

CASE REPORT / ПРИКАЗ БОЛЕСНИКА

Positive outcome of a twin pregnancy after the administration of tocilizumab to a pregnant woman with severe COVID-19

Isidora Dickov^{1,2}, Sanja Bulatović¹, Đorđe Petrović^{1,2}, Ksenija Antić-Trifunović¹, Anita Krsman^{1,2}¹University Clinical Center of Vojvodina, Clinic for Gynecology and Obstetrics, Novi Sad, Serbia;²University of Novi Sad, Faculty of Medicine, Department of Gynecology and Obstetrics, Novi Sad, Serbia**SUMMARY**

Introduction Tocilizumab is an IgG1 monoclonal antibody targeting the interleukin 6 receptor. We present a case of a pregnant woman with COVID-19 pneumonia, which rapidly worsened despite the advanced treatment. Therefore, the administration of tocilizumab was deemed necessary.

Case outline Our patient was a 31-year-old pregnant woman hospitalized on the seventh day after contracting COVID-19. She was in the 21st week of a twin pregnancy, specifically monochorionic diamniotic. Her general condition was severe, accompanied by elevated inflammation markers: C-reactive protein – 94.6 (mg/L), procalcitonin – 1.44 (ng/mL), and IL-6 – 79.3 (pg/mL), along with extensive bilateral pneumonia evident in the X-ray image. She required respiratory support in the form of high flow nasal cannula, continuous positive airway pressure, and intensive monitoring. The following day, her condition deteriorated further, prompting the decision to administer tocilizumab. After receiving tocilizumab, the X-ray image deteriorated, but the inflammation markers decreased. After 33 days of hospitalization, she was discharged with normal laboratory findings and a clear X-ray. On July 16, the patient was admitted to the Clinic for Gynecology and Obstetrics of the Clinical Center of Vojvodina at 36 weeks of gestation (35 gw + 2 day) due to premature contractions. On the same day, a caesarean section was performed, and both neonates were in good general condition.

Conclusion Managing severe COVID-19 in pregnant women poses significant challenges. This case study suggests that tocilizumab may hold efficacy in treating this condition.

Keywords: tocilizumab; bilateral pneumonia; twin pregnancy; IL-6

INTRODUCTION

The cytokine storm, or cytokine release syndrome, plays a pivotal role in the progression and exacerbation of severe acute respiratory syndrome coronavirus 2 (SARS-CoV-2). Cytokine release syndrome involves an uncontrollable immune response marked by elevated cytokine levels, notably IL-6 [1]. A significant challenge during the COVID-19 pandemic is the absence of a proven antiviral drug, especially for pregnant women. Tocilizumab (TCZ) has displayed considerable efficacy in curbing the inflammatory response to SARS-CoV-2, potentially preventing cytokine storms. Hence, this medication is being explored as an off-label treatment for moderate to severe COVID-19 [2]. TCZ, known as RoActemra® in the European Union, is a humanized monoclonal IgG1 antibody targeting the IL-6 receptor. It impedes IL-6 binding to cell receptors, reducing immune-mediated damage [3]. Treating pregnant women with COVID-19 poses uncertainties [4]. The United States Food and Drug Administration (FDA) has categorized TCZ as a category C drug in pregnancy [5]. There is a general belief that due to its size and hydrophilic nature, TCZ mainly remains in the blood plasma and extracellular fluid [6]. However, the

expanded circulating fluid volume in pregnant women might lead to reduced plasma concentration of many medications as is the case with TCZ [7]. Some studies have verified TCZ's ability to cross the placental barrier, detected through cord blood tests, newborn plasma, and even in breast milk [8]. Nonetheless, there is no definitive evidence indicating an elevated risk of congenital anomalies [9].

CASE REPORT

Our patient is a 31-year-old pregnant woman in her second pregnancy (G2P1) in the 21st gestation week (gw) of spontaneously conceived and regularly monitored monochorionic-diamniotic twin pregnancy without any complications. She was admitted to the Clinic for Gynecology and Obstetrics of the Clinical Center of Vojvodina (CGO CCV) on April 3, 2021, on the seventh day of the illness due to worsening general condition caused by SARS-CoV-2. Her symptoms started in the form of nasal congestion and weak unproductive cough when nasopharyngeal swab was positive for COVID-19, based on reverse transcription-polymerase chain reaction (RT-PCR). During the initial four days, the patient received oral

Received • Примљено:

September 1, 2023

Revised • Ревизија:

April 18, 2024

Accepted • Прихваћено:

June 9, 2024

Online first: June 28, 2024**Correspondence to:**Isidora DICKOV
Branimira Ćosića 37
21000 Novi Sad, Serbia
isidoradickov1@gmail.com

Table 1. Laboratory data during the course of COVID-19

Day of the disease	7th	8th	9th	10th	11th	16th	27th	40th
Wbc * (10 ⁹ /L) (4–10)	4.75	7.97	8.67	7.16	9.33	11.27	10.62	7.21
Neutr * (10 ⁹ /L) / (%) (2–7) / (50–70)	4.26/89.7	7.36/92.4	7.77/89.6	6.12/85.5	7.77/83.3	9.41/83.5	7.95/74.8	4.52/62.7
Lymph * (10 ⁹ /L) / (%) (0.8–4) / (20–40)	0.4/8.4	0.53/6.6	0.76/8.8	0.89/12.4	1.32/14.1	1.26/11.2	1.47/13.8	1.56/21.6
CRP (mg/L) (< 5)	94.6	98.4	100.2	46.7	22.7	1.4	0.28	0.09
PCT (ng/mL) (< 0.05)	1.44	1.42	1.08	0.67	0.42	0.08	< 0.05	< 0.05
Rbc * (10 ¹² /L) (3.9–5.4)	2.9	3.2	2.9	2.8	2.9	3	3.31	2.99
Hbg (g/L) (120–160)	88	94	86	82	86	89	99	89
Hct (L/L) (0.37–0.47)	0.26	0.28	0.26	0.25	0.26	0.26	0.29	0.26
PLT * (10 ⁹ /L) (140–400)	93	117	122	153	178	302	257	110
D-dimer (mg/L) FEU (< 0.5)	1.27	2.06	1.45	2.06	5.40	4.5	1.56	0.89
Blood sugar (mmol/L) (3.9–6.1)	5.2	6.6	4.3	4.4	5.4	5.3	4.5	4.8
Arterial blood analysis								
pH	7.41	7.42	7.45	7.43	7.45	7.47	7.47	
pCO ₂ (mmHg)	36	37	38	42	42	38	34.4	
pO ₂ (mmHg)	85	87	91	104	351	163	100.2	
Lac (mmol/L)	1.1	1	0.8	1.6	1.5	1.4	1.72	
HCO ₃ (mmol/L)	22.8	25.2	26.4	27.9	29.2	27.7	25.7	
SO ₂ (%)	96	96	97	98	100	100	100	

Wbc – white blood cells; Neutr – neutrophils; Lymph – lymphocytes; Rbc – red blood cells; Hbg – hemoglobin; HCT – hematocrit; PLT – platelets; pCO₂ – partial pressure of carbon dioxide; pO₂ – partial pressure of oxygen; Lac – lactate; HCO – bicarbonate; SO₂ – oxygen saturation

cephalosporin antibiotic (cefixime) as an outpatient. As her condition worsened with the increased body temperature up to 38°C, she was subsequently admitted to a secondary health facility where she underwent treatment with parenteral cephalosporin antibiotic (ceftriaxone), antipyretics, and received oxygen therapy through a nasal cannula. She had never undergone surgery, had not had any serious illnesses, did not receive regular therapy for chronic conditions and she did not have any allergies. On the admission to CGO CCV, the patient was conscious, oriented, communicative, without neurological symptoms, afebrile, normotensive, tachycardic up to 120 beats/minute, tachypneic with 26 respirations per minute, and oxygen saturation 88–92% with oxygen therapy via oxygen mask flow of 15 L/minute. We verified by ultrasound a vital monochorionic-diamniotic twin pregnancy at the 21st gw, a normal amount of amniotic fluid, placenta localized on the posterior wall, and both fetuses exhibited normal anatomical structures. During the examination, there was a further drop in oxygen saturation to 85% with 29 respirations per minute. Due to her severe general condition, respiratory insufficiency and tachydyspnea, she was transferred on the same evening to the Intensive Care Unit (ICU) and non-invasive ventilatory support was started. The continuous positive airway pressure (CPAP) started with (FiO₂ 100%, PEEP 5 cmH₂O, P_{supp} 5 cmH₂O) with the intermittent application of high-flow nasal cannula (FiO₂ 100%, flow 70 L/minute) where saturation of oxygen (SpO₂) was 100%. Gas analysis and blood count (Table 1) showed the patient's anemia with elevated values of inflammation markers CRP and procalcitonin. Next morning, the X-ray revealed bilateral diffuse opacities that radiologically correspond to

massive bilateral pneumonia with preserved transparency of the lung apices (Figure 1). On the eighth day of the illness and the second day of hospitalization, dual antibiotic parenteral therapy ceftriaxone 1 gr / 24 hours and piperacillin/tazobactam 4.5 gr / 6 hours, corticosteroid dexamethasone 8 mg / 24 hours i.v., therapeutic doses of low molecular weight heparin (LMWH) dalteparin 5000 IU / 12 hours s.c., gastroprotective pantoprazole 40 mg / 24 hours *per os*, and vitamin therapy were prescribed according to the National Guide for the Treatment of SARS-CoV-2, Version 11 [9]. Dual antibiotic therapy was prescribed for only one day, after which it was continued with piperacillin/tazobactam monotherapy. During the same afternoon the patient was afebrile, normotensive, tachycardic up to 123 beats/minute, tachypneic with 27 respirations per minute with rapid desaturation on room air SpO₂ < 80%. The IL-6 value was 79.3 pg/mL, which is nearly 20 times higher compared to values in healthy pregnant women in the second and third trimesters of pregnancy. Considering the worsening of her general condition, extremely elevated IL-6 levels and values of inflammatory parameters, massive bilateral pneumonia, the need for high FiO₂ and oxygen therapy flows, in agreement with the infectious disease specialist, it was decided an administration of intravenous TCZ in a double dose of 8 mg/kg for 2 days (on the eighth and ninth days of the disease). After the second dose, there was a decrease in the values of the inflammation markers with an increased level of d-dimer (Table 1). Despite unchanged parameters of oxygen therapy, there is an improvement in arterial blood gas exchange (Table 1). On the 10th day, the patient's general condition was better. The control X-ray image, taken a day after the second dose of TCZ (Figure 2)

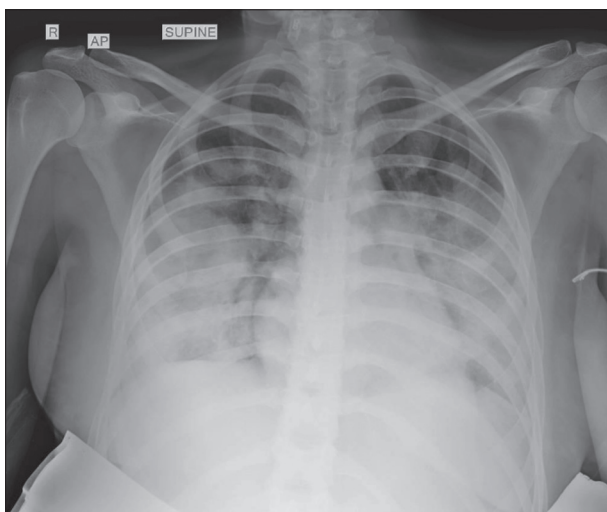


Figure 1. X-ray of the patient's heart and lungs on the eighth day of illness, before the administration of tocilizumab; chest radiograph reveals shadows in bilateral lung fields, with preserved transparency of the lung apices

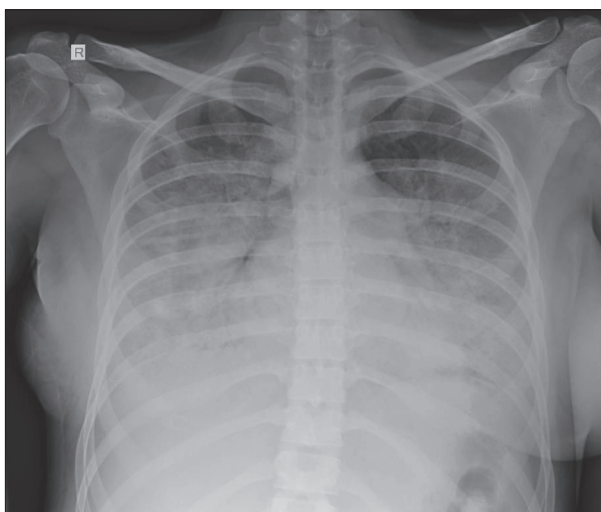


Figure 2. X-ray of the patient's heart and lungs a day after the administration of two doses of tocilizumab; lung fields on both sides with persistent diffuse shadowing, more extensive compared to the previous finding

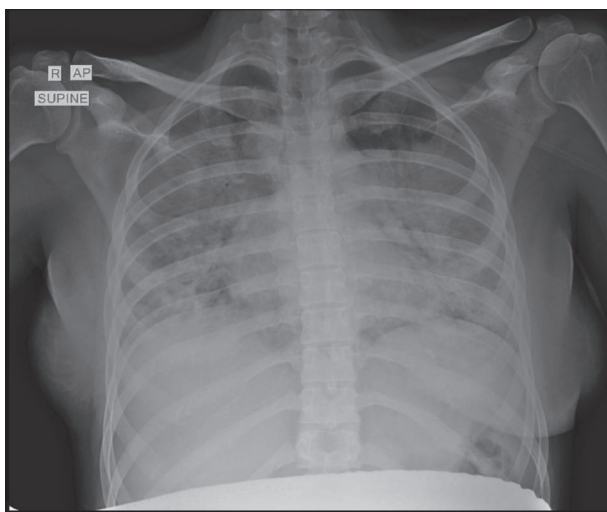


Figure 3. X-ray of the patient's heart and lungs seven days after the administration of two doses of tocilizumab; compared to the previous chest X-ray, there is slightly increased transparency in the right lung and lower part of left lung due to a mild regression in the density of merged consolidations, accompanied by a less pronounced air bronchogram and a more clearly outlined hemidiaphragm – all consistent with mild regression

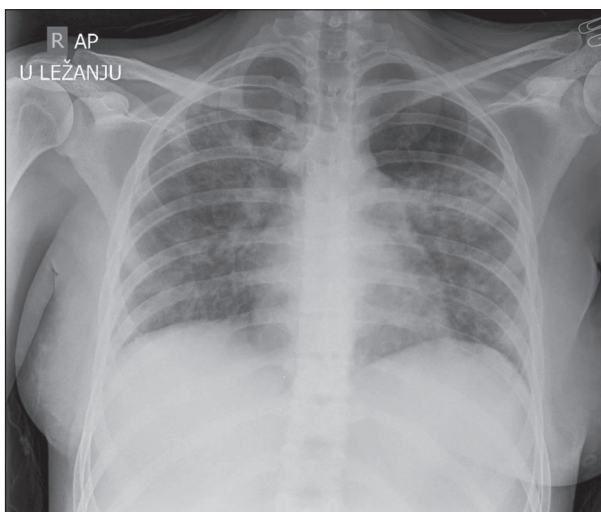


Figure 4. X-ray of the patient's heart and lungs 14 days after the administration of two doses of tocilizumab; significant regression of inflammatory changes in the lung parenchyma on both sides

indicates a progression of bilateral pneumonia with less prominent lung apex transparency. Regarding the course of the pregnancy and an ultrasound examination, everything was normal, and the pro-inflammatory markers continued to decrease. Due to the improvement in saturation, the usage of high-flow nasal cannula and continuous positive airway pressure was stopped, so the patient began using an oxygen mask with an oxygen flow of 12 L/minute. The administration of parenteral antibiotics was completed on the 16th day of the illness. The blood tests revealed normal renal and liver function tests as well as the analysis of urine and hemostatic system. Anemia was persistent in laboratory findings, with reduced iron levels of 6.5 $\mu\text{mol/L}$ (reference range for the second trimester of pregnancy is 8–32 $\mu\text{mol/L}$), along with normal values of transferrin, ferritin, folic acid, and vitamin B₁₂. Mild leukocytosis was also

present, a phenomenon called glucocorticoid-induced leukocytosis [10]. Due to the continuous use of corticosteroids, blood sugar levels were measured daily, which showed elevated values only once – 6.6 mmol/L. Seven days after the second dose of TCZ, an X-ray was taken again (Figure 3), where a greater transparency of both lungs and a clearer outline of both hemidiaphragms was evident, which pointed to the regression of the disease. Considering the improved general condition, the reduced need for oxygen therapy as well as the vital twin pregnancy, it was decided to transfer the patient to the CGO CCV, to a unit dedicated to pregnant women and postpartum mothers with COVID-19 named Covid-7 unit of CCV after 10 days spent in the ICU. During her stay at the CGO CCV, the vital parameters, blood, and urine laboratory analyses, as well as regular ultrasound checks, were consistently monitored.

As the gas exchange parameters improved, the patient received oxygen therapy through a 7 L/minute flow mask, but after a few days the patient switched to oxygen therapy via a nasal cannula. On the 27th day of the illness, in the laboratory findings, the inflammation marker continued to decline along with the improvement of anemia. Fourteen days after the administration of two doses of TCZ, the X-ray (Figure 4) was performed, which showed a significant regression of the inflammatory changes in the lung parenchyma on both sides. After 25 days of hospitalization, the use of corticosteroids was completely stopped, gradually decreasing the dosage daily. In the following days, the administration of oxygen therapy was discontinued. The patient was breathing spontaneously, maintaining oxygen saturation 98–99% in room air, with a respiratory rate of 16–18 breaths per minute. After 33 days spent in the hospital, the patient was discharged. She had normal vital parameters without any subjective complaints. Ultrasound findings showed a normal twin pregnancy. On July 16, 2021, the patient was hospitalized again at the CGO CCV, due to premature contractions in the 36th gw. On the same day, a caesarian section was performed, and both neonates were in good general condition. The patient was feeling well, without any respiratory complaints. The blood laboratory analysis showed persistent anemia, with negative CRP findings. Two live male neonates were born with body masses of 2850 g and 2590 g, respectively, and body lengths of 48 cm each. Both Apgar scores (AS) were 10/10. The caesarian section was uneventful under spinal anesthesia, with blood loss of about 400 mL and regular vital parameters. Neonates were eutrophic, normal muscle tone and well adapted. Due to prematurity and monochorionic twin pregnancy, both neonates were admitted to the semi-intensive care unit. Three hours after delivery, capillary blood gas analyses were performed on both twins and acid-base status, gas analysis, glycemia, and electrolytes of the capillary blood were normal. Blood cultures and CRP levels were tested and found to be negative. Still, a dual antibiotic treatment was empirically applied for a concise period of three days. The neonates went to the nursery regularly. There were no signs or effects of COVID-19. On the fifth postoperative day, the patient was discharged with both children. At the time of discharge, both twins were in a good overall condition, with normal findings in capillary blood. The postoperative period proceeded without complications or any symptoms of respiratory insufficiency. The histopathological examination of the placenta revealed a monochorionic placenta without pathological changes. On the follow-up examinations, the patient was in good general condition with an uneventful postpartum course.

In a phone conversation with the patient two years after the delivery, she mentioned having no health issues and regularly consulting a pulmonologist. Regarding her children, both boys are healthy, showing age-appropriate psychomotor development, up to date with vaccinations, and attending kindergarten alongside their peers.

The written consent to write and publish this case report was obtained from the patient. The review was approved by

the Ethics Committee of the Clinical Center of Vojvodina number 00-88/22.

DISCUSSION

In light of sparse data, our objective was to evaluate the maternal and neonatal safety outcomes linked to the administration of TCZ in pregnant patients severely affected by COVID-19 at CGO CCV. The Treatment Protocol for COVID-19 in the Republic of Serbia (11th Version) [11], alongside the majority of international protocols for managing SARS-CoV-2, recommends the use of IL-6 inhibitors, corticosteroids, LMWH, and oxygen therapy, in addition to starting empirical antibiotic treatment pending the identification of specific pathogens [12]. A particularly alarming observation for our medical team was the marked elevation of IL-6 levels in our patient. It's noted that serum IL-6 concentrations are naturally higher in pregnant women compared to non-pregnant women. Furthermore, these levels are elevated in the later stages of pregnancy, the second and third trimesters (below 4.4 pg/mL), in comparison to the first trimester (below 3.52 pg/mL). Our patient's IL-6 levels were found to be almost 20-fold higher than those observed in healthy women during their second and third trimesters [13]. According to the study by Isaac et al. [14], the classification of pregnant women upon their hospital admission was based on the WHO severity scale, a tool recommended by the WHO Working Group for the Clinical Characterization and Management of COVID-19 infection to assess the progression of the disease in patients. This scale spans from 0 (uninfected) to 10 (deceased), indicating disease severity and involves signs of clinical worsening, such as increased need for oxygen, declining radiographic outcomes, and escalating levels of inflammatory markers like IL-6, CRP, and d-dimer [15]. Upon the patient's admission to the CGO CCV, the WHO score was 5, which increased to 6 in less than 12 hours. Our decision to start TCZ treatment was made as our patient exhibited clinical and radiological deterioration and her WHO score increasing. In the research conducted by Isaac et al. [14], 28 expectant mothers with a WHO severity score of six and critical COVID-19 were treated with TCZ. Their findings indicated that the majority of these patients experienced a steady recovery in both clinical and radiological terms following the initiation of therapy, with no substantial adverse reactions observed in either the mothers or their babies. Similar findings were reported by Abdullah et al. [16], in a report of two pregnant women with evidence of acute cytokine storm. Both of these patients improved clinically after the use of a single dose of intravenous TCZ in addition to supportive treatments. The most extensive trial included, RECOVERY [17], demonstrated that administering a low dose of dexamethasone reduced mortality by 20% in COVID-19 patients needing oxygen and by 33% in those requiring mechanical ventilation. Considering that pregnancy is already a thrombotic

condition, with increased production of thrombin and intravascular inflammation, we immediately started with prophylactic doses of LMWH. In our patient, the presence of multiple elevations in procalcitonin and CRP values indicated the possibility of a bacterial superinfection. This led to the commencement of empirical antibiotic treatment. Considering the heightened levels of neutrophils, as well as the requirement for non-invasive ventilatory support and a stay in the ICU, the decision was made to prescribe piperacillin/tazobactam as a category B drug for use in pregnancy by the FDA [18].

Thanks to a multidisciplinary team consisting of an infectious disease specialist, gynecologist, intensivist, pulmonologist, radiologist, anesthesiologist, and a neonatologist, the patient was successfully cured, without consequences for her or her children's health.

The additional research is certainly needed on the effectiveness of TCZ use and the potential side effects of this drug in pregnant women with severe clinical course of COVID-19.

Conflict of interest: None declared.

REFERENCES

1. Ali A, Kamjani MH, Kesselman MM. The Role of Tocilizumab in Cytokine Storm and Improving Outcomes in COVID-19. *Recent Antiinfect Drug Discov.* 2020;15(2):104–12. [DOI: 10.2174/1574891X15666200922155712] [PMID: 32962623]
2. Chaudhry D, Singh PK. Tocilizumab and COVID-19. *Indian J Crit Care Med.* 2020;24(9):741–3. [DOI: 10.5005/jp-journals-10071-23608] [PMID: 33132549]
3. Xu X, Han M, Li T, Sun W, Wang D, Fu B, et al. Effective treatment of severe COVID-19 patients with tocilizumab. *Proc Natl Acad Sci U S A.* 2020;117(20):10970–5. [DOI: 10.1073/pnas.2005615117] [PMID: 32350134]
4. Wang LM, Lai SP, Liang SJ, Yang ST, Liu CH, Wang PH. Maternal and fetal outcomes of the pregnant woman with COVID-19: The first case report in Taiwan. *Taiwan J Obstet Gynecol.* 2021;60(5):942–4. [DOI: 10.1016/j.tjog.2021.07.045] [PMID: 34507681]
5. Krause ML, Amin S, Makol A. Use of DMARDs and biologics during pregnancy and lactation in rheumatoid arthritis: what the rheumatologist needs to know. *Ther Adv Musculoskelet Dis.* 2014;6(5):169–84. [DOI: 10.1177/1759720X14551568] [PMID: 25342996]
6. Ryman JT, Meibohm B. Pharmacokinetics of Monoclonal Antibodies. *CPT Pharmacometrics Syst Pharmacol.* 2017;6(9):576–88. [DOI: 10.1002/psp4.12224] [PMID: 28653357]
7. Costantine MM. Physiologic and pharmacokinetic changes in pregnancy. *Front Pharmacol.* 2014;5:65. [DOI: 10.3389/fphar.2014.00065] [PMID: 24772083]
8. Saito J, Yakuwa N, Kaneko K, Takai C, Goto M, Nakajima K, et al. Tocilizumab during pregnancy and lactation: drug levels in maternal serum, cord blood, breast milk and infant serum. *Rheumatology (Oxford).* 2019;58(8):1505–7. [DOI: 10.1093/rheumatology/kez100] [PMID: 30945743]
9. Nakajima K, Watanabe O, Mochizuki M, Nakasone A, Ishizuka N, Murashima A. Pregnancy outcomes after exposure to tocilizumab: A retrospective analysis of 61 patients in Japan. *Mod Rheumatol.* 2016;26(5):667–71. [DOI: 10.3109/14397595.2016.1147405] [PMID: 26873562]
10. Cox G. Glucocorticoid treatment inhibits apoptosis in human neutrophils. Separation of survival and activation outcomes. *J Immunol.* 1995;154(9):4719–25. [PMID: 7722324]
11. Pelemiš M, Stevanović G, Turkulov V, Vučinić V, Matijašević J, Milošević B, i saradnici. Nacionalni protokol Republike Srbije za lečenje COVID-19 infekcije, Verzija 11. Galenika. [Internet]. 2021 [cited 2022 May 09]. Available from: <https://galenika.rs/wp-content/uploads/2021/09/Protokol-za-COVID-19-11.verzija.pdf>
12. Nana M, Hodson K, Lucas N, Camporota L, Knight M, Nelson-Piercy C. Diagnosis and management of COVID-19 in pregnancy. *BMJ.* 2022;377:e069739. [DOI: 10.1136/bmj-2021-069739] [PMID: 35473709]
13. Fu Y, Tang L, Hu M, Xiang Z, Hu Y. Changes of serum interleukin-6 in healthy pregnant women and establishment of relevant reference intervals. *Clin Chim Acta.* 2020;502:116–9. [DOI: 10.1016/j.cca.2019.12.013] [PMID: 31866334]
14. Isaac B, Hazari K, Harb D K, et al. Maternal and Fetal Outcome in Pregnant Women with Critical COVID-19 Treated with Tocilizumab in a Tertiary Care Hospital in Dubai. *Cureus.* 2023;15(1):e34395. [DOI: 10.7759/cureus.34395] [PMID: 36874696]
15. WHO Working Group on the Clinical Characterisation and Management of COVID-19 infection. A minimal common outcome measure set for COVID-19 clinical research. *Lancet Infect Dis.* 2020;20(8):e192–e197. [DOI: 10.1016/S1473-3099(20)30483-7] Erratum in: *Lancet Infect Dis.* 2020;20(10):e250. [PMID: 32539990]
16. Abdullah S, Bashir N, Mahmood N. Use of intravenous tocilizumab in pregnancy for severe coronavirus disease 2019 pneumonia: two case reports. *J Med Case Rep.* 2021;15(1):426. [DOI: 10.1186/s13256-021-03010-1] [PMID: 34364393]
17. RECOVERY Collaborative Group; Horby P, Lim WS, Emberson JR, Mafham M, Bell JL, Linsell L, et al. Dexamethasone in Hospitalized Patients with Covid-19. *N Engl J Med.* 2021;384(8):693–704. [DOI: 10.1056/NEJMoa2021436] [PMID: 32678530]
18. FDA. Drugs@FDA: FDA-Approved Drugs [cited 2024 April 09]. Available at: <https://www.accessdata.fda.gov/scripts/cder/daf/index.cfm?event=browseByletter.page&productLetter=P&ai=o>.

Позитиван исход близаначке трудноће после примене тоцилизумаба код труднице са тешким обликом ковида 19

Исидора Дицков^{1,2}, Сања Булатовић¹, Ђорђе Петровић^{1,2}, Ксенија Антић-Трифунковић¹, Анита Крсман^{1,2}

¹Универзитетски клинички центар Војводине, Клиника за гинекологију и акушерство, Нови Сад, Србија;

²Универзитет у Новом Саду, Медицински факултет, Катедра за гинекологију и акушерство, Нови Сад, Србија

САЖЕТАК

Увод Тоцилизумаб је *IgG1* моноклонско антитело против рецептора интерлеукина-6. Представљамо случај труднице са тешким обликом пнеумоније изазване ковидом 19. Упркос лечењу, стање болеснице се брзо погоршавало те је примена тоцилизумаба била неопходна.

Приказ болесника Наша болесница је била 31-годишња трудница, хоспитализована седмог дана од појаве симптома ковида 19. У питању је била близаначка монохорионска диамнионска трудноћа у 21. гестацијској недељи. Опште стање болеснице било је тешко, са повишеним маркерима инфламације: С-реактивни протеин – 94,6 (*mg/L*), прокалцитонин – 1,44 (*ng/mL*) и интерлеукин-6 – 79,3 (*pg/mL*), уз присутну масивну билатералну пнеумонију. Била јој је потребна респираторна подршка у виду терапије кисеоником високог протока преко назалне каниле и примене континуираног

позитивног притиска преко личне маске, уз интензиван надзор. Дан после пријема опште стање јој се погоршало, па је одлучено да се примени тоцилизумаб. Непосредно после примене тоцилизумаба дошло је до прогресије пнеумоније, али су маркери инфламације били у паду. После 33 дана хоспитализације отпуштена је са уредним лабораторијским налазима и нормалним рендгенским снимком. На Клинику за гинекологију и акушерство примљена је 16. јула у 36. гестацијској недељи (35 недеља + два дана) због превремених контракција. Истог дана начињен је царски рез и оба новорођенчета су била у добром општем стању.

Закључак Лечење тешког облика ковида 19 код трудница представља изазов. Овај приказ болесника показује да тоцилизумаб може бити ефикасан у лечењу тог стања.

Кључне речи: тоцилизумаб; билатерална пнеумонија; близаначка трудноћа; *IL-6*