



CASE REPORT / ПРИКАЗ БОЛЕСНИКА

Breakage and dislocation of the Hickman catheter in pediatric patient

Vesna Stevanović^{1,2}, Igor Krunic², Sergej Prijic^{1,2}, Dragana Vujić^{1,2}

¹University of Belgrade, Faculty of Medicine, Belgrade, Serbia;

²Dr Vukan Čupić Mother and Child Health Institute of Serbia, Belgrade, Serbia

SUMMARY

Introduction The Hickman catheter is a tunneled, open-type catheter often implanted in children for long-term intravenous treatment. Their application can cause numerous complications. Catheter breakage and dislocation of fragments to the intravascular system is a rare but life-threatening condition. When a complication occurs, depending on the patient's clinical condition, the first step is transcatheter endovascular removal of the catheter's fragment. If this is not possible, surgical thoracotomy is necessary. The objective of this article was to present a case of breakage and dislocation of Hickman catheter in a pediatric patient, as well as the diagnostic and therapeutic approach to complications.

Case outline We report a 14-month-old child who had a Hickman catheter because he was undergoing treatment for acute juvenile myelomonocytic leukemia. Due to a malfunction of the catheter, the existing catheter had to be removed. During the surgical procedure, a breakage and dislocation of the catheter fragment occurred. A chest X-ray and an echocardiography confirmed the position of the catheter fragment in the right atrium. A transcatheter endovascular procedure was successfully performed to remove the fragment of the catheter.

Conclusion Numerous complications can occur during the insertion, management, and removal of long-term catheters. It is necessary to periodically control the catheter's position by chest X-ray and ultrasound of the heart and neck. If a particular complication is detected, an individual approach to treatment with the lowest risk to the patient should be chosen. Dislocated fragments of the Hickman catheter can be safely removed by endovascular transcatheter procedures.

Keywords: Hickman catheter; complication; children; transcatheter endovascular procedure

INTRODUCTION

The Hickman catheter is a long-term, tunneled central venous catheter (CVC). It is used to administer medications and blood components infusion or to sample blood in pediatric patients. It is implanted with a surgical approach in children with malignant diseases, short bowel syndrome, chronic diarrhea, hemophagocytic syndrome, and hemolytic-uremic syndrome [1, 2]. The catheter is removed when treatment is completed or if complications occur during catheter insertion, use and removal [3]. The most common complication is infection [4]. Less common complications are thrombosis, malfunction, obstruction of the catheter, hemo-pneumothorax, air embolism, injury of the brachial plexus, erosion of the venous wall, dislocation, catheter disconnection or catheter breakage with drug extravasation or secondary embolization [5]. Breakage of the CVC is a severe and life-threatening complication with an incidence in adults in the range of 0.2–4.2% [6, 7]. The first case report of heart embolization in humans by polyurethane peripheral venous catheter fragments was published in 1954 [8]. Depending on the place of insertion, the part of the catheter could be in the superior vena cava or the heart, causing arrhythmias, myocardial perforation, damage to the valvular apparatus

or leading to embolization of the pulmonary artery. We report the surgical removal of a Hickman catheter in a 14-month-old child. During the removal, a catheter fracture with embolization of the heart occurred. We want to emphasize the severity of the complication and point out the possibilities of diagnosis and treatment in such situations.

CASE REPORT

A 14-month-old child has been treated for juvenile myelomonocytic leukemia. Due to the challenging course of the disease, a splenectomy was performed in the 11th month of life. A 5 Fr Hickman catheter was installed through the right internal jugular vein in the same operation. Three months later, the catheter malfunctioned, requiring its surgical removal in analgosedation. A preoperative X-ray of the chest indicated the proper position of the tip of the Hickman catheter, its integrity, and a normal finding on the heart and lungs. Preoperative echocardiography demonstrated a normal finding. Blood count and coagulation screening tests were acceptable for general anesthesia. Surgical removal of the Hickman catheter was performed in the operating theatre, in analgosedation, with local anesthesia. We followed the pediatric protocols of

Received • Примљено:
January 19, 2024

Revised • Ревизија:
July 21, 2024

Accepted • Прихваћено:
August 1, 2024

Online first: August 6, 2024

Correspondence to:

Vesna STEVANOVIĆ
Dr. Vukan Čupić Mother and Child
Health Institute of Serbia
Radoja Dakića 6–8
11000 Belgrade
Serbia
vesna.stevanovic@med.bg.ac.rs

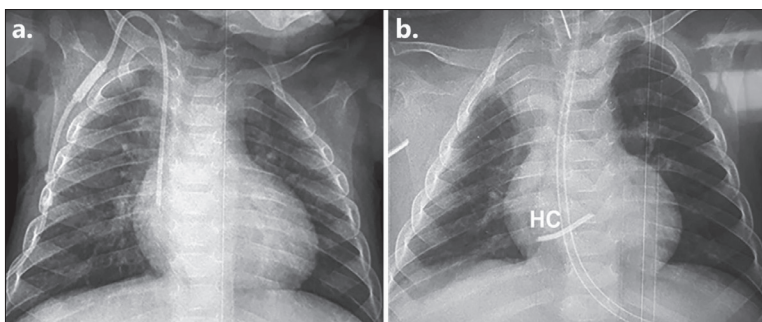


Figure 1. The preoperative chest X-ray (a); the postoperative chest X-ray (b); HC – the part of the Hickman catheter

preoperative fasting, premedication and patient monitoring during the procedure. Analgesedation was performed by intravenous use of propofol and ketamine with inhalation of oxygen and air on spontaneous breathing. Very soon after the surgery, massive bleeding developed with a growing hematoma in the right pectoral region. The child was urgently returned to the operating theatre, intubated, and was put under general anesthesia. Signs of hemorrhagic shock quickly developed. During the exploration of the bleeding site, it was necessary to give transfusion of packed erythrocytes and platelet concentrates, tranexamic acid, crystalloids, 5% albumin and dopamine infusion to maintain the hemodynamic stability. Chest X-ray in the operating theatre showed normal findings without Hickman catheter fragments. During the exploration of the wound, no specific lesion of the blood vessel was found. A hematoma was evacuated from the pectoral area, and drainage was performed.

The child was transferred into the pediatric intensive care unit (PICU). The treatment in the PICU involved mechanical ventilation of the patient, sedation, and relaxation. Hemodynamic stability was established. Laboratory results indicated impaired coagulation, with activated clotting time of 140 seconds, and platelet dysfunction on rotational thromboelastometry. Control blood count showed leukocytosis (white blood cells $27.6 \times 10^9/L$), anemia (red blood cells $1.91 \times 10^{12}/L$, hemoglobin 61 g/L, hematocrit 0.17), and thrombocytopenia (platelets $46 \times 10^9/L$). In order to correct these disorders, the patient received concentrate of clotting factors II, VII, IX, and X, tranexamic acid, packed red cells, platelet transfusion, and fresh frozen plasma. A control chest X-ray performed immediately after admission to the PICU revealed a part of the CVC in the right atrium (Figure 1) confirmed by echocardiography examination (Figure 2).

The child had no clinical symptoms caused by the intracardiac position of the catheter.

Options for foreign-body extraction were catheterization of the heart with a percutaneous endovascular retrieval of the catheter fragment or open thoracotomy. In general anesthesia, interventional cardiologist introduced the transcatheter endovascular device in the catheterization theatre through the right femoral vein. Hickman CVC fragment, 4.5 cm long (Figure 3), was attached by the snare catheter and successfully retrieved through 7 Fr long sheath introducer. The treatment continued in the PICU

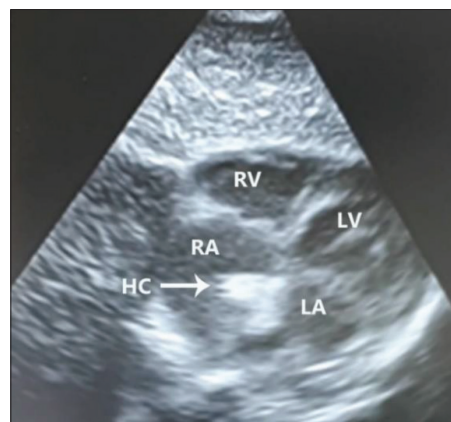


Figure 2. The postoperative heart ultrasound; HC – part of Hickman catheter; LV – left ventricle; RV – right ventricle; LA – left atria; RA – right atria

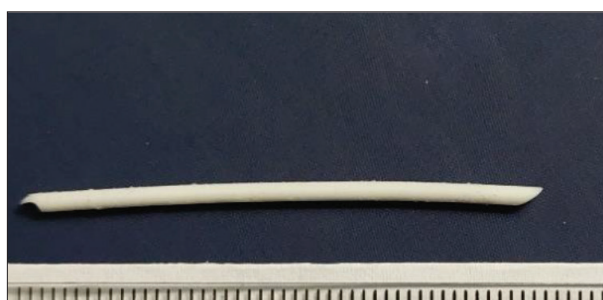

Figure 3. Part of Hickman catheter 4.5 cm long

for the next five days. The child was afebrile and hemodynamically stable. On the third postoperative day, he was extubated, and oral intake was started. Postoperative laboratory results on discharge were normal, and the child was transferred to the hematologic ward for further treatment.

The authors declare that the article has been written in accordance with the ethical standards of the Serbian Archives of Medicine and the ethical standards of medical facilities for each author involved. No personal data of the patient has been presented in the manuscript. Written consent was obtained from the parents.

DISCUSSION

Using permanent CVCs has changed the perspective of long-term treatment of pediatric patients. Complications are always possible. The most common complication is sepsis, and the less frequent complications are thrombosis, malfunction, dislocation, or catheter breakage. There are several causes of catheter breakage: the length of use, the chemical reaction of the drugs with catheter walls, the pressure at which fluids are injected, chronic pressure to which surrounding tissues expose the catheter and external influences. Many studies have shown that silicone catheters are more durable than polyurethane [9]. “Pinch-off syndrome,” which describes catheter compression between the clavicle and the first rib and can be verified by chest X-ray, indicates an imminent breakage of the catheter [10]. Catheter breakages occur in the external parts of the Hickman catheter rather than in

the tunneled part of the catheter [11]. However, in pediatric patients, this complication can be asymptomatic; symptoms can be arrhythmias, paresthesia, palpitations, or catheter malfunction. This complication can be the cause of death due to pericardial tamponade, myocardial perforation, sepsis, endocarditis, thrombosis, pulmonary embolism, myocardial infarction, fatal arrhythmias, the formation of aneurysms or pulmonary abscesses [12]. In the study of pediatric patients, Zhang et al. [13] concluded that Hickman catheters are more prone to mechanical damage than totally implanted port catheters. Also, catheter breakages are more common in occluded catheters when extensive fluid pressure is used to flush the catheter. CVC occlusion accounted for 14–36% of catheter-related complications within one to two years of insertion.

This complication occurs more frequently in younger children and in children with lower body weight [14]. Breakages during catheter removal or exchange and disconnection are more common in children than in adults [15]. The pulmonary artery is the most common location of fragment dislocation in pediatric patients.

Annual checks of the catheter position by chest X-ray or ultrasound of the heart and neck are necessary [16]. If a catheter compression is observed in the costoclavicular area on the X-ray examination, it is necessary to remove it as soon as possible [10]. Part of the protocol for implantation and explantation of the Hickman catheter in our hospital includes performing a chest X-ray to reveal the appropriate position of the catheter in the operating theatre. In our case, the chest X-ray was performed, but a catheter fragment was not seen either in the heart or in the chest because it remained in the neck (right jugular vein). Afterwards, during the stay at the PICU, the foreign body dislocated and was seen in the right atrium by a chest X-ray and echocardiography. This situation implies the need for

periprocedural X-ray imaging of the neck as well as of the chest. When a diagnosis of an intravascular foreign body is made, treatment options include percutaneous retrieval, open thoracotomy, anticoagulant therapy, or expectative management.

Clinical indications for retrieval should be made on a case-by-case basis. Indeed, catheterization extraction through the femoral vein is less radical for the patient. Snares are preferred retrieval devices in pediatric patients because of their safety, availability, and flexibility, with high success and low complication rates [15, 17]. In our case, the intervention was successful. A systematic review of adult patients with percutaneous retrieval of vascular foreign bodies showed an achievement rate of 93.5%, while a pediatric series reported a success rate of 89.5%. The leading causes of failure were the absence of a free-floating end to snare, the small size of fragments, adherence to the vein wall, and fragment lodgment in a thrombosed vessel [15]. An attempt to retrieve the foreign body percutaneously should be made whenever possible [18–21]. If it is impossible to remove a catheter fragment in this way, open thoracotomy is the next step.

In conclusion, long-term CVCs have changed the perspective of treating pediatric patients. Handling this device requires special attention. During implantation and explantation of the Hickman catheter, radiographic and ultrasound examination of the neck and chest can reveal unwanted breakage and dislocation. If complications occur, a multidisciplinary approach is necessary, and percutaneous endovascular retrieval is the treatment of choice.

Funding: The author(s) received no financial support for the research, authorship, and/or publication of this article.

Conflict of interest: None declared.

REFERENCES

- Zvzdic Z, Zaimovic E, Milisic E, Jonuzi A, Glamoclija U, Vranic S. The Frequency, Severity, and Risk Factors of Hickman Catheter Related Complications in Pediatric Cancer Patients: A Single-Center Experience from Bosnia and Herzegovina. *Turk Arch Pediatr.* 2024;59(2):144–9. [DOI: 10.5152/TurkArchPediatr.2024.23179] [PMID: 38454222]
- Avery J, Guffey D, Ma S, Basom R, Lee SJ, Garcia D, et al. Risks factors and outcomes for isolated catheter-related deep venous thrombosis in patients undergoing allogeneic hematopoietic stem cell transplantation. *Thromb Res.* 2023;229:1–6. [DOI: 10.1016/j.thromres.2023.06.017] [PMID: 37356171]
- Garonzi C, Zeni F, Tridello G, Giacomazzi A, Castagna A, Esposto MP, et al. Results of a long-term, prospective study on complications of central venous catheter in pediatric patients with hematologic-oncologic diseases. *Pediatr Blood Cancer.* 2024;71(7):e30990. [DOI: 10.1002/pbc.30990] [PMID: 38605511]
- Drasković B, Fabri I, Benka AU, Rakić G. Infections associated with the central venous catheters. *Srp Arh Celok Lek.* 2014;142(3–4):261–6. [DOI: 10.2298/sarh1404261d] [PMID: 24839787]
- Annetta MG, Celentano D, Zumstein L, Attinà G, Ruggiero A, Conti G, et al. Catheter-related complications in onco-hematologic children: A retrospective clinical study on 227 central venous access devices. *J Vasc Access.* 2024;25(2):512–8. [DOI: 10.1177/11297298221122128] [PMID: 36113076]
- Kridis W, Toumi N, Khanfir A. Causes of Fracture at Catheter of Totally Implantable Venous Access Port: A Systematic Review. *Acta Med Iran.* 2020;57(12):686–9. [DOI: 10.18502/acta.v57i12.3463]
- Gazzanelli S, Miccini M, Sapienza P, Cavallaro G, Biacchi D, Crocetti D, et al. Fracture and migration in right atrium of a permanent venous central access system in an elderly patient: case report and literature review. *Clin Ter.* 2022;173(3):207–13. [DOI: 10.7417/CT.2022.2419] [PMID: 35612331]
- Turner DD, Sommers SC. Accidental passage of a polyethylene catheter from cubital vein to right atrium; report of a fatal case. *N Engl J Med.* 1954;251(18):744–5. [DOI: 10.1056/NEJM195410282511806] [PMID: 13214322]
- Kehagias E, Galanakis N, Tsetis D. Central venous catheters: Which, when and how. *Br J Radiol.* 2023;96(1151):20220894. [DOI: 10.1259/bjr.20220894] [PMID: 37191031]
- Lakshmi HN, Sharma M, Jain A, Puj K, Jayaprakash D, Pandya S. Chemoport Fracture due to Catheter Pinch Off Syndrome: A Rare Complication of Subclavian Vein Approach Revisited. *Indian J Surg Oncol.* 2022;13(2):343–7. [DOI: 10.1007/s13193-021-01459-6] [PMID: 35782799]
- Christison-Lagay ER, Brown EG, Bruny J, Funaro M, Glick RD, Dasgupta R, et al. Central Venous Catheter Consideration in Pediatric Oncology: A Systematic Review and Meta-analysis From the American Pediatric Surgical Association Cancer Committee. *J Pediatr Surg.* 2024;59(8):1427–43. [DOI: 10.1016/j.jpedsurg.2024.03.047] [PMID: 38637207]

12. Moss JG, Wu O, Bodenham AR, Agarwal R, Menne TF, Jones BL, et al.; CAVA trial group. Central venous access devices for the delivery of systemic anticancer therapy (CAVA): a randomised controlled trial. *Lancet*. 2021;398(10298):403–15. [DOI: 10.1016/S0140-6736(21)00766-2] [PMID: 34297997]
13. Zhang JJ, Nataraja RM, Lynch A, Barnes R, Ferguson P, Pacilli M. Factors affecting mechanical complications of central venous access devices in children. *Pediatr Surg Int*. 2022;38(7):1067–73. [DOI: 10.1007/s00383-022-05130-1] [PMID: 35513517]
14. Nieto-Vega FA, García-Rojas Á, Moreno-González I, Martínez-Rivera V, Rodríguez-Mesa JM, Rosa-Camacho V. Hemodialysis Catheter Breakage in an Infant. *J Vasc Access*. 2023;24(6):1525–8. [DOI: 10.1177/11297298221086854] [PMID: 35394377]
15. Pazinato LV, Leite TFO, Bortolini E, Pereira OI, Nomura CH, Motta-Leal-Filho JMD. Percutaneous retrieval of intravascular foreign body in children: a case series and review. *Acta Radiol*. 2022;63(5):684–91. [DOI: 10.1177/02841851211006904] [PMID: 33832338]
16. Bajaber A, Ali MH, Bazuhair AO, Bajaber O, Alsaiady M, Rabie S, et al. Successful retrieval of deep intracardiac migrated broken umbilical venous catheter in a preterm infant: Case report. *Radiol Case Rep*. 2024;19(4):1235–8. [DOI: 10.1016/j.radcr.2023.12.022] [PMID: 38292783]
17. Woodhouse JB, Uberoi R. Techniques for intravascular foreign body retrieval. *Cardiovasc Intervent Radiol*. 2013;36(4):888–97. [DOI: 10.1007/s00270-012-0488-8] [PMID: 23073559]
18. Matsui Y, Asai T, Oishi A, Kamikawa Y, Amano A, Tabata M. Minimally Invasive Extraction of a Catheter From the Heart Without Thoracotomy. *Ann Thorac Surg*. 2022;114(6):e451–e453. [DOI: 10.1016/j.athoracsurg.2022.02.019] [PMID: 35231434]
19. Habib MH, Hillis M, Alkhodari KH. Percutaneous Retrieval of Fractured Catheters from Pediatric Endovascular Tree: Case Series and Literature Review. *J Heart Cardiol*. 2019;4(1):8–11. [DOI: 10.15436/2378-6914.19.2497]
20. Xu J, Morchi G, Magge SN. Endovascular retrieval of a broken distal ventriculoatrial shunt catheter within the heart: illustrative case. *J Neurosurg Case Lessons*. 2021;2(21):CASE21452. [DOI: 10.3171/CASE21452] [PMID: 36060425]
21. Mori K, Somagawa C, Kagaya S, Sakai M, Homma S, Nakajima T. "Pigtail through snare" technique: an easy and fast way to retrieve a catheter fragment with inaccessible ends. *CVIR Endovasc*. 2021;4(1):24. [DOI: 10.1186/s42155-021-00218-6] [PMID: 33651249]

Оштећење и дислокација Хикмановог катетера код педијатријског пацијента

Весна Стевановић^{1,2}, Игор Крунић², Сергеј Пријић^{1,2}, Драгана Вујић^{1,2}

¹Универзитет у Београду, Медицински факултет, Београд, Србија;

²Институт за здравствену заштиту мајке и детета Републике Србије „Др Вукан Чупић“, Београд, Србија

САЖЕТАК

Увод Хикманов катетер је стални тунелизовани катетер отвореног типа, који се често имплантира у дечјем узрасту за потребе дуготрајног лечења. Његова примена може изазвати компликације. Оштећење катетера и дислокација фрагмената у интраваскуларни систем је ретка, али животно угрожавајућа компликација. Када се компликација догоди, у зависности од клиничког стања пацијента, треба прво покушати са транскутаном ендоваскуларним уклањањем фрагмента катетера. Уколико то није могуће, приступа се торакотомији.

Циљ овог рада је да се прикаже начин настанка оштећења и дислокације Хикмановог катетера код педијатријског болесника, као и дијагностички и терапијски приступ компликацијама.

Приказ болесника Приказујемо 14-месечно дете коме је у току лечења јувенилне мијеломоноцитне леукемије уграђен Хикманов катетер. Због малфункције катетера, постојећи

катетер је морао бити извађен. Током хируршке процедуре дошло је до оштећења и дислокације фрагмента катетера. Рендгенски снимак плућа и ултразвук срца потврдили су позицију фрагмента катетера у десној комори. Транскутани ендоваскуларни приступ уклањања дела катетера је успешно изведен.

Закључак Током инсерције, примене и уклањања дуготрајних катетера могу се десити бројне компликације. Неопходна је повремена контрола позиције катетера рендгенским снимком грудног коша и ултразвучним прегледом срца и врата. Уколико се открије одређена компликација, треба приступити индивидуалном лечењу са најмањим ризиком по пацијента. Одломљени делови катетера могу бити успешно уклоњени ендоваскуларном транскатетерском процедуром.

Кључне речи: Хикманов катетер; компликације; дете; перкутана ендоваскуларна процедура