



## CASE REPORT / ПРИКАЗ БОЛЕСНИКА

# Spontaneous upper urinary tract rupture due to urolithiasis

Valentin Yotovski, Slavina Kotova, Metodi Milushev, Tzvetan Lazarov, Alexandar Krastanov

Alexandrovska University Hospital, Department of Urology, Sofia, Bulgaria;  
Medical University of Sofia, Department of Urology, Sofia, Bulgaria

## SUMMARY

**Introduction** The spontaneous rupture of the upper urinary tract's cavity system, which includes the pelvicalyceal system and ureter, is sporadic. This phenomenon, where urine unexpectedly leaks out of the cavity system without any apparent cause of trauma or medical intervention, is a fascinating and puzzling aspect of urology. This condition is typically attributed to obstructive uropathy, which leads to increased pressure within the urinary tract.

This article illustrates the sporadic occurrence of spontaneous ruptures within the pelvicalyceal system. It underscores the importance of prompt diagnosis and timely treatment to restore wall integrity without significant stenosis.

**Outlines of cases** We have recorded four cases of spontaneous rupture in urolithiasis, with a median patient age of 47.5 years. The clinical symptoms mimic those of renal colic. Ultrasound, computed tomography scans, and retrograde pyelography were used to diagnose the condition. Treatment consisted of inserting a JJ stent for an average duration of 2.5 months. In all cases, prompt diagnosis and treatment have led to a remarkable restoration of the pelvicalyceal system and the ureter's wall, with spontaneous absorption of the extravasation and without significant ureteral strictures.

**Conclusion** The positive outcome underscores the importance of early diagnosis and treatment and offers hope for future cases.

**Keywords:** urolithiasis; spontaneous rupture; extravasation

## INTRODUCTION

The spontaneous rupture of the cavity system of the upper urinary tract is infrequent, with only a handful of documented cases [1]. This condition, characterized by the outflow of contrast outside the urinary tract's cavity system, typically occurs without any trauma or surgical intervention. It is most often associated with obstructive uropathy and increased intracavitary pressure during urolithiasis. Less common causes are malignant neoplasms, idiopathic retroperitoneal fibrosis posterior urethral valves, bladder obstruction, connective tissue diseases leading to fibrosis, renal biopsy, extracorporeal shock wave lithotripsy (ESWL), increased diuresis, pregnancy [2–8]. The clinical presentation mirrors renal colic. The most common symptoms are sudden, severe, persistent lower abdominal pain with severe peritoneal irritation. Diagnosis is typically made using ultrasound, CT-urography, or retrograde pyelography. Given the scarcity of cases reported in the literature, much remains to be understood about pathogenesis and the therapeutic-diagnostic algorithm.

contrast from the urinary cavity system. In our analysis, we defined 'spontaneous' as any rupture occurring in the upper urinary tract (pelvicalyceal system and ureter) that was not directly related to trauma or surgical intervention in the area, which directly damaged the wall of the urinary system.

## Case 1

A 41-year-old man came to our urology department complaining of pain in the right lumbar region and right abdominal half for the previous five days. He also experienced nausea and vomiting and had a slight fever of 37.4°C. The patient has a history of kidney stone disease. Upon examination, he appeared to be in satisfactory general condition and was not feverish. Tenderness in the right abdominal half with peritoneal irritation and positive succussion was noted on the right side (please see Table 1 for the clinical data of the presented patients).

The patient was referred for a computed tomography scan with the introduction of intravenous contrast. The results revealed an obstructive calculus measuring 9 × 7 × 8 mm in the right kidney's ureteropelvic junction (UPJ). There was also third-degree hydronephrosis and leakage of contrast agent distal to the calculus in the periureteral fat along the entire abdominal segment of the ureter (Figures 1 and 2).

## REPORT OF CASES

This article comprehensively analyzes four cases involving the spontaneous outflow of

**Received • Примљено:**  
June 29, 2024

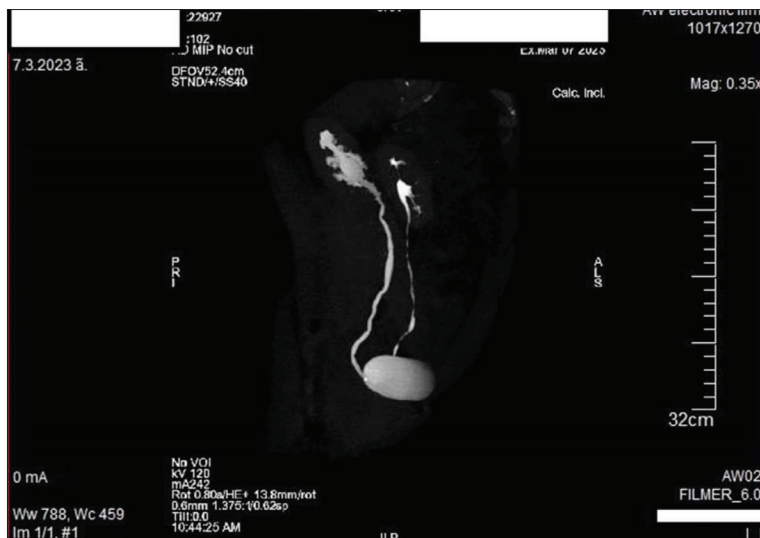**Revised • Ревизија:**  
August 11, 2024

**Accepted • Прихваћено:**  
September 8, 2024

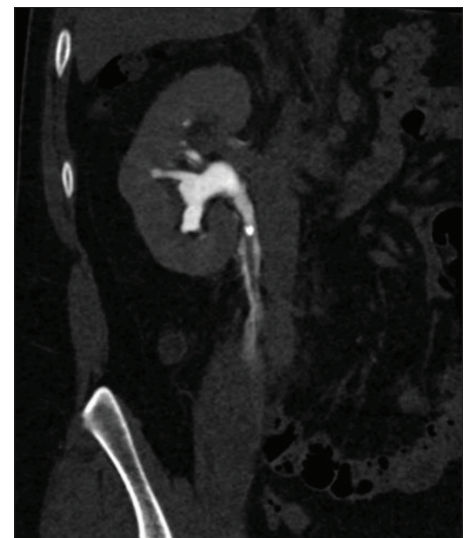
**Online first:** September 10, 2024

### Correspondence to:

Slavina KOTOVA  
Department of Urology  
Alexandrovska University Hospital  
1 Georgi Sofijski Blvd  
Sofia 1431, Bulgaria  
[slavina\\_rk@abv.bg](mailto:slavina_rk@abv.bg)



**Figure 1.** Preoperative CT scan: a spontaneous rupture of the ureteropelvic junction and a leakage of intravenous contrast around the lower pole of the right kidney



**Figure 2.** Preoperative CT scan: spontaneous rupture and leakage of intravenous contrast around the right ureter; calculus below the ureteral-pelvic junction

The patient underwent retrograde pyelography on the right side. During the procedure, a 1-cm calculus was found in the UPJ and repositioned in the kidney. Following the procedure, a 6F JJ stent was placed using a hydrophilic guidewire for eight weeks, and a urethral catheter was inserted for one week. The patient was discharged on the second postoperative day.

After two months, the patient was admitted to the urology department for planned stent removal and laser treatment of the kidney stone in the right kidney.

### Case 2

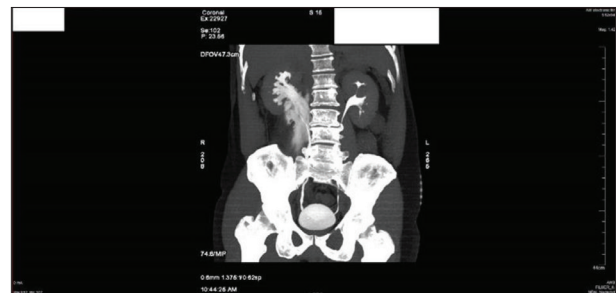
A 46-year-old patient came to the Emergency Center complaining of pain in the right lumbar region, spreading to the right abdominal area, along with urinary difficulties for about a day, as well as nausea and vomiting. No fever was reported, and the patient had no history of kidney stone disease.

Computed tomography with CT urography revealed a rupture of the pelvis of the right kidney with leakage of contrast agent into the perirenal and periureteral areas and a 4-mm obstructing calculus in the intramural part of the right ureter (Figure 3).

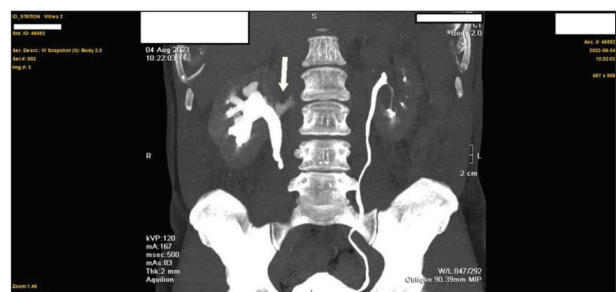
A ureteroscopy was performed on the right side, during which a 4-mm calculus was promptly reached after accessing the right ureteral ostium. The stone was extracted using a nitinol stone extractor. Subsequently, a retrograde pyelography on the right side revealed a contrast agent leakage from the collecting system of the right kidney. A 6F/26cm JJ stent was placed for a period of six weeks, and a urethral catheter was placed for ten days. The patient was discharged on the seventh day.

### Case 3

A 58-year-old man complained of pain in the right lumbar region, which radiated along the right ureter for two



**Figure 3.** Preoperative CT scan: spontaneous rupture of the pelvis and leakage of intravenous contrast throughout the abdominal segment of the right ureter



**Figure 4.** Preoperative CT scan: spontaneous rupture of the fornix of the upper calyx of the right kidney and a small leakage of contrast (arrow)

days. He did not have a fever and had no history of kidney stone disease. An intravenous contrast CT scan revealed a rupture of the fornix of the upper calyx of the right kidney and a small leakage of contrast (Figure 4).

The patient underwent retrograde pyelography on the right. During the procedure, a 1-cm calculus was found below the UPJ. Following the procedure, a 6F JJ stent was placed using a hydrophilic guidewire for three months, and a urethral catheter was inserted for 4 days. The patient was discharged on the fifth postoperative day.

After three months, the patient was admitted to the urology department for planned stent removal and laser

treatment of the kidney stone in the right kidney. One week after the laser lithotripsy procedure, the patient was readmitted to the hospital due to a urinary tract infection caused by *Klebsiella pneumoniae* and received a 10-day course of antibiotics.

#### Case 4

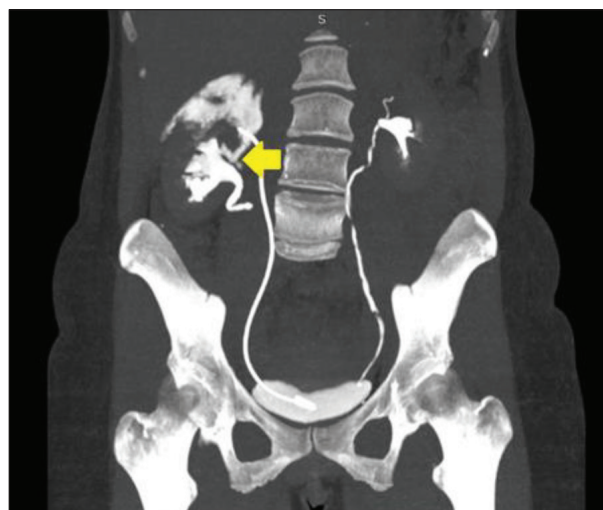
A 45-year-old female patient arrived at the Emergency Center with complaints of pain and heaviness in the right lumbar region, which had persisted for two days. The pain radiated from the right ureter to the right inguinal region and down to the right thigh. The patient also experienced one episode of nausea and vomiting.

Objectively, the patient was in satisfactory general condition and afebrile. Palpation was moderately painful in the right mesogastrium. Succussion over the right kidney was positive, and ultrasound showed mild drainage disorders in the right kidney. An X-ray revealed a 9/5-mm calcium-dense shadow in the right kidney, suspected to be a stone.

The next day, the patient underwent a retrograde pyelography on the right side, which did not reveal the presence of calculus or ureteral stenosis. A 6F/26cm JJ stent was placed. During the control CT scan with contrast, the following findings were noted for the right kidney: it was positioned abnormally low (ptosis), with the hilus at the L4 level; there was a double drainage system on the right side; a JJ stent was found in the upper part of the collecting system; and the lower part of the collecting system showed second-degree hydronephrosis. Additionally, an 8/6/4-mm oval-shaped calculus was observed in the proximal part of the inferior ureter, 20 mm from the UPJ. At the excretory phase, there is no visualization of contrast agent separation distal from the calculus due to complete obstruction. Contrast extravasation is observed from a caudally located calyx of the upper drainage system (Figure 5).

A follow-up CT scan with contrast enhancement was conducted four weeks after the surgical procedure. The scan showed no perirenal urinomas. Contrast material separated at the excretory phase beyond the previously mentioned stone. The two ureters were observed to have a parallel course and possibly share a common opening – a condition known as ureter duplex. The patient was readmitted to the hospital six weeks after the surgery to remove the inserted JJ stent and perform laser lithotripsy as planned.

All four patients experienced leakage of contrast from the cavity of the upper urinary tract without any direct trauma or iatrogenic damage. The outflow of contrast



**Figure 5.** Preoperative CT scan: spontaneous rupture of the pelvis (arrow) and an outflow of intravenous contrast around the upper pole of the right kidney

was a result of renal colic causing acute obstruction of the urinary tract. The patients were diagnosed using a combination of ultrasound, X-ray, and CT with intravenous contrast (Figures 1–4). At the same time, retrograde pyelography was used for the fourth case, following which CT-urography was repeated (Figure 5). All four patients developed acute renal colic, characterized by pain in the lumbar region that radiated along the ureter, nausea, and vomiting, with or without fever (Table 1).

The patients underwent endoscopic upper urinary tract desobstruction by a JJ stent placement on the corresponding side, followed by antibiotic therapy. Three patients underwent surgical intervention at the 24th hour of diagnosis, while one (Patient 2) underwent surgery at the fourth hour. In the case of Patient 2, a JJ placement and an extraction of a 5-mm stone from the distal ureter were performed at one stage. The urethral catheter was retained for three, 10, four, and 14 days for patients 1, 2, 3, and 4, respectively. Notably, symptom management and condition improvement can be achieved immediately after desobstruction. The criteria for discharge include the absence of symptomatology, the normalization of laboratory results, and an ultrasound examination rejecting hydronephrosis or retroperitoneal collection.

Following discharge, three patients underwent a control CT scan: Patient 1 after 30 days, Patient 2 after 15 days, and Patient 4 after 28 days. All three patients showed normal CT scans, and later, laser lithotripsy was performed in Patients 1 and 4. Due to the lack of clinical and ultrasound

**Table 1.** Clinical data

Patient	Sex	Age	Laboratory results				Comorbidity	Surgery	T°	Onset of the symptoms [days]
			Hgb	WBC	Cr	CRP				
1	Male	41	154	10.3	141	18.7	Nephrolithiasis	No	Up to 37.4°C	5
2	Male	46	156	15.5	133	3.3	Crohn's disease	No	No	2
3	Male	58	127	9	153	110	No	Laparotomy for a puncture wound	No	2
4	Female	45	131	11.8	70	15.3	No	No	Up to 38°C	7

Hgb – hemoglobin; WBC – white blood cells; Cr – creatinine; CRP – C-reactive protein

data for pathology, a control CT scan was deemed unnecessary for Patient 3, who proceeded directly to laser lithotripsy. The stents were removed after 90, 45, 90, and 55 days for patients 1, 2, 3, and 4, respectively. Timely endoscopic treatment proved effective in controlling the condition and preventing complications in all patients.

One complication, indirectly related to the rupture of the cavity system, was observed – a nosocomial urinary tract infection with *Klebsiella pneumoniae*. In Patient 3, one week after laser lithotripsy, which required re-hospitalization and a 10-day course of antibiotics.

All procedures strictly adhered to the ethical standards set forth by the institutional and national research committee, in line with the 1964 Helsinki Declaration and its subsequent revisions or equivalent ethical standards.

## DISCUSSION

Spontaneous rupture of the cavity system in the urinary tract is a rare condition, with only a few reported cases worldwide [9]. This occurs when there is a leakage of contrast into the retroperitoneal area without any trauma or medical intervention, often due to obstructive uropathy and increased pressure in the cavity system [10]. It is typically seen in the proximal third of the ureter, the pelvis, and the fornix of the calyx [11]. Cases of urinoma formation have been documented in the literature, with a median age of 42 and an equal frequency among both sexes [2, 12].

Urolithiasis is the leading cause of spontaneous ureter rupture, with the pathogenetic mechanism involving an obstruction that increases intraluminal pressure and leads to rupture. Other causes include passing stones causing mechanical trauma to the wall and erosions, ulcerations, or necrosis due to stone compression. Less common causes include malignant neoplasms, idiopathic retroperitoneal fibrosis, posterior urethral valves, bladder obstruction, vesicoureteral reflux, connective tissue diseases, renal biopsy, ESWL, urinary tract infection, increased diuresis, pregnancy, and chemotherapy [2–8].

Spontaneous ruptures of the upper urinary tract include the spontaneous rupture of the kidney (also known as Wunderlich syndrome) as well. It is a rare but life-threatening condition [13]. The clinical signs include the Lenk triad, which consists of a sudden onset of pain in the lumbar region, palpable mass, hemorrhagic shock, abdominal pain, and hematuria without any underlying trauma. Factors such as renal cell carcinoma, angiomyolipoma, systemic vasculitis, aneurysms and pseudoaneurysms of renal vessels, arteriovenous fistulas, venous thrombosis, systemic lupus, coagulopathies, infections, and the use of anticoagulants and antiplatelet agents are often implicated in the development of this condition [14, 15].

The clinical presentation of spontaneous rupture of the pelvicalyceal system and ureter includes pain in the lumbar region, abdominal pain with peritoneal irritation, acute

abdomen symptoms, nausea with or without vomiting, and fever. It frequently occurs without urinary system symptoms and with normal urine analysis results.

The optimal method for diagnosing a spontaneous rupture of the upper urinary tract involves an ultrasound examination, CT with intravenous contrast, and retrograde pyelography [16–20].

Treatment for a spontaneous rupture of the pelvicalyceal system and the ureter typically includes the placement of a JJ stent for six to eight weeks. Follow-up monitoring may consist of retrograde pyelography and/or CT-urography. If necessary, percutaneous nephrostomy with anterograde insertion of a JJ stent may be an option for a further intervention [21, 22, 23]. Conservative measures such as antibiotics and pain relief may suffice in milder cases [24–27]. Open surgery may also be considered in specific situations.

We are encouraged by the positive progress observed, with the extravasation being spontaneously absorbed within one month of the stenting. In rare cases, a nephrostomy tube may be needed to drain the urinoma. However, our follow-up at four and six months has revealed complete restoration of the pelvicalyceal system and ureter wall, with no signs of stenosis.

The spontaneous rupture of the upper urinary tract is a rare condition, often caused by obstructive uropathy from obstructive nephrolithiasis. In the four cases we examined, rupture occurred spontaneously due to renal colic. Endoscopic treatment, which included desobstruction and placement of a ureteral stent, effectively managed the symptoms. Patient follow-ups involved clinical observations, laboratory tests, ultrasound monitoring, and CT-urography. The stent remained in place for an average of 2.5 months, sufficient for complete symptom control. Timely diagnosis and treatment resulted in the complete restoration of wall integrity, spontaneous resorption of extravasation, and the absence of complications [28].

## ACKNOWLEDGMENT

Authors are grateful for the valuable support of Prof. Dr. Marin Georgiev, PhD, chief of the Department of Urology, Alexandrovska University Hospital (Bulgaria), Prof. Dr. Krasimir Yanev, PhD, chief of the Department of Urology, Medical University of Sofia (Bulgaria), Asst. Prof. Dr. Plamen Dimitrov, PhD (Bulgaria), Department of Urology, Alexandrovska University Hospital, Prof. Maria Nedevska, PhD, chief of Department of Imaging Diagnostics, St. Ekaterina University Hospital, Sofia (Bulgaria), Dr. Evgenia Mihaylova, PhD, Department of Imaging Diagnostics, St. Ekaterina University Hospital, Sofia (Bulgaria), and Dr. Magdalena Belyanova, PhD, Department of Imaging Diagnostics, Alexandrovska University Hospital, Sofia (Bulgaria).

**Conflict of interest:** None declared.

## REFERENCES

- Eken A, Akbas T, Arpacı T. Spontaneous rupture of the ureter. *Singapore Med J.* 2015;56(2):e29–e31. [DOI: 10.11622/smedj.2015029] [PMID: 25715862]
- Lee J, Darcy M. Renal cysts and urinomas. *Semin Intervent Radiol.* 2011;28(4):380–91. [DOI: 10.1055/s-0031-1296080] [PMID: 23204636]
- Caruso Lombardi A, Rinaldi MF, Bartalena T, Elmi F, Mughetti M. Urinary ascites due to retroperitoneal fibrosis: a case report. *Acta Radiol.* 2007;48(1):119–21. [DOI: 10.1080/02841850601067660] [PMID: 17325937]
- Akpinar H, Kural AR, Tüfek İ, Obek C, Demirkesen O, Solok V, et al. Spontaneous ureteral rupture: is immediate surgical intervention always necessary? Presentation of four cases and review of the literature. *J Endourol.* 2002;16(3):179–83. [DOI: 10.1089/089277902753716160] [PMID: 12028629]
- Chen SC, Liu WC, Wang CS, Jang MY, Lin HY, Lee SC, et al. Iatrogenic rupture of the ureter during kidney biopsy. *Kaohsiung J Med Sci.* 2010;26(9):502–5. [DOI: 10.1016/S1607-551X(10)70079-6] [PMID: 20837348]
- Trottmann M, Tritschler S, Graser A, Strittmatter F, Becker A, Haseke N, et al. Verletzungen des Nierenbeckens und des Ureters. Diagnostik und Management [Injuries of the renal pelvis and ureter. Diagnosis and management]. *Urologe A.* 2007;46(8):927–34; quiz 935–6. [Article in German] [DOI: 10.1007/s00120-007-1373-y] [PMID: 17628782]
- Huang E, Sayegh R, Craigo S, Chelmos D. Rupture of the renal pelvis associated with intravenous fluid bolus. *J Matern Fetal Neonatal Med.* 2002;11(5):345–6. [DOI: 10.1080/jmf.11.5.345.346] [PMID: 12389678]
- Deen S, Ogbu E, Walker NF, Nkwam NM. Spontaneous ureteric rupture due to high pressure chronic retention. *JRSM Open.* 2022;13(3):20542704221077556. [DOI: 10.1177/20542704221077556] Erratum in: *JRSM Open.* 2024;15(6):20542704241260165. [DOI: 10.1177/20542704241260165] [PMID: 35280437]
- Jamil SB, Munir M, Patoli I, Rehmani S. An Interesting Case of Critical Spontaneous Ureteral Rupture. *Cureus.* 2021;13(8):e17497. [DOI: 10.7759/cureus.17497] [PMID: 34595074]
- Spinelli MG, Palmisano F, Zanetti SP, Boeri L, Gadda F, Talso M, et al. Spontaneous upper urinary tract rupture caused by ureteric stones: A prospective high-volume single centre observational study and proposed management. *Arch Esp Urol.* 2019;72(6):590–5. English, Spanish. [PMID: 31274124]
- Tylski M, Muras-Szwedziak K, Nowicki M. Idiopathic Spontaneous Rupture of Renal Pelvis in a Single Functioning Kidney. *Case Rep Nephrol Dial.* 2021;11(2):221–6. [DOI: 10.1159/000512588] [PMID: 34414214]
- Huang E, Sayegh R, Craigo S, Chelmos D. Rupture of the renal pelvis associated with intravenous fluid bolus. *J Matern Fetal Neonatal Med.* 2002;11(5):345–6. [DOI: 10.1080/jmf.11.5.345.346] [PMID: 12389678]
- Chiancone F, Meccariello C, Ferraiuolo M, De Marco GP, Fedelini M, Langella NA, et al. A rare case of spontaneous parenchymal kidney explosion in a patient with ureteral obstruction caused by a single stone. *Urologia.* 2021;88(4):386–8. [DOI: 10.1177/0391560320975881] [PMID: 33245029]
- Yavuzsan AH, Baloğlu IH, Albayrak AT, Bursali K, Demirel HC. Spontaneous Kidney Rupture: Two Case Reports With Unusual Presentations. *Cureus.* 2021;13(5):e15332. [DOI: 10.7759/cureus.15332] [PMID: 34221775]
- Shah JN, Gandhi D, Prasad SR, Sandhu PK, Banker H, Molina R, et al. Wunderlich Syndrome: Comprehensive Review of Diagnosis and Management. *Radiographics.* 2023;43(6):e220172. [DOI: 10.1148/rg.220172] Erratum in: *Radiographics.* 2023;43(7):e239007. [DOI: 10.1148/rg.239007] [PMID: 37227946]
- Zhang H, Zhuang G, Sun D, Deng T, Zhang J. Spontaneous rupture of the renal pelvis caused by upper urinary tract obstruction: A case report and review of the literature. *Medicine (Baltimore).* 2017;96(50):e9190. [DOI: 10.1097/MD.0000000000009190] [PMID: 29390332]
- Taken K, Oncü MR, Ergün M, Eryılmaz R, Güneş M. Isolated renal pelvis rupture secondary to blunt trauma: Case report. *Int J Surg Case Rep.* 2015;9:82–4. [DOI: 10.1016/j.ijscr.2015.02.044] [PMID: 25734319]
- Pampuna E, Altobelli S, Morini M, Ricci A, D'Onofrio S, Simonetti G. Spontaneous ureteral rupture diagnosis and treatment. *Case Rep Radiol.* 2013;2013:851859. [DOI: 10.1155/2013/851859] [PMID: 24455381]
- Choi SK, Lee S, Kim S, Kim TG, Yoo KH, Min GE, et al. A rare case of upper ureter rupture: ureteral perforation caused by urinary retention. *Korean J Urol.* 2012;53(2):131–3. [DOI: 10.4111/kju.2012.53.2.131] [PMID: 22379594]
- Eken A, Akbas T, Arpacı T. Spontaneous rupture of the ureter. *Singapore Med J.* 2015;56(2):e29–31. [DOI: 10.11622/smedj.2015029] [PMID: 25715862]
- Pace K, Spiteri K, German K. Spontaneous proximal ureteric rupture secondary to ureterolithiasis. *J Surg Case Rep.* 2017;2016(11):rjw192. [DOI: 10.1093/jscr/rjw192] [PMID: 28069871]
- Assaker R, El Hasbani G, Thomas G, Sapire J, Kaye A. Spontaneous rupture of the renal calyx secondary to a vesicoureteral junction calculus. *Clin Imaging.* 2020;60(2):169–71. [DOI: 10.1016/j.clinimag.2019.10.021] [PMID: 31927172]
- Chiu TM, Fung KKF, Kan EYL. Rupture of Renal Pelvis Secondary to Obstructing Calculus in Menkes Disease: A Case Report. *Hong Kong J Radiol.* 2023;26:194–7. [DOI: 10.12809/hkj2117505]
- Tang W, Yang D, Wu T, Liang G. Delayed bilateral spontaneous renal rupture after surgery for unilateral upper ureteral calculi: a case report. *Front Med (Lausanne).* 2023;10:1173386. [DOI: 10.3389/fmed.2023.1173386] [PMID: 37869167]
- Yin G, Pan X, Tian H, Zhou Z, Li J, Tian F, et al. Spontaneous renal rupture due to renal calculi: A case report and literature review. *Exp Ther Med.* 2022;24(3):588. [DOI: 10.3892/etm.2022.11525] [PMID: 35949332]
- Yavuzsan AH, Baloğlu IH, Albayrak AT, Bursali K, Demirel HC. Spontaneous Kidney Rupture: Two Case Reports With Unusual Presentations. *Cureus.* 2021;13(5):e15332. [DOI: 10.7759/cureus.15332] [PMID: 34221775]
- Tawfick A, Matboli M, Shamloul S, Agwa SHA, Saad M, Shaker H, et al. Predictive urinary RNA biomarkers of kidney injury after extracorporeal shock wave lithotripsy. *World J Urol.* 2022;40(6):1561–7. [DOI: 10.1007/s00345-022-03996-3] [PMID: 35428927]
- Chua TWL, Wong E. Spontaneous Ureteric Rupture and Its Implications in the Emergency Department: A Case Report. *Clin Pract Cases Emerg Med.* 2021;5(2):167–70. [DOI: 10.5811/cpcem.2021.2.50652] [PMID: 34436996]

## Спонтана руптура горњег уринарног тракта као резултат уролитијазе

Валентин Јотовски, Славина Котова, Методиј Милушев, Цветан Лазаров, Александар Крастанов

Универзитетска болница „Александровска“, Уролошка клиника, Софија, Бугарска;  
Медицински универзитет у Софији, Одељење урологије, Софија, Бугарска

### САЖЕТАК

**Увод** Спонтана руптура кавитарног система горњег уринарног тракта (пијелокаликсног система и уретера) ретка је патологија. Представља спонтано цурење мокраће ван кавитарног система, без основне трауме или јатрогене интервенције, најчешће као резултат опструктивне уропатије и повећаног интралуминалног притиска.

Овај рад наглашава важност брзе дијагностике и правовременог лечења како би се обновио интегритет зида без значајне стенозе.

**Приказ болесника** Приказујемо четири случаја спонтане руптуре код уролитијазе. Просечна старост болесника била

је 47,5 година. Клиничка слика подсећа на бубрежне колике. За постављање дијагнозе користили смо ехографију, СТ-урографију, ретроградну пијелографију. Лечење подразумева фиксацију JJ стента у просеку два и по месеца. Код свих болесника благовремена дијагноза и лечење обезбеђују потпуни опоравак зида пијелокаликсног система и уретера уз спонтану ресорпцију екстравазације и без значајних стриктура уретера.

**Закључак** Добри резултати наглашавају важност правовремене дијагнозе и лечења спонтаних руптура уретера и дају наду у повољан развој у будућим случајевима.

**Кључне речи:** уролитијаза; спонтана руптура; екстравазација