



## CASE REPORT / ПРИКАЗ БОЛЕСНИКА

# Primary subtalar arthrodesis with percutaneous screw fixation and bone grafting through mini-open sinus tarsi approach for Sanders type IV bilateral calcaneal fracture – three-year follow-up case report

Želimir Jovanović<sup>1</sup>, Lazar Mičeta<sup>1,2</sup>, Nemanja Jovanović<sup>1</sup>, Danilo Jeremić<sup>1,2</sup>, Nemanja Slavković<sup>1,2</sup>

<sup>1</sup>Banjica Institute for Orthopaedics, Belgrade, Serbia;

<sup>2</sup>University of Belgrade, Faculty of Medicine, Belgrade, Serbia

## SUMMARY

**Introduction** Calcaneus fractures are rare but potentially debilitating injuries. Most of them are displaced intraarticular fractures, whose management is among controversial issues. There is no consensus on whether to operate or not. The most often chosen surgical treatment is open reduction and internal fixation as the primary method. Failure of this surgery often needs secondary subtalar arthrodesis as definitive management, so primary subtalar arthrodesis in cases with severe comminution represents definitive treatment in one stage with good functional results.

**Case outline** We present a case of a 54-year-old male patient with a severely comminuted (Sanders type IV) bilateral calcaneus fracture. After the withdrawal of local swelling and disappearance of fracture blisters, the patient was operated on using one-stage bilateral subtalar arthrodesis with percutaneous screw fixation and bone grafting performed through a mini-open sinus tarsi approach. The early post-operative period was uneventful. The patient did not walk for the first seven postoperative weeks, after which rehabilitation was continued with partial weight bearing with a gradual increase of weight-bearing to full over the next five weeks, after which walking aids were completely phased out. Three years after surgery, the patient has no symptoms and has a close-to-normal gait.

**Conclusion** Although this type of injury has traditionally been treated with open reduction and internal fixation, we believe that primary subtalar arthrodesis with bone grafting through a mini-open sinus tarsi approach can benefit patients with severe comminution of calcaneus, allowing good functional results and patient satisfaction, with fewer postoperative complications and faster definitive recovery.

**Keywords:** intra-articular fractures; calcaneus; subtalar joint; arthrodesis

## INTRODUCTION

Fractures of the calcaneus are rare, potentially debilitating injuries, which represent a therapeutic challenge even for an experienced surgeon. About 60–75% of calcaneus fractures are displaced intraarticular fractures (DIACF) [1, 2]. Operative and nonoperative treatment of DIACF have similar results, but some patient groups benefit from surgery more than others. The most widespread surgical treatment is open reduction and internal fixation (ORIF), but the results are not uniformly satisfactory. Failure to achieve an anatomical reduction of the articular surface leads to the development of painful arthrosis of the subtalar joint, requiring secondary arthrodesis in many cases [2]. This led to primary subtalar arthrodesis (PSTA) as the appropriate treatment method for DIACF [2, 3].

This paper aims to present a case of a patient with Sanders type IV calcaneus fracture treated by reduction and PSTA through a mini-open sinus-tarsi approach with osteoplasty with a graft from the bone bank and the results of a three-year follow-up.

## CASE REPORT

The patient, a 54-year-old male, sustained a bilateral calcaneus fracture accompanied by swelling, limited range of motion (ROM), and palpatory pain after a fall from a height of three meters. There were no skin or neurovascular lesions. The patient's history revealed that he is a smoker. Radiography and CT scan showed Sanders type IV intraarticular fractures of both feet (Figure 1).

The patient was initially immobilized with compressive Robert Jones bandages. Throughout the following days, swelling of soft tissue developed in the hindfoot, and occasional fracture blisters started to appear.

The operative procedure was performed 16 days after the injury, after reducing swelling and withdrawal of fracture blisters. Surgery was performed in two acts: first on the left foot, then on the right with a patient in lateral decubitus position. Preoperatively, tourniquet cuffs were placed on both lower legs but inflated separately.

The incision, approximately 4 cm long, was made above the projection of sinus tarsi. Extraction of the articular cartilage of the

**Received • Примљено:**  
February 6, 2023

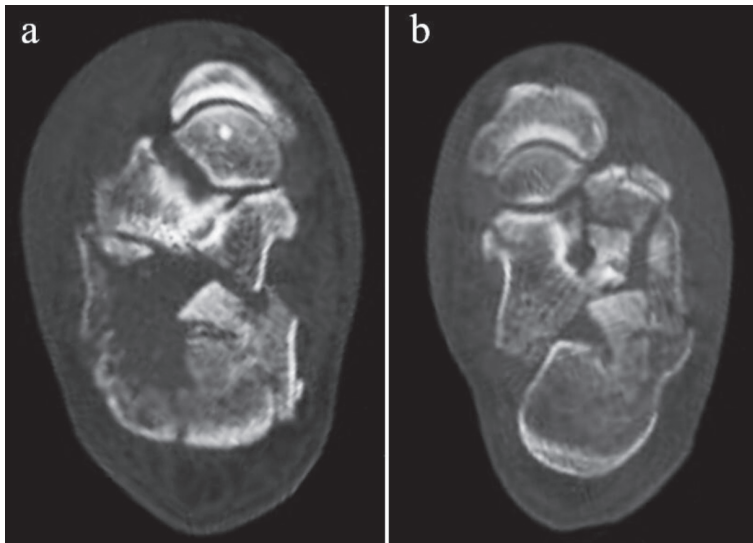
**Revised • Ревизија:**  
October 26, 2023

**Accepted • Прихваћено:**  
October 28, 2023

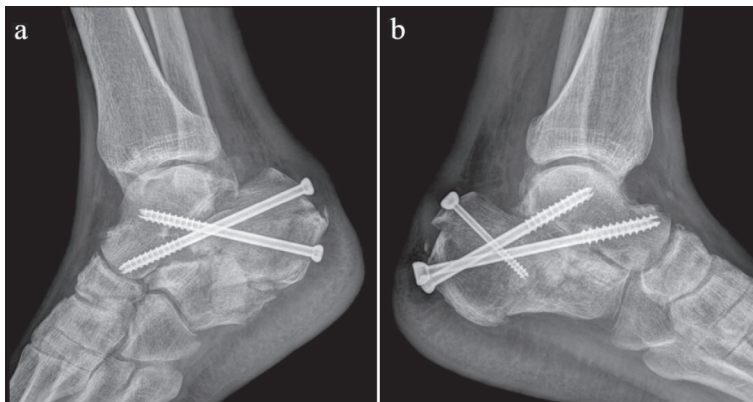
**Online first:** November 15, 2023

### Correspondence to:

Lazar D. MIČETA  
Banjica Institute for Orthopaedics  
Mihaila Avramovića 28  
11040 Belgrade, Serbia  
[lmiceta@yahoo.com](mailto:lmiceta@yahoo.com)



**Figure 1.** CT scan of both feet on admission showing severely displaced comminuted fracture of both calcaneus; a) right calcaneus fracture; b) left calcaneus fracture



**Figure 2.** Immediate postoperative lateral X-rays; plain radiograph obtained immediately after surgery; a) right foot; b) left foot

talocalcaneal joint was performed. The articular space and bone defect were filled with a combination of allogenic cancellous bone grafts from our institution's bone bank and extracted bone parts of the fractured calcaneus.

The reduction of major fragments was performed by percutaneous manipulation using a Schanz screw. Fixation of fragments was obtained with two K-wires advanced from calcaneus tuberosity to the talus body. Two cannulated screws of 7 mm in diameter and 105 mm and 120 mm in length were introduced over the wires, ensuring definitive fixation of the fragments and arthrodesis of the talocalcaneal joint. The posterior-upper fragment was reduced percutaneously by another Schanz crew and then fixed with a cannulated screw 5 mm in diameter and 50 mm in length.

After fluoroscopic evaluation and wound closure, Robert Jones dressing was applied, and the patient was rolled over to the other side. Then the talocalcaneal joint of the right leg was approached in the same manner, and the same procedure was performed, with the difference of using two cannulated screws of 7 mm in diameter and 95 mm and 105 mm in length (Figure 2).

The early postoperative period was uneventful. On the sixth postoperative day, the patient was discharged, and suture removal was performed on the 14th postoperative day.

For the first seven postoperative weeks, the patient was without weight-bearing. Ankle joints' ROM was slightly limited and painless, and there was no motion in the subtalar joints. For the next five weeks, rehabilitation was continued with partial weight bearing on the forefoot and the application of silicone heel pads in footwear.

After 12 weeks, the patient was able to walk independently with crutches. In both ankles, ROM was close to physiological. Slightly lowered, painless feet arches were noted bilaterally. The patient gradually phased out walking aids and started with full-weight bearing.

Five months after surgery, the patient could walk normally, with full-weight bearing and without walking aids. The total AOFAS (American Orthopedic Foot and Ankle Society Score) was 73 of 100 (pain 30/40; function 38/50; alignment 5/10).

On three more check-ups, 11 months, 24 months, and 35 months after surgery, the patient exhibited no significant symptoms, with AOFAS scores of 72, 73, and 73, respectively, and a close-to-normal gait (Video 1), and complete return to normal life activities, including working as an electrician, as before the injury.

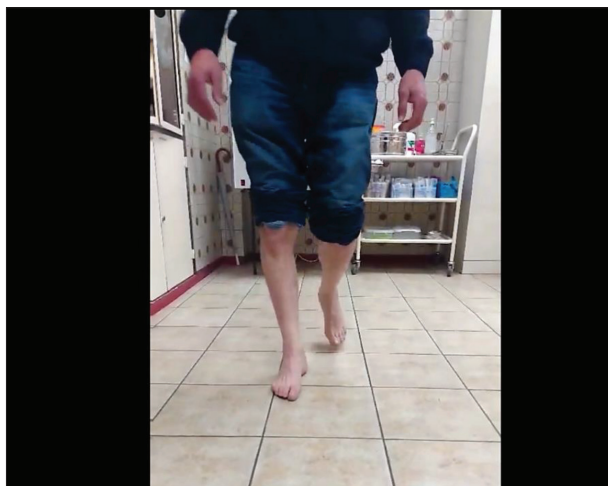
The patient has given his written consent for the publication of data in this case report. The ethics committee of the Institute for Orthopaedics Banjica decided that this paper does not require ethics committee approval (Decision number I-113/20).

## DISCUSSION

The outcome of surgical treatment of DIACF is uncertain. The risk of postoperative complications is the most common reason why surgeons continue to opt for non-surgical treatment.

There are indications that less displaced DIACF treated non-operatively have similar functional results as operatively treated ones [3]. Some authors did not find a statistically significant difference in the outcome between the operative and nonoperative treatment of DIACF, emphasizing the risk of postoperative complications [4]. Nevertheless, the prevailing view is that surgical treatment of these fractures gives better functional results than non-operative treatment [3]. Buckley et al. [5] reported significantly better functional outcomes in surgically treated patients.

The most commonly used approach for the calcaneus is the extensive lateral approach, allowing good visualization and can result in difficult wound healing and is more prone to bone infections, scarring, and arthrofibrosis of the subtalar joint. One of the less invasive approaches is through sinus tarsi (STA). Shortening the operative incision only to



**Video 1.** Representative still – patient gait three years after the operation; available at: [srpskiarhiv.rs/global/doc/42577-Other-259068-1-2-20230206.flv](https://srpskiarhiv.rs/global/doc/42577-Other-259068-1-2-20230206.flv)

the space immediately above the tarsal sinus (Mini-STA) enables satisfactory visualization with minimal trauma to the soft tissues [6].

Mini-STA and classical STA can be combined with percutaneous techniques to reduce and fix large bone fragments. Several authors presented their results with lower postoperative complications with adequate repositioning and stabilization of the subtalar joint when using STA compared to the extensive lateral approach [7, 8]. Holmes [7] reported that after 18 years of STA use, he did not encounter any complications associated with wound healing or soft tissue and bone infection. Joseph et al. [9] reported a higher percentage of complications after an extensive lateral approach compared with STA, but without statistical significance, bearing in mind that patients treated using STA were operated on earlier. Syros et al. [10] reported in their retrospective study of 36 high-risk patients with DIACF treated with STA that a short time to surgery had a negative impact on wound complication rate. Two separate meta-analyses concluded that, in the treatment of DIACF, the extensive lateral approach had significantly more complications than other, less invasive methods, with isolated percutaneous screw fixation being the one with the least complication [11, 12]. Yin et al. [13] indicated that the surgeon's volume (number of performed operations) in treating DIACF is directly correlated with the number of complications, stating that low-volume surgeons have almost 15% more complications.

In patients with Sanders type IV fractures, there have not yet been found significant differences in the outcome between ORIF and PSTA, and a low number of patients and quality studies are limiting factors for reaching a definitive conclusion. The advantages of PSTA include shorter treatment time, shorter postoperative recovery and absence from work, and lower treatment costs [14].

The results of ORIF in multisegmental DIACF can be uncertain. In Sanders type IV fracture, anatomical reposition, good joint congruence, and stable fixation are challenging to achieve, and many authors advocate using PSTA

as the treatment method [3, 15]. Even when anatomical reconstruction and stable fixation are achieved, early post-traumatic arthrosis of the subtalar joint may occur. Potenza et al. [2] reported good to excellent functional results after a five-year follow-up in six patients (seven calcanei) with Sanders IV type of fracture managed using PSTA through sinus tarsi approach with cannulated screws and filling of the bone defect with heterologous grafts.

Huefner et al. [16] state that in 2–17% of patients, it is necessary to perform secondary subtalar arthrodesis due to a degenerative disease that developed after reduction and osteosynthesis. They further report good to excellent results after open reduction and PSTA in patients with Sanders IV fracture, and the patients' return to total working activities was observed within 6.4 months on average. In performed expected value decision analysis Eisenstein et al. [17] concluded that performing ORIF with PSTA is optimal for patients with DIACF, compared with isolated ORIF surgery.

It is necessary to point out that obliteration of the subtalar joint reduces ROM of the foot, affects normal gait, and can cause diminished functionality. Almeida et al. [1] reported a slightly higher average AOFAS score in PSTA than in the osteosynthesis groups, ranging 65.8–86.8 and 62–82.4, respectively. Considering that our patient had a total AOFAS score of 73 out of 100 three years after surgery, it encouraged us to give even more space to PSTA as the solution for DIACF.

A study which included 424 non-operatively and operatively treated patients stated that 10% required secondary arthrodesis of the subtalar joint [5]. For certain patients, secondary subtalar arthrodesis was more common: men who do hard physical work, workers who receive compensation for injuries at work, patients with Sanders type IV fracture, and lower Böhler angle [5]. Sanders et al. [18] stated that the results of ORIF of type IV fractures are unpredictable even with experienced surgeons performing operations because successful anatomical repositioning and stable fixation are extremely difficult to achieve and that better results can be obtained by performing PSA.

The advantages of using bone grafts are reflected in the stimulation of fracture healing and a shortening of the period to full weight-bearing, increasing mechanical support of the calcaneus, and avoiding its collapse and post-traumatic arthrosis of the subtalar joint. Singh et al. [19] reported similar results in patients undergoing calcaneus osteosynthesis with or without bone grafts but with earlier full weight-bearing and better re-establishment of calcaneus anatomy in the group where bone grafts were used.

Despite the adequate choice of treatment, DIACF can cause severe patient disability. Performing PSTA in these patients reduces the risk of reintervention and shortens the postoperative recovery. The biggest obstacle to the widespread use of PSTA is the small number of reported patients treated this way. Our opinion is that the excellent results of treating our patient's extremely severe injuries should encourage others to use PSTA more often, improving their patient's quality of life.

**Conflicts of interest:** None declared.

## REFERENCES

- Almeida JF, Vale C, Gonzalez T, Gomes TM, Oliva XM. Osteosynthesis or primary arthrodesis for displaced intra-articular calcaneus fractures Sanders type IV – A systematic review. *Foot Ankle Surg.* 2022;28(3):281–7. [DOI: 10.1016/j.fas.2021.04.006] [PMID: 33893034]
- Potenza V, Caterini R, Farsetti P, Bisicchia S, Ippolito E. Primary subtalar arthrodesis for the treatment of comminuted intra-articular calcaneal fractures. *Injury.* 2010;41(7):702–6. [DOI: 10.1016/j.injury.2009.12.002] [PMID: 20074730]
- Sharr PJ, Mangupli MM, Winson IG, Buckley RE. Current management options for displaced intra-articular calcaneal fractures: Non-operative, ORIF, minimally invasive reduction and fixation or primary ORIF and subtalar arthrodesis. A contemporary review. *Foot Ankle Surg.* 2016;22(1):1–8. [DOI: 10.1016/j.fas.2015.10.003] [PMID: 26869492]
- Dickenson EJ, Parsons N, Griffin DR. Open reduction and internal fixation versus nonoperative treatment for closed, displaced, intra-articular fractures of the calcaneus: long-term follow-up from the HeFT randomized controlled trial. *Bone Joint J.* 2021;103-B(6):1040–6. [DOI: 10.1302/0301-620X.103B6.BJJ-2020-1962.R2] [PMID: 34058883]
- Buckley R, Tough S, McCormack R, Pate G, Leighton R, Petrie D, et al. Operative compared with nonoperative treatment of displaced intra-articular calcaneal fractures: a prospective, randomized, controlled multicenter trial. *J Bone Joint Surg Am.* 2002;84(10):1733–44. [DOI: 10.2106/00004623-200210000-00001] [PMID: 12377902]
- Liu GT, Vanpelt MD, Lalli T, Raspovic KM, Wukich DK. Surgical Management of Displaced Intra-Articular Calcaneal Fractures: What Matters Most? *Clin Podiatr Med Surg.* 2019;36(2):173–84. [DOI: 10.1016/j.cpm.2018.10.002] [PMID: 30784529]
- Holmes GB. Treatment of Displaced Calcaneal Fractures Using a Small Sinus Tarsi Approach. *Tech Foot Ankle Surg.* 2005;4(1):35–41. [DOI: 10.1097/01.btf.0000156336.58175.e1]
- Khazen G, Rassi CK. Sinus Tarsi Approach for Calcaneal Fractures: The New Gold Standard? *Foot Ankle Clin.* 2020;25(4):667–81. [DOI: 10.1016/j.fcl.2020.08.003] [PMID: 33543722]
- Joseph NM, Sinkler MA, Magister S, Bacharach A, Pang A, Boes K, et al. Fixation of displaced intra-articular calcaneus fractures is safe using either sinus tarsi or extensile lateral approach. *Injury.* 2023;S0020-1383(23)00168–7. [DOI: 10.1016/j.injury.2023.02.036] Online ahead of print. [PMID: 36878733]
- Syros A, Perez J, Hodgens BH, Boden AL, Constantinescu DS, Smith B, et al. Sinus tarsi approach in high-risk patients with displaced intra-articular calcaneus fractures: A case series. *J Orthop.* 2022;34:282–7. [DOI: 10.1016/j.jor.2022.09.009] [PMID: 36158039]
- Zhang L, Su P, Li J. Complications in the Management of Displaced Intra-articular Calcaneal Fractures: A Systematic Review and Network Meta-Analysis of 2538 Patients. *J Foot Ankle Surg.* 2022;61(6):1348–56. [DOI: 10.1053/j.jfas.2022.07.001] [PMID: 35934608]
- Shi F, Wu S, Cai W, Zhao Y. Comparison of 5 Treatment Approaches for Displaced Intra-articular Calcaneal Fractures: A Systematic Review and Bayesian Network Meta-Analysis. *J Foot Ankle Surg.* 2020;59(6):1254–64. [DOI: 10.1053/j.jfas.2020.03.021] [PMID: 32828631]
- Yin H, An Y, Dong L. Surgeon case volume and the risk of complications following surgeries of displaced intra-articular calcaneal fracture. *Foot Ankle Surg.* 2022;28(7):1002–7. [DOI: 10.1016/j.fas.2022.02.003] [PMID: 35177328]
- Buckley R, Leighton R, Sanders D, Poon J, Coles CP, Stephen D, et al. Open Reduction and Internal Fixation Compared With ORIF and Primary Subtalar Arthrodesis for Treatment of Sanders Type IV Calcaneal Fractures. *J Orthop Trauma.* 2014;28(10):577–83. [DOI: 10.1097/BOT.000000000000191] [PMID: 24983433]
- Schepers T. The primary arthrodesis for severely comminuted intra-articular fractures of the calcaneus: a systematic review. *Foot Ankle Surg.* 2012;18(2):84–8. [DOI: 10.1016/j.fas.2011.04.004] [PMID: 22443992]
- Huefner T, Thermann H, Geerling J, Pape HC, Pohlemann T. Primary subtalar arthrodesis of calcaneal fractures. *Foot Ankle Int.* 2001;22(1):9–14. [DOI: 10.1177/107110070102200102] [PMID: 11206830]
- Eisenstein ED, Kusnezov NA, Waterman BR, Orr JD, Blair JA. Open reduction and internal fixation (ORIF) versus ORIF and primary subtalar arthrodesis for complex displaced intraarticular calcaneus fractures: An expected value decision analysis. *OTA Int.* 2020;1(2):e005. [DOI: 10.1097/O19.000000000000005] [PMID: 33937643]
- Sanders R, Fortin P, DiPasquale T, Walling A. Operative treatment in 120 displaced intraarticular calcaneal fractures. Results using a prognostic computed tomography scan classification. *Clin Orthop Relat Res.* 1993;(290):87–95. [PMID: 8472475]
- Singh AK, Vinay K. Surgical treatment of displaced intra-articular calcaneal fractures: is bone grafting necessary? *J Orthop Traumatol.* 2013;14(4):299–305. [DOI: 10.1007/s10195-013-0246-y] [PMID: 23670493]

## Примарна супталарна артродеза са перкутаном фиксацијом завртњима и попуњавањем дефекта коштаном графтом кроз мини-отворен *sinus tarsi* приступ у решавању билатералног прелома калканеуса IV типа по Сандерсу – приказ болесника са трогодишњим периодом праћења

Желимир Јовановић<sup>1</sup>, Лазар Мичета<sup>1,2</sup>, Немања Јовановић<sup>1</sup>, Данило Јерemiћ<sup>1,2</sup>, Немања Славковић<sup>1,2</sup>

<sup>1</sup>Институт за ортопедију „Бањица“, Београд, Србија;

<sup>2</sup>Универзитет у Београду, Медицински факултет, Београд, Србија

### САЖЕТАК

**Увод** Преломи калканеуса су ретке, али потенцијално оне-способљавајуће повреде. Најчешће се ради о дислоцираним интраартикуларним преломима чије збрињавање представља једно од контроверзних питања. Не постоји консензус о томе да ли треба или не спровести оперативно лечење. Најчешће изабрани хируршки третман је отворена репозиција и унутрашња фиксација као примарни метод. Неуспех ове операције често захтева секундарну супталарну артродезу као дефинитивну меру лечења, тако да се примарна супталарна артродеза у случајевима са тешком коминуцијом показује као добар метод дефинитивног једноетапног лечења са добрим функционалним резултатима.

**Приказ болесника** Приказујемо случај 54-годишњег мушкарца са билатералним комунитивним (IV типом по Сандерсу) преломом калканеуса. После повлачења локалног отока и повлачења була, болесник је оперисан применом једноетапне билатералне супталарне артродезе са перкутаном фиксацијом уз попуњавање дефекта коштаном ало-

графтом кроз мини-отворен *sinus tarsi*. Рани постоперативни период је прошао без компликација. Првих седам постоперативних недеља болесник није ходао, након чега је рехабилитација настављена са ходом са делимичним ослонцем уз постепено повећање оптерећења током наредних пет недеља, а после тога су помагала за ходање потпуно укинута. Три године после операције болесник нема симптоме и хода скоро нормално.

**Закључак** Иако се ова врста повреде традиционално лечи отвореном репозицијом и унутрашњом фиксацијом, верујемо да примарна супталарна артродеза уз попуњавање дефекта коштаном алогграфтом кроз мини-отворен *sinus tarsi* може бити од користи болесницима са тешком комбинацијом калканеуса, омогућавајући добре функционалне резултате и задовољство пацијената, са мање постоперативних компликација и бржим опоравком.

**Кључне речи:** интраартикуларни преломи; калканеус; супталарни зглоб; артродеза