

## CASE REPORT / ПРИКАЗ БОЛЕСНИКА

# The presence of adenocarcinoma of the right colon and polyp in colonic graft in a female patient with colon interposition due to caustic stricture of the esophagus in childhood

Stojan Latinčić<sup>1,2</sup>, Maja Pavlov<sup>1,2</sup>, Jovica Vasiljević<sup>1,2</sup>, Dragan Vasin<sup>1,3</sup>, Milena Papović<sup>2</sup><sup>1</sup>University of Belgrade, Faculty of Medicine, Belgrade, Serbia;<sup>2</sup>University Clinical Centre of Serbia, Clinic for Digestive Surgery – First Surgical Clinic, Belgrade, Serbia;<sup>3</sup>University Clinical Centre of Serbia, Emergency Department, Belgrade, Serbia**SUMMARY**

**Introduction** Colon interposition is considered an effective option for esophageal replacement in children, particularly in cases of caustic esophageal stricture. The use of colonic tissue grafts for esophageal replacement can lead to late complications, including the development of precancerous lesions and malignant tumors. The aim of the paper is to describe a female patient who was diagnosed with adenocarcinoma of the right colon at the age of 71, 60 years after surgery for benign esophageal stricture.

**Case outline** A 71-year-old female presented to our clinic in January 2023 with symptoms of abdominal pain. At the age of 11, the patient had bypass esophagocoloplasty with retrosternal esophagogastrocolonic anastomosis due to esophageal stricture after accidental caustic ingestion. CT imaging revealed tumor of the ascending colon, estimated stage T4aN1M0. An upper digestive endoscopic examination revealed one polyp while a lower digestive endoscopic examination confirmed the presence of a stenotic tumor in the ascending colon. Furthermore, a polypoid alteration was identified in the descending colon. CT angiography revealed that the tumor was found to receive its vascular supply through the middle colic artery, while the colonic transplant received its vascular supply through the right colic artery.

**Conclusion** It is recommended to implement lifelong endoscopic surveillance for patients who have undergone colon interposition. In cases such as this, it is crucial to establish a comprehensive treatment plan and employ effective diagnostic measures to ensure the preservation of the integrity and vascularization of the colonic graft.

**Keywords:** esophagocoloplasty; endoscopic resection; colon cancer

**INTRODUCTION**

Colon interposition is considered an effective option for esophageal replacement in children, particularly in cases of caustic esophageal stricture [1, 2]. The left transverse colonic graft, based on the left colic artery, is commonly used for this purpose, although the ascending or descending colon may also be utilized [3, 4, 5]. In the past, the retrosternal esophagogastric anastomosis was the most frequently employed procedure [6]. However, recent research has shown that the posterior mediastinal route may offer better outcomes for interposing the colon [7]. The choice between the retrosternal and posterior mediastinal routes for colon interposition has been a topic of debate [8]. The posterior mediastinal route has been shown to be shorter and associated with fewer cardiopulmonary complications and anastomotic leaks, potentially contributing to lower rates of hospital mortality [9].

The use of colonic tissue grafts for esophageal replacement can lead to late complications, including the development of precancerous lesions and malignant tumors. Some studies examined the late complications of colonic interposition grafts and found that the development

of malignant tumors was one of the potential complications. The study highlighted the importance of long-term follow-up and surveillance to detect and manage these complications in a timely manner [10]. So, it is crucial for healthcare professionals to be aware of these risks and to implement appropriate surveillance and management strategies to ensure the long-term health and well-being of patients who have undergone this procedure.

We present a female patient who was diagnosed with adenocarcinoma of the right colon at the age of 71, 60 years after surgery for benign esophageal strictures, where a left transversal colonic graft was used for replacement of the esophagus.

**CASE REPORT**

A 71-year-old female presented to our clinic in January 2023 with symptoms of abdominal pain; two months earlier, she had a fever. At the age of 11, the patient had bypass esophagocoloplasty with retrosternal esophagogastrocolonic anastomosis due to esophageal stricture after accidental caustic ingestion.

**Received • Примљено:**

August 15, 2022

**Revised • Ревизија:**

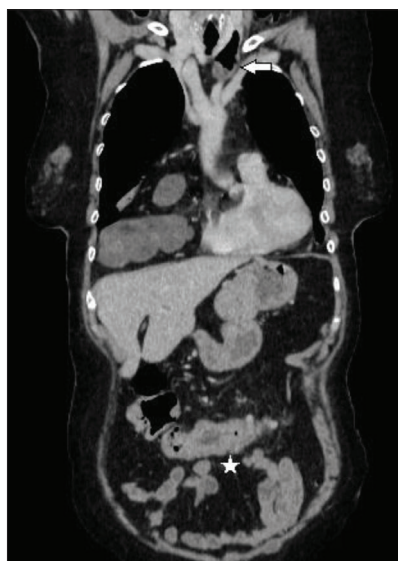
October 19, 2023

**Accepted • Прихваћено:**

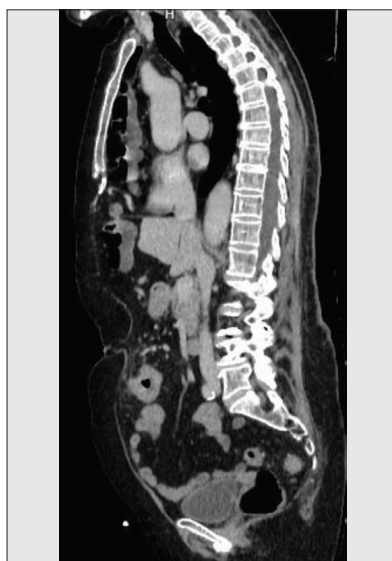November 13, 2023

**Online first:** November 15, 2023**Correspondence to:**

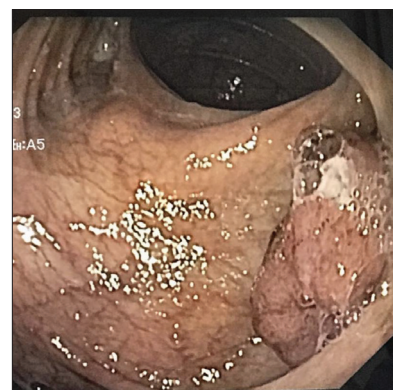Milena PAVOVIĆ  
University Clinical Centre of  
Belgrade  
Clinic for Digestive Surgery – First  
Surgical Clinic  
Koste Todorovića 6  
11000 Belgrade, Serbia  
[mina.papovic@yahoo.com](mailto:mina.papovic@yahoo.com)



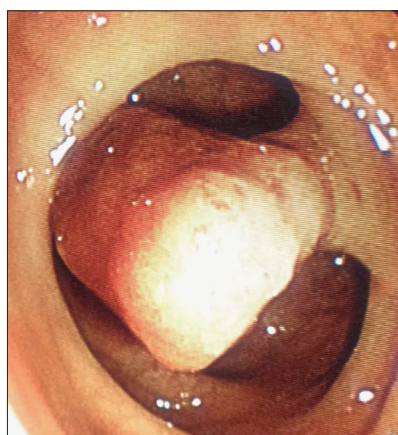
**Figure 1.** Coronal contrast-enhanced CT image demonstrates the colic transplant placed through the retrosternal space with esocolic anastomosis in the thorax (white arrow) and colonic tumor in the abdomen (white star)



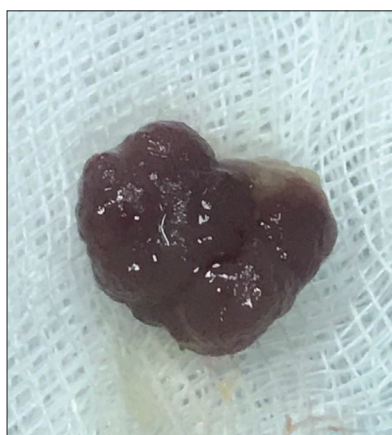**Figure 2.** Sagittal contrast-enhanced CT image shows the colic transplant placed through the retrosternal space and colonic tumor in the abdomen



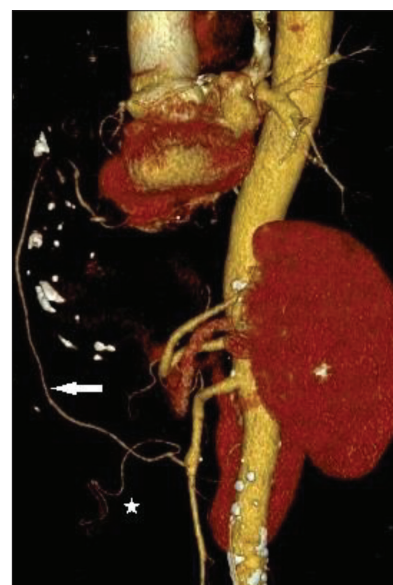**Figure 3.** An upper digestive endoscopic study revealed one polyp with a narrow base suitable for electroresection at 25 cm from the dental arch



**Figure 4.** A polypoid change in the descending colon



**Figure 5.** Electroresected polypoid change in the descending colon



**Figure 6.** Three-dimensional volume rendering CT angiography clearly shows abdominal vasculature, including the superior mesenteric artery with tumor vascular supply through the middle colic artery (white star) and colonic transplant vascular supply through the right colic artery (white arrow)

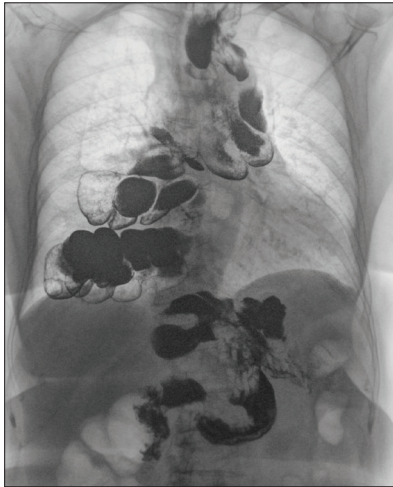
Chest, abdomen, and pelvic tomography imaging revealed segmental thickening of the wall of the ascending colon, measuring approximately 50 mm in length and with a wall thickness of up to 12 mm. The imaging also indicated signs of infiltration into the surrounding mesocolon (Figures 1 and 2). Staging performed using the same imaging modality identified individual lymph nodes in the surrounding mesocolon, measuring up to 10 × 7 mm. Notably, no signs of metastatic disease were observed, leading to an estimated stage of T4aN1M0. An upper digestive endoscopic study revealed one polyp with a narrow base suitable for electroresection at 25 cm of the dental arch (Figure 3). In addition, numerous diverticula and a tortuous lumen were observed distally with neat anastomoses.

Prior to the procedure, laboratory findings revealed physiological values for a carcinoembryonic antigen, as well as for 19-9 cancer antigen.

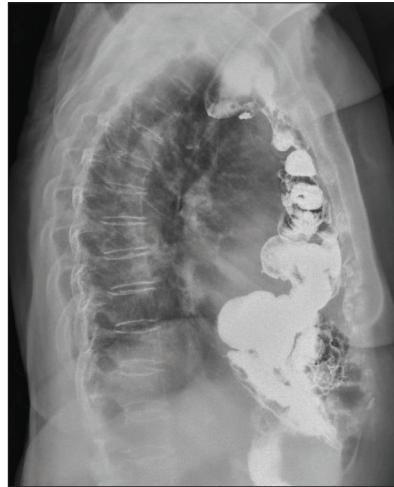In the subsequent diagnostic evaluation, a lower digestive endoscopic examination confirmed the presence of a stenotic tumor alteration in the ascending colon. Furthermore, a polypoid alteration was identified in the descending colon, which was deemed suitable for electroscopic resection (Figures 4 and 5). The pathohistological analysis of the electroresected polypoid alteration revealed the presence of *adenoma tubulare coli descendens* with *dysplasia epithelialis levis (I-II)*.

Considering that the operation was 60 years ago, we performed a CT colonography with angiography in order to preserve the vascularization of the colonic graft.

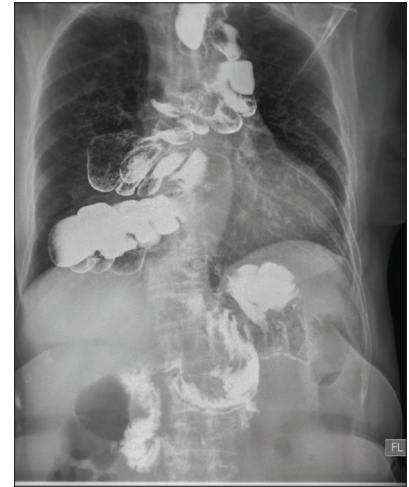CT colonography with angiography revealed a tumor located approximately 7 cm from the Bauhinia valve, measuring approximately 52 mm in length. Additionally, three-dimensional volume rendering CT angiography provided a clear visualization of the abdominal vasculature, including



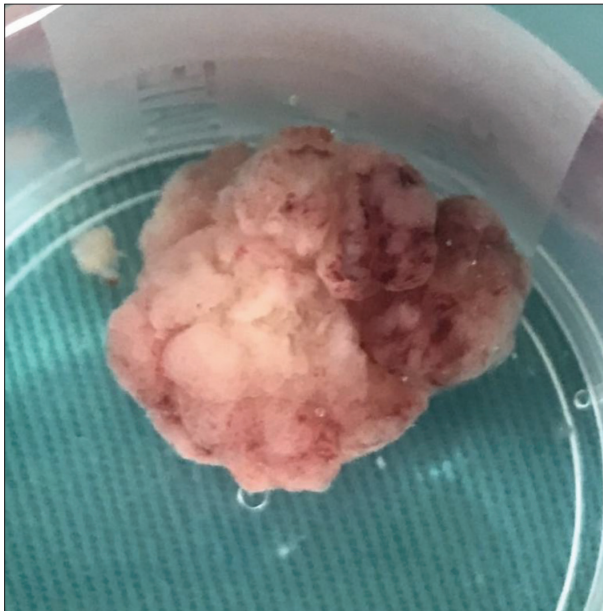
**Figure 7.** Barium swallow shows colon interposition with cervical esophago-colonic and abdominal gastrocolonic anastomosis



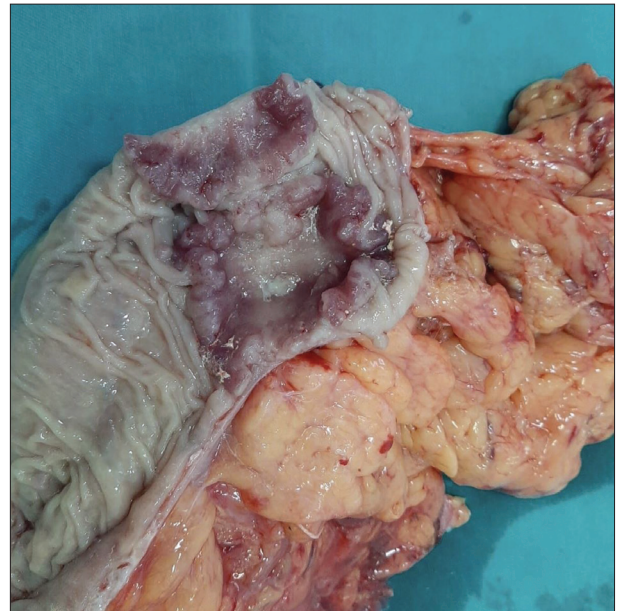
**Figure 8.** Barium swallow – lateral view shows retrosternal interposition of the colonic graft



**Figure 9.** Passage of the contrast through the colo-gastro terminolateral anastomosis



**Figure 10.** Electroresected polyp in the colonic graft



**Figure 11.** Specimen of the ascending colon with stenotic tumor

the superior mesenteric artery. The tumor was found to receive its vascular supply through the middle colic artery, while the colonic transplant received its vascular supply through the right colic artery (Figure 6).

Contrast radiography was performed to assess the functionality of the esophago-colo terminolateral (TL) anastomosis and colo-gastro TL anastomosis. The radiographic images revealed that the contrast passed unhindered through the esophago-colo TL anastomosis, which exhibited a normal width of the lumen (Figure 7). Similarly, the contrast smoothly passed through the colo-gastro TL anastomosis, which also displayed a normal lumen width (Figures 8 and 9).

The case was presented at a medical review board meeting and it was decided that, after induction into general anesthesia, endoscopic electroresection of the previously verified polyp in the colonic graft should be performed (Figure 10) before operation. Pathohistological finding of

the electroresected polyp was *adenoma tubulovillosum coli* with low epithelial dysplasia.

The patient underwent right hemicolectomy with ileocolic anastomosis. The procedure was uneventful, as was the postoperative period. The patient was discharged on the eighth postoperative day. Macroscopically, the tumor exhibited circumferential involvement and infiltration through all layers of the wall (Figure 11). Definitive pathological findings showed that it was adenocarcinoma stage T3c N0(0/17) M0 Bd1. The oncology council advised the use of adjuvant therapy with 5FU/LV. At the regular follow-up the patient was without complaints. Control radiography was without signs of recurrence.

The authors declare that the article was written according to ethical standards of the Serbian Archives of Medicine as well as ethical standards of medical facilities for each author involved. The patient's written consent was obtained for the writing of this case report.

## DISCUSSION

Caustic esophageal stricture is a common indication for esophageal replacement in children. In pediatric patients, colon conduit has been found to be a suitable substitute for the esophagus, particularly when utilizing the retrosternal technique. The use of colon interposition as a conduit for esophageal replacement has been well-documented in the literature [11, 12]. Colon interposition has been shown to be the most suitable type of reconstruction for esophageal corrosive strictures, with excellent functional results and low rates of postoperative morbidity and mortality. The choice of colon graft is based on the pattern of blood supply, and the type of anastomosis is determined by the stricture level and the part of the colon used for reconstruction [13]. Current reconstruction approaches typically involve the use of an autologous conduit such as the stomach, small bowel, or colon. However, these approaches are associated with high morbidity and mortality rates. Therefore, there is a critical need for alternative approaches to esophageal reconstruction [14].

Colonic replacement of the esophagus in children leads to significant anatomical modifications. Understanding the typical post-surgical changes and recognizing the imaging characteristics of frequently encountered complications can enhance diagnostic precision for radiologists and aid surgeons in devising appropriate treatment plans for these cases. The literature emphasizes the importance of recognizing the normal postoperative changes following colonic replacement of the esophagus. The authors highlighted the need for radiologists to be familiar with the expected anatomical alterations and to differentiate them from potential complications [15].

Adenoma and adenocarcinoma are recognized as potential late complications in colonic tissue grafts utilized for esophageal substitution [16, 17]. The occurrence of malignant tumors in the transposed colon is a rare long-term

complication associated with the irritation of the colonic mucosa by gastric acid content or bile. The prolonged passage time of food contents in the grafted colon, coupled with the absence of a sphincter, renders the grafted colon more susceptible to reflux from the stomach. Consequently, the grafted colon is exposed to noxious agents and carcinogens for a longer duration compared to the normal esophagus [18, 19]. Early detection and treatment are crucial in reducing morbidity and mortality rates [20].

Due to the rareness of respective cohort studies, the frequency of metachronous lesions cannot be calculated accurately. Sohn et al. [21] performed a systematic review in order to identify all reports on the development of metachronous adenoma and adenocarcinoma in colon interposition. The estimated rate of interval carcinoma is  $\leq 0.22\%$ . Considering that patients who receive the interposition procedure for benign pathologies are relevantly younger in general, their lifetime risk for the development of mucosal changes in the substitute is relatively higher [21]. Sterpetti and Sapienza [22] performed a systematic review to analyze the reports of *de-novo* adenocarcinoma arising in the transposed colon, where among 205 papers that were fully evaluated only 45 papers clearly reported patients with a transposed colon autograft in which a *de-novo* adenocarcinoma was diagnosed.

Adenocarcinoma of the interposed colon is a rare phenomenon, and the exact incidence remains unclear. However, due to the potential risk, it is recommended to implement lifelong endoscopic surveillance for patients who have undergone colon interposition [23, 24, 25]. In cases such as this, it is crucial to establish a comprehensive treatment plan and employ effective diagnostic measures to ensure the preservation of the integrity and vascularization of the colonic graft.

**Conflict of interest:** None declared.

## REFERENCES

- Loukogeorgakis SP, Piero A. Replacement surgery for esophageal atresia. *Eur J Pediatr Surg.* 2013;23(3):182–90. [DOI: 10.1055/s-0033-1347915] [PMID: 23720209]
- Youn JK, Park T, Kim SH, Han JW, Jang HJ, Oh C, et al. Prospective evaluation of clinical outcomes and quality of life after gastric tube interposition as esophageal reconstruction in children. *Medicine (Baltimore).* 2018;97(52):e13801. [DOI: 10.1097/MD.00000000000013801] [PMID: 30593168]
- Larsson S, Lepore V, Cardillo G. Replacement of the oesophagus with a segment of colon: experience of 30 cases and technical considerations. *Acta Chir Scand.* 1990;156(11–12):789–93. [PMID: 2075776]
- Gündoğdu HZ, Tanyel FC, Büyükpamukçu N, Hiçsönmez A. Colonic replacement for the treatment of caustic esophageal strictures in children. *J Pediatr Surg.* 1992;27(6):771–4. [DOI: 10.1016/s0022-3468(05)80114-9] [PMID: 1501044]
- Irino T, Tsekrekos A, Coppola A, Scandavini CM, Shetye A, Lundell L, et al. Long-term functional outcomes after replacement of the esophagus with gastric, colonic, or jejunal conduits: a systematic literature review. *Dis Esophagus.* 2017;30(12):1–11. [DOI: 10.1093/dote/dox083] [PMID: 28881882]
- AbouZeid AA, Zaki AM, Radwan AB, Allam AM, Rawash LM, Mohammad SA. Colonic replacement of the esophagus: towards standardization of the technique. *J Pediatr Surg.* 2020;55(6):1145–51. [DOI: 10.1016/j.jpedsurg.2019.10.050] [PMID: 31718868]
- Booka E, Takeuchi H, Morita Y, Hiramatsu Y, Kikuchi H. What is the best reconstruction procedure after esophagectomy? A meta-analysis comparing posterior mediastinal and retrosternal approaches. *Ann Gastroenterol Surg.* 2023;7(4):553–64. [DOI: 10.1002/ags3.12685] [PMID: 37416735]
- Oida T, Mimatsu K, Kano H, Kawasaki A, Kuboi Y, Fukino N, et al. Anterior vs. posterior mediastinal routes in colon interposition after esophagectomy. *Hepatogastroenterology.* 2012;59(118):1832–4. [DOI: 10.5754/hge10213] [PMID: 22819902]
- Chan ML, Hsieh CC, Wang CW, Huang MH, Hsu WH, Hsu HS. Reconstruction after esophagectomy for esophageal cancer: retrosternal or posterior mediastinal route? *J Chin Med Assoc.* 2011;74(11):505–10. [DOI: 10.1016/j.jcma.2011.09.006] [PMID: 22100020]
- Neoral C, Aujesky R, Vrba R, Stašek M. The use of retrosternally placed colon in esophageal replacement. *Rozhl Chir.* 2018;97(7):301–8. [PMID: 30442011]
- Burgos L, Barrena S, Andrés AM, Martínez L, Hernández F, Olivares P, et al. Colonic interposition for esophageal replacement in children remains a good choice: 33-year median follow-up of 65 patients. *J Pediatr Surg.* 2010;45(2):341–5. [DOI: 10.1016/j.jpedsurg.2009.10.065] [PMID: 20152348]

12. Iascone C, Urbani L, Cavicchi F, Mascioli F, Sorrentino M, Pronio A, et al. Adenocarcinoma in the Intrathoracic Transposed Colon. *Ann Thorac Surg.* 2019;108(4):e223–e224. [DOI: 10.1016/j.athoracsur.2019.01.081] [PMID: 30878461]
13. Knezević JD, Radovanović NS, Simić AP, Kotarac MM, Skrobić OM, Konstantinović VD, et al. Colon interposition in the treatment of esophageal caustic strictures: 40 years of experience. *Dis Esophagus.* 2007;20(6):530–4. [DOI: 10.1111/j.1442-2050.2007.00694.x] [PMID: 17958730]
14. La Francesca S, Aho JM, Barron MR, Blanco EW, Soliman S, Kalenjian L, et al. Long-term regeneration and remodeling of the pig esophagus after circumferential resection using a retrievable synthetic scaffold carrying autologous cells. *Sci Rep.* 2018;8(1):4123. [DOI: 10.1038/s41598-018-22401-x] [PMID: 29515136]
15. AbouZeid AA, Mohammad SA, Rawash LM, Radwan AB, El-Asmar KM, El-Shafei E. The radiological assessment of colonic replacement of the esophagus in children: A review of 43 cases. *Eur J Radiol.* 2015;84(12):2625–32. [DOI: 10.1016/j.ejrad.2015.09.014] [PMID: 26431748]
16. Bando H, Ikematsu H, Fu KI, Oono Y, Kojima T, Minashi K, et al. A laterally-spreading tumor in a colonic interposition treated by endoscopic submucosal dissection. *World J Gastroenterol.* 2010;16(3):392–4. [DOI: 10.3748/wjg.v16.i3.392] [PMID: 20082488]
17. De Moura DTH, Ribeiro IB, Coronel M, De Moura ETH, Carvalho JR, Baba ER, et al. Primary adenocarcinoma arising in esophageal colon interposition for corrosive esophageal injury: a case report and review of the literature. *Endosc Int Open.* 2018;6(12):E1406–E1409. [DOI: 10.1055/a-0751-2812] [PMID: 30505933]
18. Grunner S, Gilshtein H, Kakiashvili E, Kluger Y. Adenocarcinoma in colonic interposition. *Case Rep Oncol.* 2013;6(1):186–8. [DOI: 10.1159/000350743] [PMID: 23626559]
19. Sterpetti AV, Marzo LD, Sapienza P. Risk factors for adenocarcinoma in the surgically transposed colon not exposed to the fecal stream. Etiological considerations extrapolated to sporadic colon carcinoma in the general population. *Eur J Surg Oncol.* 2021;47(5):931–4. [DOI: 10.1016/j.ejso.2020.10.026] [PMID: 33139129]
20. Hwang HJ, Song KH, Youn YH, Kwon JE, Kim H, Chung JB, et al. A case of more abundant and dysplastic adenomas in the interposed colon than in the native colon. *Yonsei Med J.* 2007;48(6):1075–8. [DOI: 10.3349/ymj.2007.48.6.1075] [PMID: 18159607]
21. Sohn M, Agha A, Trum S, Moser C, Gundling F, Hochrein A, et al. Frequency of Polyps and Adenocarcinoma in Colon Interposition After Esophagectomy in Adulthood – A Systematic Review. *Anticancer Res.* 2019;39(12):6419–30. [DOI: 10.21873/anticancer.13856] [PMID: 31810906]
22. Sterpetti AV, Sapienza P. Adenocarcinoma in the transposed colon: High grade active inflammation versus low grade chronic inflammation. *Eur J Surg Oncol.* 2019;45(9):1536–41. [DOI: 10.1016/j.ejso.2019.05.012. 15] [PMID: 31118132]
23. Ng DW, Ching Tan GH, Teo MC. Malignancy arising in a 41-year-old colonic interposition graft. *Asian J Surg.* 2016;39(1):45–7. [DOI: 10.1016/j.asjsur.2014.01.002] [PMID: 24637188]
24. Simões C, Moura M, Noronha Ferreira C, Rosa R, Freire JP, Carrilho Ribeiro L, et al. Lateral Spreading Tumor Arising in an Interposed Colonic Segment. *ACG Case Rep J.* 2019;6(10):e00245. [DOI: 10.14309/crj.0000000000000245] [PMID: 31832471]
25. Baek SH, Lee JH, Yoo DR, Kim HY, Jin M, Jang AR, et al. Colonic Intramucosal Cancer in the Interposed Colon Treated with Endoscopic Mucosal Resection: A Case Report and Review of Literature. *Clin Endosc.* 2019;52(4):377–81. [DOI: 10.5946/ce.2018.129] [PMID: 31370380]

## Аденокарцином десног колона и присуство полипа у колонином графту код болеснице код које је у детињству учињена колопластика због каустичне стенозе једњака

Стојан Латинчић<sup>1,2</sup>, Маја Павлов<sup>1,2</sup>, Јовица Васиљевић<sup>1,2</sup>, Драган Васин<sup>1,3</sup>, Милена Паповић<sup>2</sup>

<sup>1</sup>Универзитет у Београду, Медицински факултет, Београд, Србија;

<sup>2</sup>Универзитетски клинички центар, Клиника за дигестивну хирургију – Прва хируршка клиника, Београд, Србија;

<sup>3</sup>Универзитетски клинички центар, Ургентни центар, Београд, Србија

### САЖЕТАК

**Увод** Езофагоколопластика представља адекватну процедуру код деце са езофагеалном бенигном стенозом, нарочито у случају ингестије корозивног средства. Употреба колониног трансплантата у оваквим случајевима може довести до касних компликација, укључујући и развој преканцерозних лезија и малигну тумора. Циљ рада је приказ болеснице старости 71 годину код које је дијагностикован аденокарцином десног колона шездесет година после езофагоколопластике због бенигне стенозе једњака.

**Приказ болесника** Болесница старости 71 годину се јавила на нашу клинику са боловима у трбуху. Код ње је 60 година раније учињена езофагоколопластика са ретростерналном езофагогастроколонином анастомозом због стенозе једњака услед акциденталне ингестије корозивног средства. Преглед грудног коша и абдомена компјутеризованом томо-

графијом показао је тумор асцендентног колона, процењеног стадијума *T4aN1M0*. Ендоскопијом горњих партија дигестивног тракта верификован је један полип у колонином графту, док се колоноскопијом верификује стенозантна туморска промена асцендентног колона, као и полипоидна промена у десцендентном колону. *СТ* ангиографијом се верификује да тумор васкуларизује средња колична артерија, док колоници трансплантан добија васкуларизацију преко десне количне артерије.

**Закључак** Неопходно је дугорочно ендоскопско праћење болесника код којих је учињена езофагоколопластика. У случајевима као што је овај, неопходно је установити план лечења и применити ефикасне дијагностичке мере како би се очували интегритет и васкуларизација колониног графта.

**Кључне речи:** езофагоколопластика; ендоскопска ресекција; карцином дебелог црева