

CASE REPORT / ПРИКАЗ БОЛЕСНИКА

Radical resection and reconstruction of a large sternal chondrosarcoma

Željko Garabinović^{1,2}, Milan Savić^{1,2}, Nikola Čolić³, Milan Stojičić^{2,4}, Slaviša Zagorac^{2,5}¹University Clinical Center of Serbia, Clinic for Thoracic Surgery, Belgrade, Serbia;²University of Belgrade, Faculty of Medicine, Belgrade, Serbia;³University Clinical Center of Serbia, Center for Radiology and Magnetic Resonance Imaging, Belgrade, Serbia;⁴University Clinical Center of Serbia, Clinic for Burns, Plastic and Reconstructive Surgery, Belgrade, Serbia;⁵University Clinical Center of Serbia, Orthopedic and Traumatology Clinic, Belgrade, Serbia**SUMMARY**

Introduction Primary malignant tumors of the sternum are rare, with chondrosarcoma being the most common primary malignant tumor of the chest. The gold standard in treatment is surgical treatment with wide resection margins, where the rigidity of the chest wall must be ensured, with protection of internal organs with satisfactory lung function.

Case outline We present a 67-year-old patient in whom previous computed tomography and magnetic resonance imaging examinations confirmed a tumor mass involving the sternum with the associated ribs, with involvement of the soft tissues above. First, sternum resection was performed with partial resection of the associated ribs and soft tissues. Reconstruction and stabilization of the chest wall were achieved with two layers of polypropylene mesh and methyl methacrylate bone cement with antibiotics. We reconstructed the primary soft tissue defect with a combination of a large local fasciocutaneous flap raised from the abdomen and a smaller sliding flap from the chest. The secondary defect was reconstructed by wide undermining of the skin in the area of the anterior abdominal wall and a small Thiersch-type free skin graft. In the postoperative period, the flaps were vital, but there was necrosis of the free skin graft. That defect was closed secondary thanks to bandaging. Respiratory function was preserved.

Conclusion Surgical treatment is the main treatment for sternal chondrosarcoma. With an adequate preoperative and intraoperative approach, it is necessary to enable good postoperative oncological outcomes with the achievement of chest rigidity and satisfactory respiratory status.

Keywords: sternal chondrosarcoma; surgical treatment; reconstruction

INTRODUCTION

Primary malignant tumors arising from the sternum are a rare type of bone and soft tissue tumor. Chondrosarcoma is the most common primary malignant tumor of the chest, with an incidence of < 0.5 per million per year [1]. Due to the hypovascularity and slow rate of mitosis in chondrosarcomas, they are resistant to chemotherapy and radiation therapy [2]. Therefore, as the gold standard, a complete resection of the primary tumor with wide margins is the best therapeutic option for sternal chondrosarcomas [1, 3]. Excision of sternal tumors is difficult because of the anatomical proximity to neuromuscular structures and the limited surgical margins that can be achieved [2]. Reconstructive procedures must provide both, rigidity to protect the internal thoracic organs, and elasticity to maintain lung function [1].

The aim of this work is to present radical surgical resection of a rare case of sternal chondrosarcoma, as well as the method of reconstruction of the anterior chest wall defect after resection.

CASE REPORT

A 67-year-old patient was admitted to our clinic for surgical treatment of a tumor mass of the anterior chest wall. On admission, the patient states that the tumor appeared two years ago, with slow progression, no pain present, and no previous occurrence of bleeding. He denied any difficulty breathing, or weight loss. He had been treated for diabetes mellitus type 2, hypertension, has been obese and a smoker.

The physical findings were normal, except for a tumor mass fixed to the anterior chest wall, without pathological vascularization on the skin, size 17 × 10 cm, with protrusion above the level of the anterior chest wall 4 cm (Figure 1 and 2). A computed tomography (CT) and magnetic resonance imaging (MRI) examination of the chest verified a tumor mass involving the sternum and associated ribs, namely the third, fourth, fifth, sixth, and seventh rib on the right, and the third, fourth, fifth, and sixth rib on the left, with involvement of the covering muscles and subcutaneous tissue (Figure 3 and 4). A tumor biopsy was not performed before surgery because the tumor showed typical features of chondrosarcoma (slow growth, large size, localization).

Received • Примљено:

October 18, 2023

Accepted • Прихваћено:

December 9, 2023

Online first: January 12, 2024**Correspondence to:**

Željko GARABINOVIĆ

Sundečićeva 3E

11000 Belgrade

zeljkogarabinovic@gmail.com

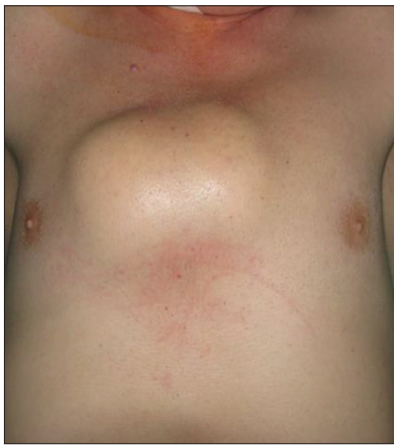

Figure 1. Preoperative view (anterior aspect)

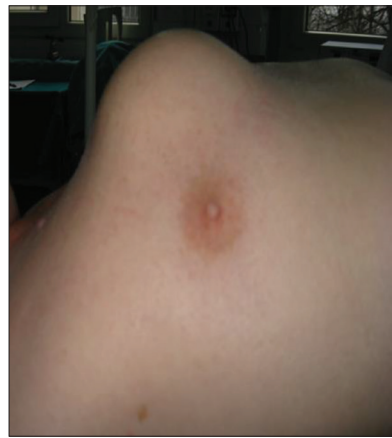

Figure 2. Preoperative view (lateral aspect)

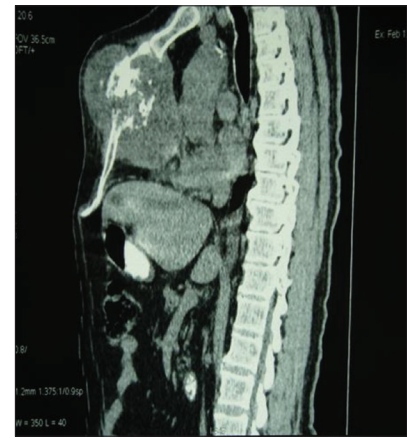

Figure 3. Preoperative chest computed tomography scan (sagittal view)

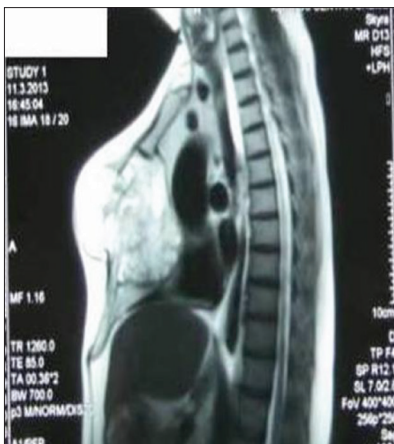

Figure 4. Preoperative chest magnetic resonance imaging scan (sagittal view)

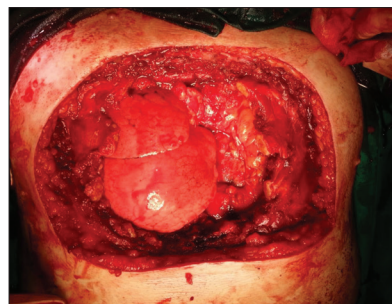


Figure 5. Intraoperative aspect (after resection)

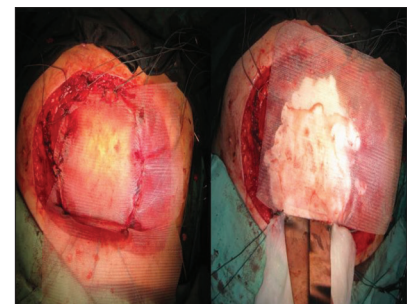


Figure 6. Intraoperative aspect after reconstruction of the anterior chest wall defect with combination of polypropylene mesh and methyl methacrylate bone cement with antibiotics

First, an en bloc resection of the sternum with partial resection of the affected ribs and soft tissues with wide margins was performed. The mediastinal structures were not affected by the tumor. After the wide excision of the tumor, a defect measuring about 24×18 cm remained, with the organs of the chest cavity exposed (Figure 5). The reconstruction was supposed to stabilize the chest and cover the soft tissue defect with vital tissue. Given that at the time of the operation, for technical reasons, the planned 3D model of the sternum and part of the ribs (made on the basis of CT and MRI) was not available to us beforehand, stabilization of the chest was achieved with sandwich technique, with combination of polypropylene mesh and methyl methacrylate bone cement with antibiotics (Figure 6). We reconstructed the soft tissue primary defect with a combination of a large local fasciocutaneous flap raised from the abdomen and a smaller sliding flap from the chest. The secondary defect was reconstructed by wide undermining of the skin in the region of the anterior abdominal wall and a small Thiersch-type free skin graft (Figure 7). In the postoperative period, the flaps were vital, but there was necrosis of the free skin graft, but that defect was closed secondary thanks to bandaging (Figure 8). The sutures were removed on the day 15 after the operation. There was no need for a blood transfusion. Respiratory function was preserved. The resected specimen was sent for histological examination

that confirmed the diagnosis of chondrosarcoma with a free resection margin from the tumor (Figure 9).

All procedures performed in studies involving human participants were in accordance with the ethical standards of the institutional and national research committee and with the 1964 Helsinki declaration and its later amendments and comparable ethical standards.

DISCUSSION

Chondrosarcomas make up about 30% of primary bone cancers, with only 1% of primary bone cancers arising from the sternum. Chondrosarcomas occur most often in the third and fourth decade of life, and are more common in men than in women [2]. In our case, the patient is a male in the seventh decade of life.

In preoperative diagnosis and planning, CT of the chest can be considered the gold standard, providing data on dissemination, lung involvement, the presence of metastases, as well as in the assessment of mediastinal lymph node involvement [4, 5], and also important role in the postoperative follow-up of sternal chondrosarcoma, as well as sarcoma of the other localizations [6]. MRI is used to differentiate between intraosseous and extraosseous involvement, while positron emission tomography (PET) can differentiate benign from a malignant tumor, but the type of tumor cannot be distinguished [2]. Some recent studies

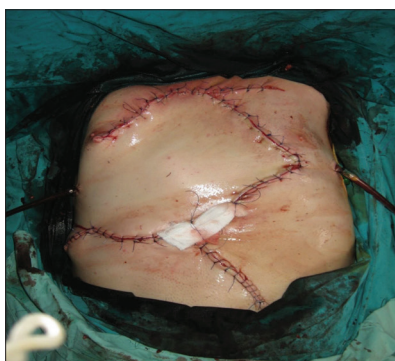

Figure 7. Postoperative aspect after reconstruction

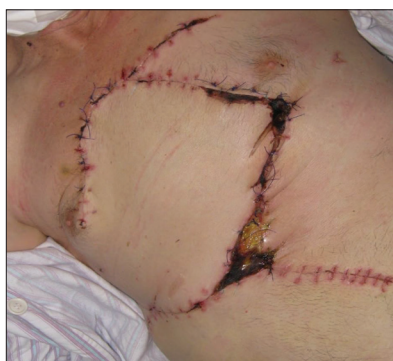

Figure 8. Presentation of necrosis of the free skin graft postoperatively

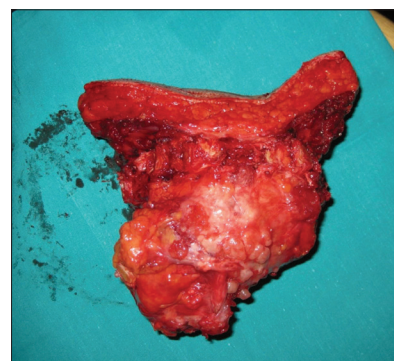


Figure 9. Resected specimen

indicate the need for larger prospective studies to evaluate the possibility of differentiating tumor subtypes based on MRI characteristics [7]. Also, PET can play an important role in the diagnosis of other types of sarcomas [8]. During the diagnostic procedure, we performed CT and MRI of the chest, while PET was not available to us at the time. In the course of preoperative diagnostics, invasive preoperative diagnostics with a surgical needle biopsy of the tumor can be performed, but it can be uncertain in cases where the sternum cortex is not affected [5]. In our case, the tumor biopsy was not performed before the operation because based on previous non-invasive preoperative diagnostic procedures and clinical presentation verified tumor that showed typical features of chondrosarcoma.

Radical resection with wide margins is the standard for treatment, given that the use of radiotherapy and chemotherapy does not provide satisfactory outcomes [9, 10, 11]. A five-year survival ranges between 64% and 92%, with negative predictors for survival being high tumor grade, incomplete (R1) resection, and tumors larger than 10 cm [9]. In the case of resection margins to be achieved, there are various recommendations, whereby margins of 4–6 cm are most often recommended [1, 5, 9], or a negative finding on frozen section, which is considered sufficient without a certain distance [5].

Although sternal chondrosarcomas are rare, if adequate treatment is not started in a timely manner, metastases can occur [12]. Metastases are mostly extrapulmonary [13].

After the resection has been performed and there is a defect in the chest wall, no reconstruction is required for defects smaller than 5 cm [1, 4]. For larger defects, it is necessary to enable the rigidity of the chest wall, obliterate the dead space, preserve lung mechanics, protect the intrathoracic organs, ensure patency with soft tissues, minimize deformities. Several prosthetic reconstruction materials are available, including synthetic, biological, metallic materials, and soft-tissue reconstruction with skin grafts, free flaps, myocutaneous flaps, fasciocutaneous flaps, each of which has its own advantages and disadvantages [14].

The sandwich technique with methyl methacrylate between two layers of polypropylene mesh is widely accepted, because it ensures the rigidity of the chest, which can be modeled according to the shape of the chest wall. It is relatively cheap, while its rigidity enables the stability

of the chest wall and the covering of vital structures, while infection, dislocation and fracture of methyl methacrylate are most often cited as the disadvantages of this method of reconstruction [4]. Lardinois et al. [15] reported on 26 cases of reconstruction using the sandwich technique, in which there were no deaths within 30 days, and postoperative complications were recorded in four patients, while none of the others numerous studies have not noted an increased rate of infection [11, 15, 16, 17]. In a series of cases in 20 patients in which this reconstruction technique was applied, Foroulis et al. [18] reported only one case of a methyl methacrylate fracture that was accidentally discovered during follow-up, on a follow-up chest CT scan after a year and a half of reconstruction, and there was no dislocation or a violation of the chest wall stability.

Reconstruction of soft tissue defects of the chest wall depends on the location and size of the defect, the availability of local and regional options, information on previous surgery, radiotherapy, the general condition of the patient and the prognosis of the disease [4].

The advantage of applying local fasciocutaneous flaps is multiple. They are easy and quick to remove, they are very reliable because they have good vascularization, the fixation of the fascia achieves excellent tensile strength, so the skin closes tightly, they have identical or similar characteristics of the tissue they replace, blood loss is minimal, and after their application, numerous possibilities remain for the following reconstructions, if necessary. The thoracoabdominal flap is a fasciocutaneous rotator flap. They can be based laterally or medially, whereby laterally based flaps preserve the intercostal arteries, while medially based flaps preserve the upper epigastric perforator branches [19].

In conclusion, it is important to note that chondrosarcomas of the sternum, as very rare tumors, which are resistant to chemotherapy and radiotherapy, represent a real challenge for surgical treatment, given that surgical treatment is the main form of treatment for these tumors. Careful preoperative diagnosis, operative approach, as well as adequate reconstruction of defects and soft tissues of the chest wall, enabling good postoperative oncological outcomes with the achievement of chest wall rigidity and satisfactory respiratory status.

Conflict of interest: None declared.

REFERENCES

- Kawana S, Yamamoto H, Maki Y, Sugimoto S, Toyooka S, Miyoshi S. Reconstruction of Anterior Chest Wall with Polypropylene Mesh: Two Primary Sternal Chondrosarcoma Cases. *Acta Med Okayama*. 2017;71(3):259–62. [DOI: 10.18926/AMO/55210] [PMID: 28655947]
- Yousefi Y, Sadrizadeh A, Sadrizadeh S. Huge sternal chondrosarcoma: a case report. *Asian Cardiovasc Thorac Ann*. 2018;26(8):632–4. [DOI: 10.1177/0218492318803813] [PMID: 30269524]
- Pavelescu C, Bebliuc A, Asmarandei R, Safta MS, Zaharia O, Costache VS, et al. Giant Sternal Chondrosarcoma in a 50-Year-Old Patient. *Healthcare (Basel)*. 2022;10(1):158. [DOI: 10.3390/healthcare10010158] [PMID: 35052321]
- Brito ÍM, Teixeira S, Paupério G, Choupina M, Ribeiro M. Giant chondrosarcoma of the chest wall: a rare surgical challenge. *Autops Case Rep*. 2020;10(3):e2020166. [DOI: 10.4322/acr.2020.166] [PMID: 33344295]
- Kozak K, Łochowski MP, Białas A, Rusinek M, Kozak J. Surgical treatment of tumours of the sternum - 10 years' experience. *Kardiochir Torakochirurgia Pol*. 2016;13(3):213–6. [DOI: 10.5114/kitp.2016.62608] [PMID: 27785134]
- Marić N, Nikolić A, Cvijanović V, Ristanović A, Vešović N, Stojković D, et al. Redak slučaj primarnog sinovijalnog sarkoma pleure. *Vojnosanit Pregl*. 2021;78(4):467–70. [DOI: 10.2298/VSP20190110068M]
- Gülçin Bozbeyoğlu S, Toksoz Yildirim AN. Can we distinguish conventional osteosarcoma subtypes (osteoblastic and chondroblastic) based on their magnetic resonance signal intensities? *Srp Arh Celok Lek*. 2023;151(9–10):536–41. [DOI: 10.2298/SARH220920085G]
- Zivgarević L, Žunić S. 18F-fluorodeoksiglukoza pozitronska emisija tomografija - kompjuterizovana tomografija u primarnom sarkomu pluća. *Srp Arh Celok Lek*. 2022;150(9–10):594–7. [DOI: 10.2298/SARH220507069Z]
- Gričiuta Al, Bracken A, Abbas AE, Petrov RV. Complex anterior chest wall reconstruction after extensive oncologic resections: a narrative review. *Shanghai Chest*. 2021;5:41. [DOI: 10.21037/shc-21-8] [PMID: 35495182]
- Abdufatah E, Rottmann D, Morag Y, Pantanowitz L, Udager AM, Hao W, et al. Conventional chondrosarcoma of the rib cage and sternum: clinicopathological and molecular analysis of 27 patients treated at a single institution. *Hum Pathol*. 2023;136:63–74. [DOI: 10.1016/j.humpath.2023.03.011] [PMID: 37019410]
- Lo Iacono G, Mazzella A, Mohamed S, Petrella F, Sedda G, Casiraghi M, et al. The Role of Surgery in Primary Chest Wall Tumors: Over 20 Years' Experience in Resection and Reconstruction. *Cancers (Basel)*. 2023;15(7):2153. [DOI: 10.3390/cancers15072153] [PMID: 37046813]
- Jadhav SS, Dhok AP, Mitra KR, Onkar PM, Phatak SV. Chondrosarcoma of Sternal Origin: A Rare Case. *Cureus*. 2023;15(6):e40393. [DOI: 10.7759/cureus.40393] [PMID: 37456492]
- Jalil RA, Abdallah FA. Multiple local recurrences of primary sternal chondrosarcoma: tumor manipulation or self-seeding. *J Cardiothorac Surg*. 2023;18(1):114. [DOI: 10.1186/s13019-023-02213-5] [PMID: 37031192]
- Sanna S, Brandolini J, Pardolesi A, Argnani D, Mengozzi M, Dell'Amore A, et al. Materials and techniques in chest wall reconstruction: a review. *J Vis Surg*. 2017;3:95. [DOI: 10.21037/jovs.2017.06.10] [PMID: 29078657]
- Lardinois D, Muller M, Furrer M, Banic A, Gugger M, Krueger T, et al. Functional assessment of chest wall integrity after methylmethacrylate reconstruction. *Ann Thorac Surg*. 2000;69(3):919–23. [DOI: 10.1016/S0003-4975(99)01422-8] [PMID: 10750784]
- Fouad FA. Chest wall resection and reconstruction: analysis of 11 cases after methylmethacrylate reconstruction. *J Egypt Natl Canc Inst*. 2006;18(3):175–82. [PMID: 17671526]
- Weyant MJ, Bains MS, Venkatraman E, Downey RJ, Park BJ, Flores RM, et al. Results of chest wall resection and reconstruction with and without rigid prosthesis. *Ann Thorac Surg*. 2006;81(1):279–85. [DOI: 10.1016/j.athoracsur.2005.07.001] [PMID: 16368380]
- Foroulis CN, Kleontas AD, Tagarakis G, Nana C, Alexiou I, Grosomanidis V, et al. Massive chest wall resection and reconstruction for malignant disease. *Onco Targets Ther*. 2016;9:2349–58. [DOI: 10.2147/OTT.S101615] [PMID: 27143930]
- Sakamoto A, Noguchi T, Matsuda S. Thoracoabdominal flap reconstruction after resection of superficial soft-tissue sarcomas in the chest wall. *J Surg Case Rep*. 2021;2021(1):rjaa571. [DOI: 10.1093/jscr/rjaa571] [PMID: 33542811]

Радикална ресекција и реконструкција великог хондросаркома стернума

Жељко Гарабиновић^{1,2}, Милан Савић^{1,2}, Никола Чолић³, Милан Стојичић^{2,4}, Славиша Загорац^{2,5}

¹Универзитетски клинички центар Србије, Клиника за грудну хирургију, Београд, Србија;

²Универзитет у Београду, Медицински факултет, Београд, Србија;

³Универзитетски клинички центар Србије, Центар за радиологију и магнетну резонанцу, Београд, Србија;

⁴Универзитетски клинички центар Србије, Клиника за опекологију, пластичну и реконструктивну хирургију, Београд, Србија;

⁵Универзитетски клинички центар Србије, Клиника за ортопедску хирургију и трауматологију, Београд, Србија

САЖЕТАК

Увод Примарни малигни тумори стернума су ретки, при чему је хондросарком најчешћи примарни малигни тумор грудног коша. Златни стандард у лечењу представља хируршко лечење са широким ресекционим маргинама, при чему се мора обезбедити ригидност грудног коша са заштитом унутрашњих органа уз задовољавајућу плућну функцију.

Приказ болесника Приказујемо случај 67-годишњег болесника код кога је претходним прегледима компјутеризованом томографијом и магнетном резонанцом верификована туморска маса која захвата стернум са припадајућим ребрима, са захватањем меких ткива изнад. Најпре је учињена ресекција стернума са парцијалном ресекцијом припадајућих ребара и меких ткива. Реконструкција и стабилизација зида грудног коша постигнута је са два слоја полипропиленске мрежице и метил-метакрилатног коштаног цемента са антибиотиком. Мекоткивни примарни дефект реконструисали

смо комбинацијом великог локалног фасциокутаног режња одигнутог са предела абдомена и мањег клизајућег режња са грудног коша. Секундарни дефект је реконструисан широким подминирањем коже у пределу предњег трбушног зида и малим слободним кожним трансплантатом типа Тирш. У постоперативном периоду режњеви су били витални, али је дошло до некрозе слободног кожног трансплантата. Тај дефект се затворио секундарно захваљујући превијању. Респираторна функција је била очувана.

Закључак Хируршко лечење је основни вид лечења хондросаркома стернума. Адекватним преоперативним и интраоперативним приступом потребно је омогућити добре постоперативне онколошке исходе уз постизање ригидности грудног коша и задовољавајућег респираторног статуса.

Кључне речи: хондросарком стернума; хируршко лечење; реконструкција