

CASE REPORT / ПРИКАЗ БОЛЕСНИКА

A very rare cutaneous epithelioid hemangioendothelioma in the right auricle in a male adult

Milan Filipović^{1,2}, Tatjana Filipović¹, Nebojša Videnović^{1,2}, Zlatan Elek^{1,3}, Aleksandar Božović^{1,3}¹University of Priština – Kosovska Mitrovica, Faculty of Medicine, Kosovska Mitrovica, Serbia;²Priština Clinical Hospital Center – Gračanica, Gračanica, Serbia;³Kosovska Mitrovica Clinical Hospital Center, Kosovska Mitrovica, Serbia**SUMMARY****Introduction** Epithelioid hemangioendothelioma is an extremely rare tumor of vascular origin, which mainly affects soft tissues and, in rare cases, also affects the skin.**Case outline** A 71-year-old man came for an examination due to a tumor localized on the antihelix of the right ear. A radical excision of the tumor and reconstruction of the defect with a preauricular transposition tunnelized Banner flap was performed.**Conclusion** Epithelial hemangioendothelioma of the skin is an extremely rare, vascular tumor. It is characterized by local aggression, the appearance of local recurrences and metastatic hematogenous and lymphogenic spread. Standard dermoscopic examination of this tumor is not important. The appearance of the tumor itself has no clinical specificity, and most often resembles nodular basal cell carcinoma. An early visit to the doctor and removing the change early are the key to success in treating this tumor. So far, no case has been reported that is localized on the antihelix of the ear. Radical surgical excision is the therapy of choice.**Keywords:** epithelioid hemangioendothelioma; vascular neoplasm; auricle**INTRODUCTION**

Epithelioid hemangioendothelioma (EHE) is a vascular tumor of endothelial cell origin. EHE is extremely rare, with an incidence of 1:1,000,000 [1], and the literature is limited to case reports and several retrospective studies. It most commonly occurs in the lungs, liver, and bones, but can also occur in the skin [2]. EHE was first described by Weiss and Enzinger in 1982 as a soft tissue tumor [3]. Clinically, the neoplasm usually presents as a slightly raised, erythematous, sometimes painful dermal nodule.

According to the World Health Organization classification from 2020, EHE is a tumor that is locally aggressive, with metastatic potential [4]. The rate of local recurrence of EHE is 10–15%, and the level of lymphatic and systemic metastases is 20–30% [5]. Pathohistological analysis is the gold standard for definitive diagnosis, where tumor cells are CD31-, CD34-, FLI-1-, and ERG-positive [1]. The main treatment for local changes is surgical removal. Chemotherapy and radiotherapy have not been shown to be effective due to slow tumor growth [6]. The prognosis of surgically treated local changes is good, with a five-year survival rate of 75.3% [7].

CASE REPORT

This case demonstrates a rare neoplasm which unusually presented as a cutaneous lesion. The

location of the lesion on the ear is a challenging area for the surgeon to reconstruct. Local flaps, preauricular transposition tunnelized flap in this case, provide adequate reconstruction and are cosmetically acceptable. EHE requires aggressive management, given its potential to metastasize to lymph nodes, and it requires continued surveillance after treatment. It is important to consider alternative histological diagnoses in patients presenting with cutaneous lesions and how this affects management and prognosis.

A seventy-one-year-old patient was admitted to the surgery department of the Priština Clinical Hospital Center– Gračanica, due to a tumor localized on the antihelix of the right ear. On physical examination, in the area of the antihelix of the right ear, there was a nodule measuring 0.5 × 0.5 cm, above the level of the skin, with clearly defined edges, firm consistency, immobile in relation to the surface (Figure 1).

The anamnestic patient states that he noticed the change four months before and that it increased rapidly. Upon admission to our institution, the patient was in good general condition, with normal laboratory findings, conscious, oriented, normocardic, eupneic. A radical excision of the tumor was performed under local anesthesia. The reconstruction of the resulting defect was performed using a preauricular transposition flap (Banner flap) tunnelized through a cartilaginous fistula created at the helical crus. The flap was deepithelialized

Received • Примљено:

May 8, 2023

Revised • Ревизија:

November 13, 2023

Accepted • Прихваћено:

November 17, 2023

Online first: November 21, 2023**Correspondence to:**Aleksandar BOŽOVIĆ
University of Priština – Kosovska
Mitrovica
Faculty of Medicine
Department of Surgery
Anri Dinana b.b.
38220 Kosovska Mitrovica, Serbia
aleksandar.bozovic@med.pr.ac.rs

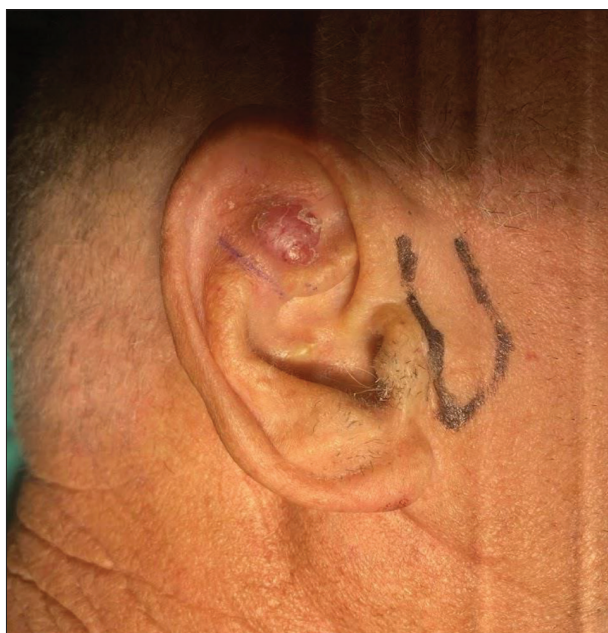

Figure 1. Appearance of the tumor preoperatively

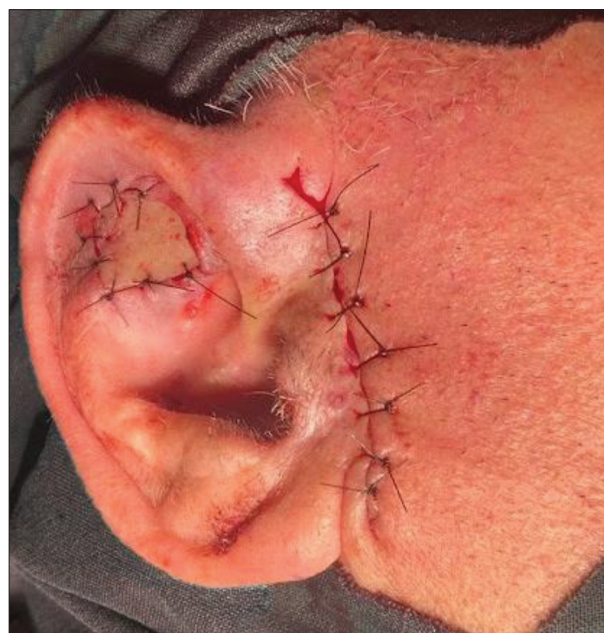

Figure 2. Appearance at the end of the operation

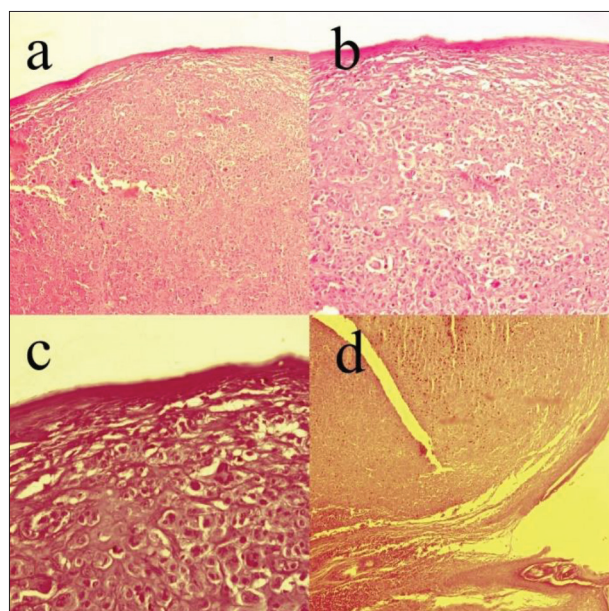


Figure 3. Histopathological findings at different magnifications show: a – 10×0.25 ; b – 10×0.35 ; c – 10×0.40 [non-encapsulated tumor nodule built of epithelioid cells, more abundant eosinophilic cytoplasm, round-oval nucleus with noticeable nucleolus and rare mitoses (2–3 mitoses/mm²), scattered multinuclear cells and small foci of lymphocytic infiltrates, and focal, more pronounced superficial, hyalinized stroma between tumor cells]; and d – 4×0.25 (the ratio of tumor tissue to healthy tissue)

at its base to allow the closure in a single step. The donor site was primarily closed (Figure 2).

In the pathohistology laboratory, pathohistological and immunohistochemical analysis of the tumor change was performed.

Histopathological findings were as follows (Figure 3):

- separated from the epidermis by a narrow free zone, limited, non-encapsulated tumor nodule built of epithelioid cells, more abundant eosinophilic cytoplasm,

round-oval nucleus with noticeable nucleolus and rare mitoses (2–3 mitoses/mm²);

- scattered multinuclear cells and small foci of lymphocytic infiltrates;
- focal, more pronounced superficial, hyalinized stroma between tumor cells.

Immunohistochemical findings were as follows:

- PRAME: + (paler coloring);
- CD34: -;
- BAP1: +;
- ERG: + (Figure 4);
- CD68: - (rare scattered single cells +);
- FLI-1: +;
- CD10: diffuse +;
- Ki-67: about 20%;
- CD31: -;
- maximum tumor thickness: 4.3 mm;
- minimum distance from the resection line in depth: 0.2 mm.

After the early postoperative period, which passed uneventfully, the patient came for regular follow-up check-ups at one, three, six, and 12 months postoperatively (Figure 5).

At each examination, clinical, laboratory, and ultrasound evaluations were performed in order to confirm the occurrence of possible metastatic changes. After a one-year follow-up, which is without clinical manifestations of disease recurrence, we will continue the follow-up in the next four-year period.

All procedures performed in studies involving human participants were in accordance with the ethical standards of the institutional and national research committee and with the 1964 Helsinki declaration and its later amendments or comparable ethical standards. Written consent to publish all shown material was obtained from the patient.

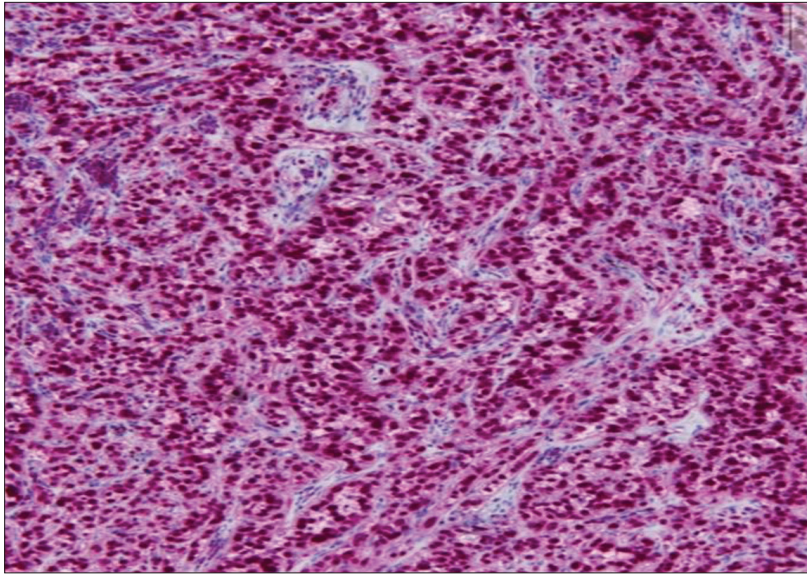


Figure 4. Positive nuclear ERG expression in tumor cells (10 × 0.25)

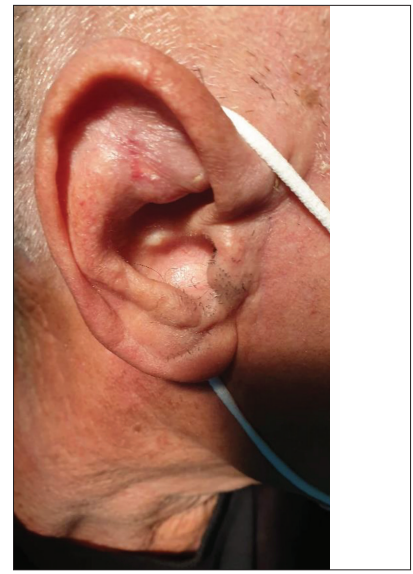


Figure 5. Postoperative appearance after six months

DISCUSSION

Cutaneous EHE is most common in adults, both men and women, but there are several cases where cutaneous EHE has been described in children [8]. According to the World Health Organization, EHE is a malignant tumor with a metastasis incidence of 20–30% and a mortality of 10–20% [4]. Deyrup et al. [9], in 2008, analyzed a series of 49 EHE subjects and concluded that large tumors (> 3 cm in diameter) with high mitotic activity (more than 3 mitoses) have a more aggressive clinical course. In our case, the mitotic activity of the tumor was low, as well as the diameter of the tumor itself, which indicates that it was a tumor with a low risk of local recurrence and systemic metastasis. According to the literature, the clinical findings of EHE vary from dermal or subcutaneous nodules, through non-healing ulcers, to small multiple red papules [10, 11].

Pathohistologically, tumor cells with eosinophilic cytoplasm, organized in hyaline or mucoid stroma, are present in EHE [12]. A large number of endothelial proteins may be useful in the diagnosis of EHE. FLI-1 protein shows greater sensitivity and specificity in the diagnosis of EHE than CD-31 and CD-34. CD-34 is positive in more than 90% of vascular tumors, so this marker has low specificity because it occurs in a large number of soft tissue

tumors [13]. Based on research in 2000, Miettinen et al. [14] showed that the ERG transcription factor is a tumor marker that occurs in 42 of 43 cases of EHE (Figure 6). Based on the analysis of Flucke et al. [15], all 39 of their subjects with EHE tested for ERG were positive, as were all five tested for FLI-1.

EHE is an extremely rare tumor of vascular origin. It is characterized by local aggression, local recurrences and metastatic, hematogenous and lymphogenic spread. Standard dermoscopic examination of this tumor is unimportant. The appearance of the tumor itself has no clinical specificity, and most often resembles nodular basal cell carcinoma. Going to the doctor early and removing the change early are the key to success in treating this tumor. Radical surgical excision is the therapy of choice. There are various surgical procedures described for the reconstruction of the anterior auricle, including local flaps, skin grafts and even healing by secondary intention. The authors consider the tunneled preauricular transposition flap a good option especially when compared to interpolated flaps, since it allows a reconstruction in a single surgical step with decreased morbidity and favorable cosmetic results.

Conflict of interest: None declared.

REFERENCES

1. Stacchiotti S, Miah AB, Frezza AM, Messiou C, Morosi C, Caraceni A, et al. Epithelioid hemangioendothelioma, an ultra-rare cancer: a consensus paper from the community of experts. *ESMO Open*. 2021;6(3):100170. [DOI: 10.1016/j.esmoop.2021.100170] [PMID: 34090171]
2. Mc Collum JK, Al-Rohill R. Cutaneous Vascular Neoplasms of Uncertain Biological Behavior. *Biology (Basel)* 2021;10(11):1160. [DOI: 10.3390/biology10111160] [PMID: 34827153]
3. Chaouki A, Mkhatri A, Ballage A, Zouhair N, Mahtar M. Extensive epithelioid hemangioendothelioma of the maxillary sinus: A case report. *Int J Surg Case Rep*. 2019;58:70–3. [DOI: 10.1016/j.ijscr.2019.04.013] [PMID: 31015076]
4. Sbaraglia M, Bellan E, Dei Tos AP. The 2020 WHO Classification of Soft Tissue Tumours: news and perspectives. *Pathologica*. 2021;113(2):70–84. [DOI: 10.32074/1591-951X-213] [PMID: 33179614]
5. Chen L, Han F, Yang J, Huang B, Liu H. Primary epithelioid hemangioendothelioma of the eyelid: A case report. *Oncol Lett*. 2022;24(5):398. [DOI: 10.3892/ol.2022.13518] [PMID: 36276489]
6. Hickman AD, Bezerra ED, Roden AC, Houdek MT, Barlow JD, Robinson SJ, et al. An unusual case of aggressive malignant spread of epithelioid hemangioendothelioma. *Rare Tumors*. 2021;13:20363613211010858. [DOI: 10.1177/20363613211010858] [PMID: 33959241]
7. Wu X, Li B, Zheng C, Hong T, He X. Clinical characteristics of epithelioid hemangioendothelioma: a single-center retrospective study. *Eur J Med Res*. 2019;24(1):16. [DOI: 10.1186/s40001-019-0375-8] [PMID: 30819247]
8. Bannoura S, Putra J. Primary malignant vascular tumors of the liver in children: Angiosarcoma and epithelioid hemangioendothelioma. *World J Gastrointest Oncol*. 2021;13(4):223–30. [DOI: 10.4251/wjgo.v13.i4.223] [PMID: 33889274]
9. Deyrup AT, Tighiouart M, Montag AG, Weiss SW. Epithelioid hemangioendothelioma of soft tissue: a proposal for risk stratification based on 49 cases. *Am J Surg Pathol*. 2008;32(6):924–7. [DOI: 10.1097/pas.0b013e31815bf8e6] [PMID: 18551749]
10. Senaratne R, Casey MC, Kelly JL. Malignant epithelioid hemangioendothelioma of the ear. *J Surg Case Rep*. 2022;2022(3):rjac062. [DOI: 10.1093/jscr/rjac062] Erratum in: *J Surg Case Rep*. 2022;2022(5):rjac207. [PMID: 35280049]
11. Witte S, Weidema M, Kaal S, Versleijen-Jonkers Y, Flucke U, van der Graaf W, et al. The heterogeneity of Epithelioid Hemangioendothelioma (EHE): A case series and review of the literature with emphasis on treatment options. *Semin Oncol*. 2021;48(2):111–8. [DOI: 10.1053/j.seminoncol.2021.04.002] [PMID: 34176654]
12. Mansfield SA, Williams RF, Iacobas I. Vascular tumors. *Semin Pediatr Surg*. 2020;29(5):150975. [DOI: 10.1016/j.sempedsurg.2020.150975] [PMID: 33069294]
13. Tansir G, Rastogi S, Barwad A, Yadav R, Shamim SA, Dhamija E, et al. Management and outcomes of advanced hemangioendothelioma at a medical oncology clinic in an Indian tertiary care center. *Future Sci OA*. 2023;8(10):FSO827. [DOI: 10.2144/fsoa-2021-0132] [PMID: 36874373]
14. Miettinen M, Wang ZF, Paetau A, Tan SH, Dobi A, Srivastava S, et al. ERG transcription factor as an immunohistochemical marker for vascular endothelial tumors and prostatic carcinoma. *Am J Surg Pathol*. 2011;35(3):432–41. [DOI: 10.1097/PAS.0b013e318206b67b] [PMID: 21317715]
15. Flucke U, Vogels RJ, de Saint Aubain Somerhausen N, Creyten DH, Riedl RG, van Gorp JM, et al. Epithelioid Hemangioendothelioma: clinicopathologic, immunohistochemical, and molecular genetic analysis of 39 cases. *Diagn Pathol*. 2014;9:131. [DOI: 10.1186/1746-1596-9-131] [PMID: 24986479]

Веома редак кожни епителоидни хемангиоендотелиом десне ушне шкољке код одраслог човека

Милан Филиповић^{1,2}, Татјана Филиповић¹, Небојша Виденовић^{1,2}, Златан Елек^{1,3}, Александар Божовић^{1,3}

¹Универзитет у Приштини – Косовска Митровица, Медицински факултет, Косовска Митровица, Србија;

²Клиничко-болнички центар „Приштина“ – Грачаница, Грачаница, Србија;

³Клиничко-болнички центар „Косовска Митровица“, Косовска Митровица, Србија

САЖЕТАК

Увод Епителоидни хемангиоендотелиом је изузетно редак тумор васкуларног порекла, који углавном захвата мека ткива, а у ретким случајевима захвата и кожу.

Приказ болесника Приказан је мушкарац старости 71 годину, који долази на преглед због туморске промене локализоване на антихеликсу десне ушне шкољке. Болеснику је урађена радикална ексцизија тумора и реконструкција транспозиционим тунелизованим Банеровим флапом.

Закључак Епителоидни хемангиоендотелиом коже представља изузетно редак тумор васкуларног порекла. Карактеристике се локалном агресивношћу, појавом локалних

рецидива и метастатским хематогеним и лимфогеним ширењем. Стандардни дермоскопски преглед овог тумора није од значаја. Изглед саме туморске промене клинички нема специфичности и најчешће подсећа на нодуларни базоцелуларни карцином. Рани одлазак код лекара и рано уклањање промене су кључ успеха у лечењу овог тумора. До сада није објављен ниједан случај који је локализован на антихеликсу ушне шкољке. Радикална хируршка ексцизија је терапија избора.

Кључне речи: епителоидни хемангиоендотелиом; васкуларна неоплазма; ушна шкољка