



ORIGINAL ARTICLE / ОРИГИНАЛНИ РАД

The incidence of patients with pseudoexfoliation in two different regions of Serbia

Miroslav Stamenković^{1,2}, Tatjana Šarenac-Vulović^{3,4}, Nenad Petrović^{3,4}, Jovana Srejić^{3,4}, Katarina Čupić^{3,4}, Marko Popović¹, Ivana Todorović¹, Dušan Todorović^{3,4}

¹Zvezdara University Medical Center, Belgrade, Serbia;

²University of Belgrade, Faculty of Special Education and Rehabilitation, Belgrade, Serbia;

³Kragujevac University Clinical Center, Clinic of Ophthalmology, Kragujevac, Serbia;

⁴University of Kragujevac, Faculty of Medical Sciences, Department of Ophthalmology, Serbia

SUMMARY

Introduction/Objective Pseudoexfoliation (PEX) is an age-related systemic disorder, which can affect the whole body, as well as the eye. It is characterized by abnormal production and accumulation of pseudoexfoliative material. When present in the eye, it can cause different difficulties, but most common are PEX glaucoma (XFG) and intraoperative and postoperative complications of cataract surgeries. The aim of this study was to determine an incidence of patients with PEX in two different regions of Serbia.

Methods The study included 7451 patients scheduled for cataract surgery in two regions of Serbia. It was designed as a multicentric, retrospective study with evaluation of the medical records of all patients who underwent cataract surgery. The study evaluated: incidence of PEX syndrome and PEX glaucoma, age, and sex of patients, as well as preoperative antiglaucomatous therapy and intraoperative and postoperative cataract surgery complications.

Results PEX syndrome (XFS) was recorded in 676 patients (407 females and 269 males), while 243 patients had XFG. It represented 3.26% of patients included in the study. Mean age of XFG patients was 78.1 ± 2.1 years with a statistically significant difference ($p < 0.05$) among incidence of XFG in females compared to males. Intraoperative and postoperative complications during cataract surgery were significantly common in patients with PEX ($p < 0.05$)

Conclusion PEX can complicate cataract surgery, while on the other hand XFG is more difficult to treat and control than most other glaucomas. Therefore, patients with PEX require special treatment during follow-up and treatment.

Keywords: pseudoexfoliation syndrome; phacoemulsification; pseudoexfoliation glaucoma

INTRODUCTION

Pseudoexfoliation (PEX) syndrome (XFS) is an age-related systemic disorder [1, 2]. It can be presented in the whole body, as well as in the eye [3]. This disease is characterized by abnormal production and accumulation of pseudoexfoliative material [4].

The prevalence of the PEX among different nations and regions is different [5]. It is also more common after the sixth decade of the life [6]. Some studies suggested the female predomination, but the others suggested that of the male. Certainly, there is no evidence with sex-related inheritance. The highest incidence linked with geographical regions is in Scandinavian countries and Greece (the island of Crete) [7].

Pseudoexfoliative material is made of abnormal fibrotic fiber [8]. Histologically those fibers are very similar to fibrous tissue fibers. According to some earlier examinations, inflammation is the main process in the very beginning of XFS. Due to inflammation and accumulation of PEX material in trabecular meshwork it can cause intraocular pressure (IOP) rise. That condition is known as pseudoexfoliation glaucoma (XFG) [9]. It represents secondary open-angle glaucoma, usually

recorded in older patients. PEX material can be deposited in all parts of the eye, with different consequences [10]. Those consequences are very important for every ophthalmologist. The most important are: XFG and cataract surgery complications (intraoperative and postoperative) [11]. Detailed ophthalmological examination is necessary for every ophthalmological patient, especially elder, to avoid many possible complications. PEXs are the most commonly present at iris pupillary margin (Figure 1) and anterior lens capsule (Figure 2). In the body PEX is accumulated in visceral organs as well as in blood vessels [8].

Cataract surgery is one of the most frequently performed operations in all medicine [12]. The results of cataract surgery are very important for the patient, for the surgeon, and for the surroundings.

The aim of this study was to determine an incidence of patients with PEX in two different regions of Serbia.

METHODS

The study was designed as a multicentric, retrospective study with evaluation of the

Received • Примљено:

December 12, 2023

Accepted • Прихваћено:

February 1, 2024

Online first: February 5, 2024

Correspondence to:

Dušan TODOROVIĆ

Kragujevac University Clinical

Center

Clinic of Ophthalmology

Zmaj Jovina 30

34000 Kragujevac

Serbia

drdusantodorovic@yahoo.com

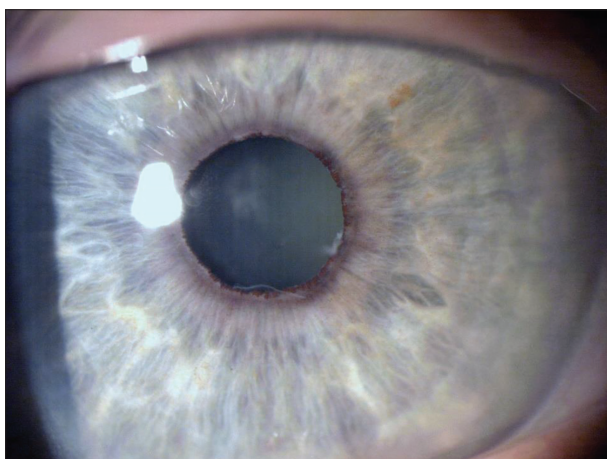


Figure 1. Pseudoexfoliations at the iris pupillary margin and anterior lens capsule

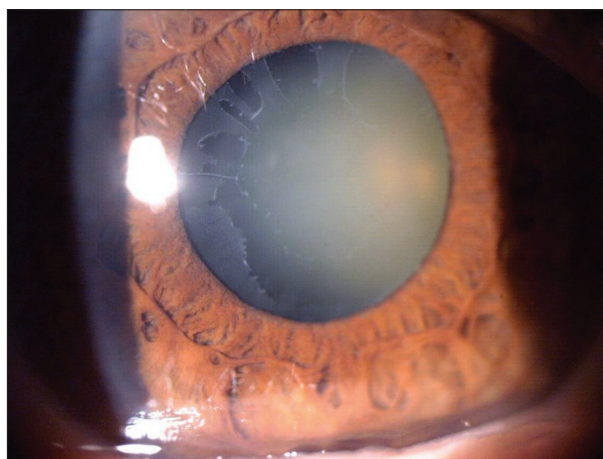


Figure 2. Pseudoexfoliations at the anterior lens capsule

medical records of all patients who underwent cataract surgery. It was conducted at the Clinic of Ophthalmology, Zvezdara University Medical Center and the Clinic of Ophthalmology, Kragujevac University Clinical Center. It included 7451 patients scheduled for cataract surgery. The study period was from November 2021 to November 2023. The written informed consent was obtained from all participants, and the study protocol was approved by the Ethics Committee of the Kragujevac University Clinical Center, prior to the onset of the study. The investigation was conducted in accordance with the principles outlined in the Declaration of Helsinki and the principles of Good Clinical Practice.

The authors evaluated: incidence of PEX syndrome and PEX glaucoma, age, and sex of patients, as well as preoperative antiglaucomatous therapy and intraoperative and postoperative cataract surgery complications. The main inclusion criterion was the presence of cataract, and with no exclusion criterions.

In the preoperative preparation of patients, the presence of ocular and systemic comorbidities, antiglaucoma drugs was analyzed through the detailed review of the medical documentation. A detailed ophthalmological examination was performed for every participant before and after the cataract surgery. It included: the best corrected visual acuity, IOP measurements using Goldmann tonometry, slit lamp examination in mydriasis, indirect ophthalmoscopy. Intraocular lens (IOL) power for every patient was calculated by using SRK/T formula and by using ocular ultrasound A and B scan (Compact touch, Lumibird Medical, Cedex, Lannion, France). The same IOL companies were used in the both Clinics. The XFG was diagnosed if the IOP was above 21 mmHg, characteristic glaucoma damage of optic nerve head and visual field defects were present, as well as PEX material noticed at iris pupillary margin and/or lens anterior capsule during slit lamp examination.

The phacoemulsification was performed for all patients with the same phacoemulsification machine (Stellaris, Bausch and Lomb, Laval, Canada). The cataract surgery was done under the topical anesthesia. After performing paracentesis and central corneal incision, cohesive

viscoelastic was injected in anterior chamber (AC). Then continuous capsulorhexis, hydrodissection and nucleus rotation followed. The nucleus was cracked using “stop and chop” technique and the remaining cortex was aspirated using bimanual irrigation and aspiration. After fulfilling AC and capsular bag with cohesive viscoelastic IOL was injected. The remaining viscoelastic was aspirated and intracameral solution of cefuroxime (1 mg / 0.1 ml balanced salt solution) was injected in AC. In the indicated cases, the procedure was supplemented by preventive or therapeutic implantation of the capsular tension ring. Combined eyedrops of dexamethasone and tobramycin (Tobradex®, Alcon, Vernier-Geneva, Switzerland) were prescribed to all patients, in the same way. From the first postoperative day, patients were also applied a local non-steroidal anti-inflammatory drug (Nevanac®, Alcon, Vernier-Geneva, Switzerland) in the operated eye for prophylaxis of cystoid macular oedema. The patient was then followed up by an external ophthalmologist. The presence of any intraoperative and postoperative complications was recorded.

IBM SPSS Statistics for Windows, Version 22.0. (IBM Corp., Armonk, NY, USA) was used for statistical analysis. According to the normality of distribution, paired t-test, χ^2 , Mann–Whitney test was used in analysis of the incidence of XFS, XFG, comorbidities, number of antiglaucomatous drugs, intra and postoperative complications, as well as patients' age and sex. Values $p < 0.05$ and $p < 0.001$ were considered to be statistically significant.

RESULTS

The mean patients' age was 71.4 ± 2.3 years (median 72, range 53–91 years). According to the age of patients, most of them were in a range from 61 to 80 years old (5301 patients) (Figure 3). In total, 3558 males and 3883 females participated in the study. No statistical significance was noticed between the sexes ($p < 0.05$).

XFS was recorded in 676 patients. It represents 9.07% of all the patients who participated in the study. Among them, 407 were females and 269 were males (Figure 4).

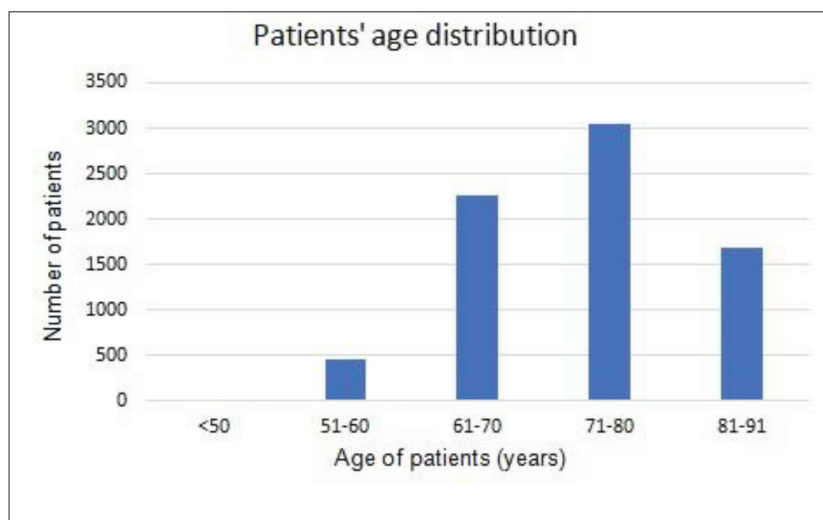


Figure 3. Patients' age distribution

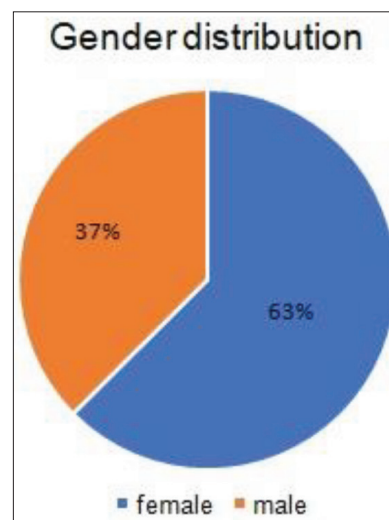


Figure 4. Patients' sex distribution

Table 1. The incidence of intraoperative complications

Intraoperative complications	PEX patients number (%)	NO PEX patients number (%)	Significance
Poor mydriasis	122 (18.04)	655 (9.66)	$p = 0.023^*$
Posterior capsule rupture	55 (8.13)	181 (2.67)	$p = 0.017^*$
Zonular dehiscence	71 (10.5)	273 (4.02)	$p = 0.014^*$
Capsular tension ring implantation	23 (3.4)	171 (2.52)	$p = 0.003^*$
Intraoperative miosis	103 (15.23)	195 (2.87)	$p = 0.001^*$

*Statistically significant
PEX – pseudoexfoliation

Table 2. The incidence of postoperative complications

Postoperative complications	PEX patients number (%)	NO PEX patients number (%)	Significance
Corneal edema	116 (17.15)	652 (9.62)	$p = 0.037^*$
Intraocular lense decentration	52 (7.69)	344 (5.07)	$p = 0.055$
Anterior chamber inflammation	118 (17.45)	477 (7.04)	$p = 0.017^*$
Retinal detachment	21 (3.10)	269 (3.97)	$p = 0.068$
Cystoid macular edema	43 (6.36)	143 (2.11)	$p = 0.009^*$

*Statistically significant
PEX – pseudoexfoliation

Statistically significant difference was measured between sexes in XFS patients ($p < 0.001$). The mean age of XFS patients was 77.5 ± 3.4 years (median 74, range 58–90 years).

We recorded 243 patients with XFG, which represents 3.26% of patients who were included in the study. Mean age of XFG patients was 78.1 ± 2.1 years (median 73, range 53–88 years). There was a statistically significant difference ($p < 0.05$) among incidence of XFG in females ($n = 157$) compared to males ($n = 86$). The mean number of the used antiglaucomatous drugs in XFG patients was 2.2 ± 0.7 . No statistical significance was measured in the number of used antiglaucomatous drugs depending on patients' sex ($p > 0.05$). From these 243 XFG patients, 219 managed to successfully treat glaucoma using antiglaucomatous drugs, while argon laser trabeculoplasty (ALTP) was performed in

19 and trabeculectomy in five patients during the study.

Intraoperative complications including poor mydriasis (less than 5 mm), posterior capsule rupture, zonular dehiscence, capsular tension ring implantation were significantly more often presented in PEX patients (Table 1). Postoperative complications also occurred more commonly in patients with PEXs (Table 2).

DISCUSSION

Senile cataract is the blurring of the lens after the age of 65 [13]. Its development can be in relation to different conditions in the eye, and in the body, as well. Our results also indicate that older people are in positive correlation with cataract incidence, with no statistical significance with sex predomination.

Cataract surgery is the only effective way of its treatment [13]. Phacoemulsification is the most performed method for cataract surgery [14]. Ultrasound energy is used to emulsify and aspirate the crystalline lens in the eye through the small corneal incision. For good results some precursors must be fulfilled: dilated pupils, stability of the iridolental diaphragm, manual dexterity, and the experience of the surgeon [15].

Our study established that PEX presentation in our group of patients was 9.07%. This result is similar as in the other studies [16, 17], where incidence in studies ranges from 4% to 10%. We must notice that it is not same if the incidence is 4% or 10%, because for surgeon it is very important to be beware during and after surgery if PEX material is presented in the eye. According to our results, older female patients were more common. This result is in accordance with the earlier studies [10, 18]. It was also very important to notice that mean age of patients with PEX was higher in comparison to patients without PEX. According

to these findings, some suggestions to ophthalmologists are to pay attention to older female patients, recruited for cataract surgery.

Dilated pupils can be reached, using combined installation of mydriatic eye drops: tropicamide, phenylephrine, or homatropine. In some cases, it is demanded to prescribe the use of non-steroidal anti-inflammatory drug eyedrops preoperative to reach and maintain dilated pupils [19]. Patients with uveitic, diabetic, or traumatic cataract, patients with PEX deposits or patients which are using tamulosin is very difficult to reach good dilated pupils [20]. In that case, cataract surgery becomes very complicated, and needs an experienced surgeon or the use of some intraoperative devices to get dilated pupils (ring) [21].

Stability of the iridolental diaphragm is also very important because of the zonula's weakness, which provokes very serious complications during and after the phacoemulsification surgery [22]. This condition is very often related to PEX deposits in the eye. PEX deposits in the eye predict harder nuclear form of the cataract. Dense and hard cataracts are related to a greater number of intraoperative complications [23]. An increased incidence of PEX patients in our study could be the consequence of increased referral of these patients from private to state clinics, due to higher complications rate during cataract surgery.

Based on the facts above, PEX presentation in the eye is very important for every phacoemulsification surgeon. In order to avoid difficult intra and postoperative complications, detailed clinical examination of every eye of patients must be performed [12].

Earlier investigations suggested that some PEX deposits were not recorded because of the poor dilated pupils [24]. During the surgery, PEX can be detected using the capsular stain.

In the literature, complications of cataract surgery in PEX patients are more common than in patients without PEX. The most common intraoperative complications of the phacoemulsification surgery in patients with PEX are: posterior capsule rupture, vitreous body loss, zonula dehiscence, intraoperative miosis; postoperative complications are: cystoid macular edema, nuclear fragment dislocation, posterior lens capsule opacification, corneal edema, retinal detachment, AC inflammation and hyphema, as well as IOL decentration [25].

Our study established that older patients had more frequent PEX. It seems to be in correlation with earlier epidemiological non-experimental studies. Oxidative stress which is increased in older age is the main cause of PEX production [26]. It induces inflammation and initiates the production of fibrous tissue [9, 27]. Increased production and accumulation of some abnormal fibrous fibers in the anterior segment of the eye result as PEX deposits in the all parts of the eye [4]. PEX material deposits in the iridocorneal angle, and in the retinal vessels, which make conditions to provoke XFG development [3]. According to our findings, approximately 3% of our patients had XFG. Considering that this type of glaucoma is very hard to treat and control, and that it has advanced damage of the retinal nerve fiber layer we have to pay more attention to making

the decision for the cataract surgery. Some earlier studies suggested that IOP can be reduced after phacoemulsification surgery in patients with XFG [28]. Personalized, patient and detailed approach to every patient with PEX is demanded.

Every patient, which comes for cataract surgery, must be undergo a detailed ophthalmological examination, to determine PEX presence in anterior segment of the eye. That finding will help the surgeon to make good choice and strategy for future surgery.

Pseudoexfoliative material is one of the risk factors for XFG. XFG treatment demands highly intensive antiglaucomatous therapeutic approach, because of its unpredictable course of the disease. Using antiglaucomatous drugs with preservative provokes ocular surface changes, and can have impact on the IOL calculation, as well as on corneal clearness during the surgery [29]. Also, PEX material in lamina cribrosa of the optic nerve head and in the retinal vessels make good predisposition for the glaucoma disease progression. Phacoemulsification surgery must be done very carefully without fast IOP oscillations. On the other hand, it is helpful to know that IOP can be decreased and well controlled after phacoemulsification surgery, up to a year after the surgery. PEX material is associated with a decreased number of corneal endothelial cells which increase the risk for development of postoperative corneal edema [30]. So, it is very important to use as less as possible ultrasound energy during phacoemulsification as well as to inject dispersive viscoelastic in AC to protect corneal endothelial layer. Also, surgeon would have to consider the possibility to do phacoemulsification surgery in earlier stages of the cataract development, because of the lower ultrasound energy for lens emulsification.

Every surgery has complications. Phacoemulsification surgery complications are divided into: intraoperative and postoperative [25]. Our results indicated that intraoperative complications were statistically significantly increased compared to patients without PEX. Surgery plan, good technique and some devices must be well considered before the surgery.

Postoperative complications are in relation with PEX presentation, and in surgery process. Inflammation was more commonly described in patients with PEX in comparison to with patients without PEX (PEX pathophysiology) [9]. Good manipulation during surgery and preoperative preparation for it are very important in order to avoid inflammation of the eye.

Postoperative capsular opacification was statistically significant more commonly in patients with PEX in comparison to patients without PEX. Some studies also noticed that capsular opacification is more common in patients with PEX because those patients are more susceptible to inflammable postoperative and fibrous reactions [24].

CONCLUSION

Phacoemulsification has improved cataract surgery in all aspects, but still, this technique is not without risks.

Patients with PEX had more frequent occurrence of intraoperative and postoperative complications which can disrupt the final outcome of the surgery and patient's satisfaction. XFG is difficult to control and treat. All these

facts indicate that PEX patients require special attention and additional caution during treatment.

Conflict of interest: None declared.

REFERENCES

- Elhawry E, Kamthan G, Dong CQ, Danias J. Pseudoexfoliation syndrome, a systemic disorder with ocular manifestations. *Hum Genomics*. 2012;6(1):22. [DOI: 10.1186/1479-7364-6-22] [PMID: 23157966]
- Wang W, He M, Zhou M, Zhang X. Ocular pseudoexfoliation syndrome and vascular disease: a systematic review and meta-analysis. *PLoS One*. 2014;9(3):e92767. [DOI: 10.1371/journal.pone.0092767] [PMID: 24667689]
- Schlötzer-Schrehardt U. New pathogenetic insights into pseudoexfoliation syndrome/glaucoma. Therapeutically relevant?. *Ophthalmologe*. 2012;109(10):944–51. [DOI: 10.1007/s00347-012-2531-1] [PMID: 23053330]
- Schlötzer-Schrehardt U, Naumann GO. Ocular and systemic pseudoexfoliation syndrome. *Am J Ophthalmol*. 2006;141(5):921–37. [DOI: 10.1016/j.ajo.2006.01.047] [PMID: 16678509]
- Melese EK, Shibeshi MA, Sherief ST. Prevalence of Pseudoexfoliation Among Adults and Its Related Ophthalmic Variables in Southern Ethiopia: A Cross-Sectional Study. *Clin Ophthalmol*. 2022;16:3951–8. [DOI: 10.2147/OPHTH.S391290] [PMID: 36471727]
- Schweitzer C. Pseudoexfoliation syndrome and pseudoexfoliation glaucoma. *J Fr Ophtalmol*. 2018;41(1):78–90. [DOI: 10.1016/j.jfo.2017.09.003] [PMID: 29329947]
- Kozobolis VP, Papatzanaki M, Vlachonikolis IG, Pallikaris IG, Tsambarlakos IG. Epidemiology of pseudoexfoliation in the island of Crete (Greece). *Acta Ophthalmol Scand*. 1997;75(6):726–9. [DOI: 10.1111/j.1600-0420.1997.tb00640.x] [PMID: 9527341]
- Buffault J, Labbé A, Hamard P, Brignole-Baudouin F, Baudouin C. The trabecular meshwork: Structure, function and clinical implications. A review of the literature. *J Fr Ophtalmol*. 2020;43(7):e217–30. [DOI: 10.1016/j.jfo.2020.05.002] [PMID: 32561029]
- Sarenac Vulovic TS, Pavlovic SM, Zdravkovic NS. Proinflammatory Cytokines Induce XFG Development. *Ocul Immunol Inflamm*. 2016;24(6):671–7. [DOI: 10.3109/09273948.2015.1063672] [PMID: 26651123]
- Rumelaitiene U, Speckauskas M, Tamosiunas A, Radisauskas R, Peto T, Larsen MB, et al. Exploring association between pseudoexfoliation syndrome and ocular aging. *Int Ophthalmol*. 2023;43(3):847–57. [DOI: 10.1007/s10792-022-02486-0] [PMID: 36127504]
- Faschinger C. Pseudoexfoliation glaucoma in pseudophakic eyes: still a therapeutic challenge. *Graefes Arch Clin Exp Ophthalmol*. 2023;261(12):3345–6. [DOI: 10.1007/s00417-023-06234-7] [PMID: 37704760]
- Goel R, Shah S, Malik KPS, Sontakke R, Golhait P, Gaonker T. Complications of manual small-incision cataract surgery. *Indian J Ophthalmol*. 2022;70(11):3803–11. [DOI: 10.4103/ijo.IJO_1812_22] [PMID: 36308100]
- Rewri P, Lohan A, Aggarwal S, Chodhary P, Singhal A. Cataract surgical reach: Falling short to catch white cataracts! *Indian J Ophthalmol*. 2021;69(6):1575–8. [DOI: 10.4103/ijo.IJO_2560_20] [PMID: 34011744]
- Boulter T, Bernhisel A, Mamalis C, Zaugg B, Barlow WR, Olson RJ, et al. Phacoemulsification in review: Optimization of cataract removal in an in vitro setting. *Surv Ophthalmol*. 2019;64(6):868–75. [DOI: 10.1016/j.survophthal.2019.06.007] [PMID: 31276738]
- Akpolat C, Demir M, Cevher S, Ozturk SZ, Yesiltas S. The impact of phacoemulsification surgery on vision-related quality of life in senile cataract patients. *Ther Adv Ophthalmol*. 2022;14:25158414211063293. [DOI: 10.1177/25158414211063293] [PMID: 35083419]
- Ekström C, Winblad von Walter L. Incidence and baseline risk factors for pseudoexfoliation in Sweden: a long-term follow-up study. *Acta Ophthalmol*. 2020;98(3):310–4. [DOI: 10.1111/aos.14254] [PMID: 31573742]
- Karger RA, Jeng SM, Johnson DH, Hodge DO, Good MS. Estimated incidence of pseudoexfoliation syndrome and pseudoexfoliation glaucoma in Olmsted County, Minnesota. *J Glaucoma*. 2003;12(3):193–7. [DOI: 10.1097/00061198-200306000-00002] [PMID: 12782834]
- Aström S, Lindén C. Incidence and prevalence of pseudoexfoliation and open-angle glaucoma in northern Sweden: I. Baseline report. *Acta Ophthalmol Scand*. 2007;85(8):828–31. [DOI: 10.1111/j.1600-0420.2007.00992.x] [PMID: 17986290]
- Schulz CB, Goverdhan SV, Humphry RC. An evaluation of intracameral mydriasis for routine cataract surgery. *Br J Ophthalmol*. 2018;102(6):784–9. [DOI: 10.1136/bjophthalmol-2017-310510] [PMID: 28903962]
- Kwak J, Han JY, Moon SY, Nam S, Kim JY, Tchah H, et al. Relationship Between Tamsulosin Use and Surgical Complications of Cataract Surgery in Elderly Patients: Population-Based Cohort Study. *Front Med (Lausanne)*. 2022;9:882131. [DOI: 10.3389/fmed.2022.882131] [PMID: 35665322]
- Oudjani N, Renault D, Courrier E, Malek Y. Phacoemulsification And Zonular Weakness: Contribution Of The Capsular Tension Ring With A Thread. *Clin Ophthalmol*. 2019;13:2301–4. [DOI: 10.2147/OPHTH.S212063] [PMID: 31849440]
- Venkateswaran N, Henderson BA. Loose zonules in cataract surgery. *Curr Opin Ophthalmol*. 2022;33(1):53–7. [DOI: 10.1097/ICU.0000000000000826] [PMID: 34783703]
- Foster GJ, Allen QB, Ayres BD, Devgan U, Hoffman RS, Khandelwal SS, et al. Phacoemulsification of the rock-hard dense nuclear cataract: Options and recommendations. *J Cataract Refract Surg*. 2018;44(7):905–16. [DOI: 10.1016/j.jcrs.2018.03.038] [PMID: 29960655]
- Sternfeld A, Luski M, Sella R, Zahavi A, Geffen N, Pereg A, et al. Diagnosis of Pseudoexfoliation Syndrome in Pseudophakic Patients. *Ophthalmic Res*. 2021;64(1):28–33. [DOI: 10.1159/000508336] [PMID: 32353850]
- Sarenac Vulovic T, Todorovic D, Petrovic N, Jovanovic S. The complication of cataract surgery in apertins with pseudoexfoliation. *Experimental and Applied Biomedical Research*. 2020. [DOI: 10.2478/sjcr-2020-0044]
- Sarenac Vulovic TS, Pavlovic SM, Jakovljevic VL, Janicijevic KB, Zdravkovic NS. Nitric oxide and tumour necrosis factor alpha in the process of pseudoexfoliation glaucoma. *Int J Ophthalmol*. 2016;9(8):1138–42. [DOI: 10.18240/ijo.2016.08.09] [PMID: 27588268]
- Sarenac Vulovic T, Pavlovic S, Lutovac M, Zdravkovic V, Sreckovic S, Zdravkovic N. Regulatory cytokines prescribe the outcome of the inflammation in the process of pseudoexfoliation production. *J Chin Med Assoc*. 2019;82(12):935–40. [DOI: 10.1097/JCMA.0000000000000214] [PMID: 31800535]
- Todorović M, Šarenac Vulović T, Petrović N, Todorović D, Srećković S. Intraocular pressure changes after uneventful phacoemulsification in early postoperative period in healthy eyes. *Acta Clin Croat*. 2019;58(3):467–72. [DOI: 10.20471/acc.2019.58.03.10] [PMID: 31969759]
- Saeedi O, Chen V. BAK to the Future? Preserved and Preservative-Free Topical Glaucoma Medications. *Eye Contact Lens*. 2022;48(4):139–40. [DOI: 10.1097/ICL.0000000000000893] [PMID: 35296624]
- Todorović D, Šarenac-Vulović T, Petrović N, Jovanović S, Janićijević-Petrović M, Đoković D, et al. The effect of intraocular lens material and postoperative therapy on the posterior capsule opacification development after the senile cataract surgery. *Srp Arh Celok Lek*. 2020;148(5–6):333–7. [DOI: 10.2298/SARH18121118T]

Инциденца пацијената са псеудоексфолијацијама у два различита региона Србије

Мирослав Стаменковић^{1,2}, Татјана Шаренац-Вуловић^{3,4}, Ненад Петровић^{3,4}, Јована Срејовић^{3,4}, Катарина Ђупић^{3,4}, Марко Поповић¹, Ивана Тодоровић¹, Душан Тодоровић^{3,4}

¹Универзитетски клиничко-болнички центар „Звездара“, Београд, Србија;

²Универзитет у Београду, Факултет за специјалну едукацију и рехабилитацију, Београд, Србија;

³Универзитетски клинички центар „Крагујевац“, Клиника за офталмологију, Крагујевац, Србија;

⁴Универзитет у Крагујевцу, Факултет медицинских наука, Катедра за офталмологију, Србија

САЖЕТАК

Увод/Циљ Псеудоексфолијације су системски поремећај повезан са годинама, који може утицати на цело тело, али и око. Карактерише га абнормална производња и акумулација псеудоексфолијативног материјала. Када је присутан у оку, може изазвати различите потешкоће, али најчешће су псеудоексфолијациони глауком и интраоперативне и постоперативне компликације операција катаракте.

Циљ овог истраживања био је да се утврди учесталост оболелих од псеудоексфолијације у два различита региона Србије.

Метод Студија је обухватила 7451 пацијента заказаног за операцију катаракте у два региона Србије. Замишљена је као мултицентрична, ретроспективна студија са евалуацијом медицинске документације свих пацијената који су били подвргнути операцији катаракте. Студија је проценила учесталост псеудоексфолијативног синдрома и псеудоексфолијативног глаукома, старост и пол пацијената, као и преоперативну антиглаукоматозну терапију и

компликације интраоперативне и постоперативне операције катаракте.

Резултати Псеудоексфолијативни синдром забележен је код 676 пацијената (407 жена и 269 мушкараца), док су 243 болесника имала псеудоексфолијативни глауком. Обухватио је 3,26% пацијената укључених у студију. Просечна старост пацијената са псеудоексфолијативним глаукомом била је $78,1 \pm 2,1$ година са статистички значајном разликом ($p < 0,05$) између инциденције код жена у односу на мушкарце. Интраоперативне и постоперативне компликације током операције катаракте биле су значајно честе код пацијената са псеудоексфолијацијама ($p < 0,05$).

Закључак Псеудоексфолијације могу да закомпликују операцију катаракте, док је с друге стране псеудоексфолијативни глауком тежи за лечење и контролу од већине других глаукома. Због тога пацијенти са псеудоексфолијацијама захтевају посебан третман током праћења и лечења.

Кључне речи: псеудоексфолијативни синдром; факоемулзификација; псеудоексфолијативни глауком