

ORIGINAL ARTICLE / ОРИГИНАЛНИ РАД

Total knee arthroplasty in patients with a proximal tibial stress fracture associated with bilateral severe knee osteoarthritis

Slavko Manojlović^{1,2}, Rajko Dodik¹, Mirko Manojlović¹, Željko Jovičić³,
Dragana Dragičević-Cvjetković^{4,5}

¹Gradiška General Hospital, Department of Surgery, Gradiška, Republic of Srpska, Bosnia and Herzegovina;

²University of Banja Luka, Faculty of Medicine, Department of Surgery, Banja Luka, Republic of Srpska, Bosnia and Herzegovina;

³Dr Miroslav Zotović Institute of Physical Medicine and Rehabilitation, Department of Orthopedic Surgery, Banja Luka, Republic of Srpska, Bosnia and Herzegovina;

⁴Dr Miroslav Zotović Institute of Physical Medicine and Rehabilitation, Department of Rehabilitation and Balneology, Banja Luka, Republic of Srpska, Bosnia and Herzegovina;

⁵University of Banja Luka, Faculty of Medicine, Department of Physical Medicine and Rehabilitation, Banja Luka, Republic of Srpska, Bosnia and Herzegovina



SUMMARY

Introduction/Objective Proximal tibial stress fractures associated with bilateral severe knee osteoarthritis are rare and, due to possible consequences, are considered a treatment challenge. This paper aims to present the applied treatment method of these patients and its results.

Methods A prospective study followed 14 patients with an average age of 74.1 years and with unilateral proximal tibial stress fracture associated with bilateral severe knee osteoarthritis. Surgical treatment involved modular total knee arthroplasty (TKA) on the fracture side, in the first act, and contralateral standard TKA, in the second act, based on the severe osteoarthritis. Rehabilitation was performed for 21 days after both operations and included the following: kinesiotherapy, electrotherapy, magnetotherapy, hydrotherapy, and thermotherapy. Monitoring parameters were as follows: X-ray, range of motion, and WOMAC index. Monitoring periods were preoperative and three, six, and nine months after the first TKA surgery.

Results The radiological findings in all patients during these follow-up periods were normal. All tibial stress fractures healed within six months after surgery. Knee function was significantly improved nine months after the first TKA surgery compared to the preoperative finding. A statistically significant improvement in the physical functioning was found in all postoperative periods, especially nine months after the first TKA surgery ($p < 0.05$).

Conclusion Modular total knee arthroplasty on the tibial stress fracture side and delayed standard total knee arthroplasty of contralateral osteoarthritic knee combined by postoperative inpatient rehabilitation give optimal final functional outcome.

Keywords: tibia; fracture; stress; knee; osteoarthritis; arthroplasty

INTRODUCTION

Stress fractures of the proximal tibia often occur as a result of the gravity loads on the osteoporotic bone. They can be related to other conditions and diseases (inflammatory rheumatism, malignancies, metabolic bone diseases), but they are most common in bilateral advanced knee osteoarthritis with marked varus deformity. In patients with such bilateral knee osteoarthritis, a stress fracture is caused by normal stresses placed on an abnormal bone [1]. This poor biomechanical condition leads to a fracture in the proximal part of tibia at the site of the new resultant force [2, 3]. Such cases are rare, but possible consequences make its treatment a challenge [4, 5]. It is most often performed by bilateral total knee arthroplasty (TKA) on both sides, in two phases. The first phase involves the TKA with a modular tibial stem on the knee

with the fracture, and the second phase is performed by a standard TKA on the contralateral knee (usually three months after the first TKA and after the rehabilitation is being finished) [6]. After both surgeries, additional inpatient physical therapy is being performed. The object of this paper is to present the algorithm and the results of the treatment on a series of patients with unilateral stress proximal tibial fracture and bilateral primary knee osteoarthritis in a manner as described above.

METHODS

In the period from 2005 to 2017, 14 patients with a unilateral proximal tibial stress fracture, associated with bilateral primary knee osteoarthritis grade 4 according to the Kellgren–Lawrence classification, were surgically treated at the

Received • Примљено:

October 22, 2022

Revised • Ревизија:

December 10, 2023

Accepted • Прихваћено:

December 18, 2023

Online first: December 26, 2023

Correspondence to:

Slavko MANOJLOVIĆ
University of Banja Luka
Faculty of Medicine
Department of Surgery
Save Mrkalja 14
Banja Luka 78 000
The Republic of Srpska
Bosnia and Herzegovina
slavko.manojlovic@gmail.com

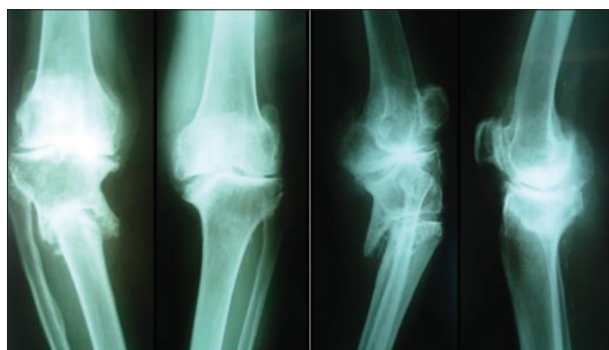

Figure 1. X-rays of both knees in a patient with a proximal metaphysis stress fracture of the right tibia, associated with severe bilateral knee osteoarthritis

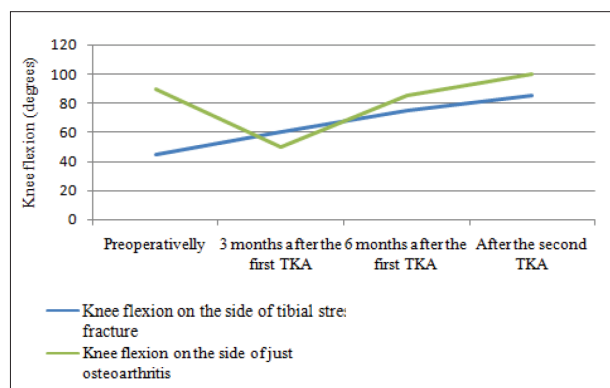


Figure 3. Improvements of average knee flexion in both knees; TKA – total knee arthroplasty

Gradiška General Hospital (Figure 1). These were also the inclusive criteria. Excluding criteria were the following: inflammatory and metabolic rheumatic disease, trauma, and previous surgery on the same leg. The treatment of choice was TKA with modular tibial stem on the fractured knee, in the first act, and standard TKA on the other knee, in the second act, for all patients. After standard preoperative preparation, the surgeries were performed under spinal anesthesia in all cases. A tourniquet was used each time. Standard mid-vastus approach was applied. Thromboprophylaxis was performed in all the patients one day preoperatively and during 21 days postoperatively. Walking with forearm crutches was allowed after the surgery, with partial support up to the pain limit. All the patients had two postoperative rehabilitation periods of 21 days each – after the first and after the second surgery. Both inpatient rehabilitation treatments were performed one month after each TKA. The rehabilitation had included kinesitherapy, occupational therapy, electrotherapy five times a week, and daily hydrotherapy. Monitoring parameters were X-rays, range of motion (knee flexion), and the Western Ontario and McMaster Universities Arthritis Index (WOMAC) index preoperatively, and three, six, and nine months after the first surgery. Statistical analysis was performed by Student's t-test for $p < 0.05$ level of significance, using IBM SPSS Statistics, Version 19.0 (IBM Corp., Armonk, NY, USA). The study has been approved by the Ethics Committee of the Gradiška General Hospital (Reference Number 01-1758-3/20).

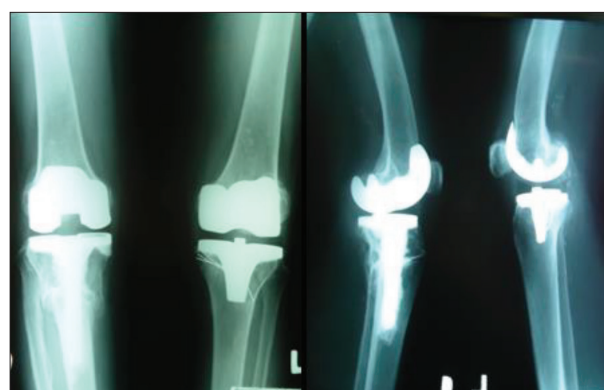

Figure 2. X-rays of both knees in a patient with a proximal metaphysis stress fracture of the right tibia, associated with severe bilateral knee osteoarthritis, treated with bilateral total knee arthroplasty in two acts, nine months after the first modular total knee arthroplasty

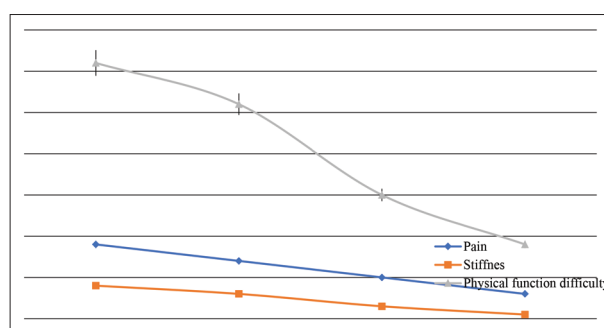


Figure 4. Subscales of the WOMAC index; X-axis: (1) three months after the first total knee arthroplasty (TKA), time of the second TKA; (2) six months after the first TKA, three months after the second TKA; (3) six months after the first TKA, three months after the second TKA; (4) nine months after the first TKA, six months after the second TKA

RESULTS

The study sample included 14 women with an average age of 74.1 ± 2.07 years on the day of the first surgery. The rate of these patients in relation to all TKA surgeries for the observed period was 0.7% (14/1970). All the patients denied any mechanism of trauma related to the pain. The limb axis correction was confirmed after surgery and the fracture healing was clinically and radiologically confirmed in all cases six months after surgery (Figure 2), except for one case complicated by infection, being treated later through another approach.

All the patients preoperatively had a knee flexion contracture. Average extension deficit in the knee with tibial stress fracture was $15^\circ \pm 3.1^\circ$, while on the knee with osteoarthritis it was $7^\circ \pm 2.5^\circ$. At the same time, the average knee flexion in the knee with tibial stress fracture was $55^\circ \pm 2.7^\circ$, and on the knee with just osteoarthritis it was $90^\circ \pm 3.7^\circ$. Nine months after the first surgery, when the rehabilitation following the second surgery was finished, full extension was observed in both knees of all the patients. At the same time, the average flexion was $100^\circ \pm 3.2^\circ$ in the arthritic knee without the fracture, and $85^\circ \pm 2.6^\circ$ in the knee with proximal tibial stress fracture, which was significantly improved compared to the preoperative condition ($p < 0.05$) (Figure 3).

Pain and stiffness reduction as well as improvement of physical function (decrease of physical function difficulty) were noted by the WOMAC index at three and six months after the first TKA surgery, and were improved in relation to preoperative values. This improvement was particularly significant nine months after the first TKA surgery, when the rehabilitation following the second surgery was also finished (Figure 4).

DISCUSSION

Tibial stress fractures in patients with bilateral primary knee osteoarthritis associated with severe flexion varus deformity are rare and complex clinical condition, making its treatment a challenge [4, 6]. This type of fracture is caused by the action of repetitive gravity loads on the proximal tibial metaphysis due to the change of the axes in the knee, both in coronal and sagittal planes. The goal of the treatment in these patients is to achieve the fracture healing, satisfactory joint stability, a normal relation between the limb axes, painless joint mobility, and independent walking. Improving these factors improves the patient's quality of life. Anamnestic data about sudden worsening of the primary knee osteoarthritis symptoms can indicate the proximal tibial stress fracture. The diagnosis of these fractures is performed by radiography. The treatment of these patients is mainly surgical [7, 8]. At the time we treated the first such patient, there were very few published papers on this topic in the literature, with a very small number of cases [9, 10]. Later, we found in the literature different ways of surgical treatment: corrective osteotomies with plate fixation, intramedullary fixation, standard arthroplasty, and the modular TKA [1, 11–18]. Our choice from the beginning was the use of modular TKA in all patients with a proximal tibial stress fracture associated with bilateral primary knee osteoarthritis. Rehabilitation goals were to reduce pain and swelling, improve the range of knee motion, increase the muscular strength of thigh muscles, and achieve the independent gait. We found a radiographically correct finding in most of the patients. The average range of motion in the knees postoperatively was significantly better at six and nine months after the first TKA surgery than preoperatively. Improvement of knee extension was better and faster than knee flexion. However, knee flexion was significantly improved at six and nine months after the first TKA surgery. A small decline or stagnation in the knee flexion recovery at the third month after the first TKA surgery indicates that these limitations were caused by impaired function of the contralateral osteoarthritic knee.

Our sample consisted of elderly women. There is a study that does not confirm these results [3]. As a possible reason for the proximal tibia stress fracture occurrence in this population, associated with the physiological loss of mineral bone density, but due to difficulty in movement, we should also consider the correlation between inactivity and osteoporosis [19].

Our research indicates a significant improvement in general physical functioning as soon as three months after

the first TKA. Given that modular TKA provides the primary goals to be achieved in the surgical treatment of the proximal tibial stress fracture of an osteoarthritic knee (fracture healing, osteoarthritic surfaces plasty, and local biomechanical correction), and that postoperative rehabilitation contributes to better functional results through reducing pain and swelling, it is clear why the physical functioning was significantly better as soon as three months after the first surgery. After the first TKA, the symptoms dominantly influencing the WOMAC index were related to primary osteoarthritis of the other knee.

Only after the definitive treatment is complete in these patients, i.e., after the rehabilitation following the second TKA is complete, the definitive outcome can be fully assessed. Measured by WOMAC index six months after the first TKA, i.e., after the both knees TKA surgeries, the patients experienced good physical functioning, significantly better compared to the preoperative level, but this was also the case at three months after the modular TKA surgery. Since stress fractures of the proximal tibia associated with bilateral primary knee osteoarthritis are rare, few studies, with small sample sizes, have been published [20, 21]. Soundarrajan et al. [22] performed a study on 20 patients and concluded that long-term plaster immobilization slows down the fracture healing process and even can lead to nonunion; thus, modular TKA was suggested as the treatment of choice as soon as possible. The same was confirmed by Sawant et al. [23] through the series cases of four patients. Wui et al. [24] confirmed good short-term results of the treatment with a modular prosthesis on the stress fracture side and standard TKA on the osteoarthritis side in a study of a series of cases. Shah et al. [25] published the results of a study on 62 patients and confirmed that modular stem implantation is a good solution for patients with tibial stress fracture associated with knee osteoarthritis. Studies by Indian researchers from 2019 and 2022 performed on small-samples are in correlation with our results [26, 27].

We did not find a study with the results opposed to our own.

CONCLUSION

Modular TKA followed by postponed standard knee arthroplasty at contralateral side is a suggested choice in the treatment of unilateral proximal tibial metaphysis stress fracture because its application provides a good fracture healing, osteoarthritis treatment, deformity correction, and restoring knees axes to a normal. The quality of life is expected to be significantly improved nine months after the modular TKA surgery, followed by standard contralateral TKA performed about six months after the first TKA. This treatment should include inpatient physical procedures after each surgery, because of its significant contributing to the final outcome improvement.

Conflict of interest: None declared.

REFERENCES

- Tomlinson MP, Dingwall IM, Phillips H. Total knee arthroplasty in the management of proximal tibial stress fractures. *J Arthroplasty*. 1995;10(5):707–13. [DOI: 10.1016/s0883-5403(05)80222-0] [PMID:9273389]
- Cameron HU. Double stress fracture of the tibia in the presence of arthritis of the knee. *Can J Surg*. 1993;36(4):307–10. [PMID: 8370010]
- Ivanovski A, Medjedovic D, Perisic V. Fractures of the metatarsal bones caused by fatigue. *Srp Arh Celok Lek*. 1998;126(3–4):107–10. [PMID: 9863365]
- Shekhar S, Rai A, Prakash S, Khare T, Malhotra R. Single-stage long-stem total knee arthroplasty in severe arthritis with stress fracture: a systematic review. *Knee Surg Relat Res*. 2023;35(1):4. [DOI: 10.1186/s43019-023-00178-2] [PMID: 36658622]
- Miller TL, Best TM. Taking a holistic approach to managing difficult knee fractures. *J Orthop Surg Res*. 2016;11(1):98. [DOI: 10.1186/s13018-016-0431-9] [PMID:27608681]
- Reddy NVR, Saini MK, Reddy PJ, Thakur AS, Reddy CD. Analysis of clinical and radiological outcomes of long tibial stemmed total knee arthroplasty in knee osteoarthritis complicated by tibial stress fracture. *Knee Surg Relat Res*. 2022;34(1):7. [DOI: 10.1186/s43019-022-00139-1] [PMID: 35193706]
- Gill UN, Noor SS, Haneef M, Ahmed N, Iqbal F, Najjad MKR. Management of early and late presenting tibial stress fracture with advanced osteoarthritis of the knee: A dilemma among arthroplasty surgeons in developing countries. *Knee*. 2021;29:95–100. [DOI: 10.1016/j.knee] [PMID: 33601273]
- Dudko OG, Glubochenko OV, Pickula VV, Marchuk OF, Shayko-Shaykovskiy OG. Predisposing factors and treatment of osteoarthritis after surgeries performed for tibial fractures. *World Science*. 2019;12(52):16–9. [DOI: 10.31435/rsglobal_ws/30122019/6825]
- Song M, Lin X, Han W, Li J, Lui W. Is proximal tibial tubercle osteotomy superior to distal tibial tubercle osteotomy for medial compartment osteoarthritis? A meta-analysis. *J Orthop Surg Res*. 2023;18(1):245–8. [DOI: 10.1186/s13018-023-03725-5] [PMID: 36967435]
- Gadhe S, Bhor P, Kanade S, Kale S, Vatlar A, Chaudhari P. Proximal tibial stress fracture with Grade 4 osteoarthritis of knee – experience with long stem TKR. *Int J Orthop Sci*. 2019;5(3):293–7. [DOI: 10.22271/ortho.2019.v5i3e.1543]
- Haspl M, Jelić M, Pečina M. Arthroplasty in treating knee osteoarthritis and proximal tibia stress fracture. *Acta Chir Orthop Traumatol Cech*. 2003;70(5):303–5. [PMID: 14669593]
- Tey IK, Chong KW, Singh I. Stress fracture of the distal tibia secondary to severe knee osteoarthritis: a case report. *J Orthop Surg (Hong Kong)*. 2006;14(2):212–5. [DOI: 10.1177/230949900601400222] [PMID: 16914792]
- Jeremic D, Vitosevic F, Glusevic B, Slavkovic N, Apostolovic M, Lalosevic M, et al. Single center experience in treatment of tibial shaft fractures using the Ilizarov technique. *Srp Arh Celok Lek*. 2020;148(3–4):167–72. [DOI: 10.2298/SARH190901003J]
- Milenkovic S, Mitkovic MM, Mitkovic MB. Unilateral external fixation of the tibial shaft malunion. *Srp Arh Celok Lek*. 2020;148(1–2):37–40. [DOI: 10.2298/SARH190908119M]
- Khakha RS, Bin Abd Razak HR, Kley K, van Heerwaarden R, Wilson AJ. Role of high tibial osteotomy in medial compartment osteoarthritis of the knee: Indications, surgical technique and outcomes. *J Clin Orthop Trauma*. 2021;23:101618. [DOI: 10.1016/j.jcot.2021.101618] [PMID: 35070682]
- Jabalarneli M, Hadi H, Bagherifard A, Rahbar M, Minator, Sajjadi M. Long-stem total knee arthroplasty for proximal tibial stress fractures in the elderly patients. *Arch Bone J Surg*. 2018;6(5):376–80. [PMID: 30320177]
- Kumar Saini M, Singh M, Singh D, Seervi PM, Reddy PJ, Reddy NR. Management of proximal tibial stress fracture associated with advanced knee osteoarthritis: A systematic review. *Chin J Traumatol*. 2023;S1008-1275(23)00068-8. Online ahead of print. [DOI: 10.1016/j.cjtee.2023.07.002] [PMID: 37543509]
- Mittal A, Bhosale PB, Suryawanshi AV, Purohit S. One-stage long-stem total knee arthroplasty for arthritic knees with stress fractures. *J Orthop Surg*. 2013;21(2):199–203. [DOI: 10.1177/230949901302100217] [PMID: 24014784]
- Wang SP, Wu PK, Lee CH, Shih CM, Chiu YC, Hsu CE. Association of osteoporosis and varus inclination of the tibial plateau in postmenopausal women with advanced osteoarthritis of the knee. *BMC Musculoskelet Disord*. 2021;22(1):223. [DOI: 10.1186/s12891-021-04090-2] [PMID: 33632177]
- Osman WS, Younis AS, Thompson J, Amin AA, El-Sebai M. Knee Rheumatoid Arthritis With Lateral Tibial Plateau and Tibial Stress Fractures Managed With One-Stage Knee Joint Replacement. *Arthroplast Today*. 2020;6(3):487–91. [DOI: 10.1016/j.artd.2020.06.002] [PMID: 32685641]
- Rashid RH, Zubairi AJ, Umer M, Hashmi PM, Lakdawala RH. Management of stress fractures of the proximal tibia in patients with advance knee osteoarthritis. A case series. *Acta Orthop Belg*. 2018;84(4):436–42. [PMID: 30879448]
- Soundarrajan D, Rajkumar N, Dhanasekararaja P, Rajasekaran S. Proximal tibia stress fracture with osteoarthritis of knee – Radiological and functional analysis of one stage TKA with long stem. *SICOT J*. 2018;4:13. [DOI: 10.1051/2018006] [PMID: 29667926]
- Sawant MR, Bendall SP, Kavanagh TG, Citron ND. Nonunion of tibial stress fractures in patients with deformed arthritic knees. Treatment using modular total knee arthroplasty. *J Bone Joint Surg Br*. 1999;81(4):663–6. [DOI: 10.1302/0301-620x.81b4.9091] [PMID: 10463741]
- Wui NB, Ahmad Anuar MA, Abdul Wahid AM. Short-term outcome of early primary total knee arthroplasty for fractures around the knee in the elderly population: the experience of a secondary healthcare centre in Malaysia. *Malays J Med Sci*. 2020;27(4):64–71. [DOI: 10.21315/mjms2020.27.4.6] [PMID: 32863746]
- Shah VI, Upadhyay S, Shah K, Sheth A, Kshatriya A, Patil J. Proximal fibular resection improves knee biomechanics and enhances tibial stress fracture healing in patients with osteoarthritis with varus deformity: a prospective, randomized control analysis. *Arthroplasty*. 2020;2(1):11. [DOI: 10.1186/s42836-020-00030-y] [PMID: 35236433]
- Gadhe SS, Bhor P, Kanade G, Kale S, Vatkar A, Chaudhari P. Proximal tibia stress fractures with grade 4 osteoarthritis of knee-experience with long stem TKR. *Int J Orthop Sci*. 2019;5(3):294–7. [DOI: 10.22271/ortho.2019.v5.i3e.1543]
- Reddy NVR, Saini MK, Reddy PJ, Thakur AS, Reddy CD. Analysis of clinical and radiological outcomes of long tibial stemmed total knee arthroplasty in knee osteoarthritis complicated by tibial stress fracture. *Knee Surg Relat Res*. 2022;34(1):7. [DOI: 10.1186/s43019-022-00139-1] [PMID: 35193706]

Тотална артропластика колена код болесника са стресним преломом тибије удруженим са тешким обостраним остеоартритисом колена

Славко Манојловић^{1,2}, Рајко Додик¹, Мирко Манојловић¹, Жељко Јовичић³, Драгана Драгичевић-Цвјетковић^{4,5}

¹Општа болница „Градишка“, Одељење за хирургију, Градишка, Република Српска, Босна и Херцеговина;

²Универзитет у Бањој Луци, Медицински факултет, Катедра за хирургију, Република Српска, Босна и Херцеговина;

³Завод за физикалну медицину и рехабилитацију „Др Мирослав Зотовић“, Одељење за ортопедску хирургију, Бања Лука, Република Српска, Босна и Херцеговина;

⁴Завод за физикалну медицину и рехабилитацију „Др Мирослав Зотовић“, Одељење за балнеологију и рехабилитацију, Бања Лука, Република Српска, Босна и Херцеговина;

⁵Универзитет у Бањој Луци, Медицински факултет, Катедра за физикалну медицину и рехабилитацију, Бања Лука, Република Српска, Босна и Херцеговина

САЖЕТАК

Увод/Циљ Стресни преломи тибије (преломи тибије услед премора) повезани са билатералним остеоартритисом колена су ретки, али због својих последица представљају терапијски изазов. Овај рад има за циљ да прикаже примењени начин лечења ових болесника и његове резултате.

Методе Проспективна студија је пратила 14 болесника просечне старости од 74,1 године са једностраним стресним преломом тибије удруженим са билатералним тешким остеоартритисом колена. Хируршко лечење подразумева у првом чину уградњу модуларне тоталне протезе колена на страни прелома, а у другом чину имплантацију тоталне, контралатералне протезе колена на бази тешког остеоартритиса. Стационарна рехабилитација је обављена после обе операције у трајању од 21 дан и обухватала је примену кинезитерапије, радне терапије, електротерапије, магнетотерапије, хидротерапије и термотерапије. Параметри праћења били су рендгенски снимак – преоперативно и постоперативно, обим покрета преоперативно и на крају лечења и индекс WOMAC преоперативно и постоперативно.

Периоди праћења су били: преоперативно и три, шест и девет месеци постоперативно.

Резултати Радиолошки налази код свих болесника током ових периода праћења били су нормални. Сви стресни преломи тибије су зарасли унутар шест месеци од операције. Локални налаз на коленима код свих болесника девет месеци постоперативно значајно се побољшао у поређењу са преоперативним налазом. Статистички значајно побољшање квалитета живота праћено индексом WOMAC утврђено је у свим постоперативним периодима праћења, посебно у деветом постоперативном месецу ($p < 0,05$).

Закључак Модуларна тотална протеза колена на страни стресног прелома тибије и одложена имплантација контралатералне протезе колена на колено захваћено остеоартритисом у комбинацији са постоперативном болничком рехабилитацијом дају оптималан функционални исход и побољшавају квалитет живота ових болесника.

Кључне речи: тибија; преломи; стрес; колено; остеоартритис; артропластика