

ORIGINAL ARTICLE / ОРИГИНАЛНИ РАД

Diagnostic potential of the infrared thermal camera in the detection of parotid region tumors

Andrija Ćosić¹, Igor Jovanović², Miona Andrejević-Stošović², Dragan Krasić¹, Goran Videnović³, Dragan Mančić², Vladimir Videnović⁴

¹University of Niš, Faculty of Medicine, Clinic for Dental Medicine, Niš, Serbia;

²University of Niš, Faculty of Electronic Engineering, Niš, Serbia;

³University of Priština, Faculty of Medicine, Kosovska Mitrovica, Serbia;

⁴Clinical Hospital Center Zvezdara, Department of Radiology, Belgrade, Serbia



SUMMARY

Introduction/Objective Timely and accurate diagnosis is essential for successfully treating salivary gland tumors. This study aims to examine the possibility of an infrared thermal camera application in the parotid region pathology.

Methods In 36 patients with histopathologically confirmed tumors of the parotid region, the temperature of the area on the side of the tumor and the contralateral, healthy side was measured. The temperature difference was analyzed and compared with the control group. The measurement was performed using a high-resolution infrared thermographic camera. Statistical significance was tested using the T-test and Analysis of Variance (ANOVA) test.

Results The results showed that there is a highly significant difference in temperature between the tumor of the affected parotid regions and the contralateral, healthy side (all tumors: $p = 0.001$; malignant tumors: $p = 0.007$).

Conclusion We concluded that determining the temperature differences between the tumor-affected and contralateral, unaffected sides can be an important tool in diagnosing parotid region tumors.

Keywords: tumors of the parotid region; diagnosis; infrared camera

INTRODUCTION

The salivary gland tumors represent a diverse group of tumors that most often affect the parotid gland, followed by submandibular and sublingual salivary glands [1]. The classification of salivary gland tumors has been recently updated in the 5th edition of the World Health Organization Classification of Head and Neck Tumors which described several new entities of benign (sclerosing polycystic adenoma, keratocystoma, intercalated duct adenoma, striated duct adenoma) and malignant (microsecretory adenocarcinoma and sclerosing microcystic adenocarcinoma) salivary gland tumors [2].

The most common parotid salivary gland tumors are pleomorphic adenoma, Warthin's, and malignant tumors [3]. Parotid salivary gland tumors are often presented as painless masses that clinical examination cannot define. Thus, establishing a timely diagnosis is of great importance for the successful treatment of patients. Furthermore, the differentiation of benign from malignant parotid gland tumors is a big challenge for a maxillofacial surgeon since the choice of treatment method, possible complications and treatment costs depend on it.

Computed Tomography, Magnetic Resonance Imaging, Ultrasonography, Fine Needle Aspiration Biopsy and postoperative histopathological findings are key diagnostic tools

used for identifying, classifying and determining the tumor's size, type and biological potential [1, 3]. All these diagnostic methods have their advantages and disadvantages. For example, ultrasound and fine-needle aspiration (FNA) are relatively inexpensive and safe procedures, but they heavily depend on the experience of the examining and intervening physician. CT and MRI are structural diagnostic procedures, like ultrasound, representing the gold standard for diagnosing and preoperative preparation of patients with tumors. However, they are not suitable for mass use due to the ionizing radiation (CT), expensive equipment, the need for highly trained personnel, and high costs.

Some authors define infrared thermography (IRT) as a functional diagnostic non-invasive, contactless, and cost-effective method that meets the basic requirements for detecting various pathological conditions [4–7]. It can assist clinicians in differential diagnosis and prognostic studies for various maxillofacial diseases [8, 9, 10].

The application of IRT is based on the fact that blood flow, influenced by the neuro-vegetative central nervous system, expands uniformly to the left and right sides of the body, resulting in a symmetrical left and right thermal pattern. Any qualitative and quantitative changes in thermal distribution may indicate an abnormality [11]. According to data retrieved

Received • Примљено:
October 3, 2023

Revised • Ревизија:
December 4, 2023

Accepted • Прихваћено:
December 7, 2023

Online first: January 11, 2024

Correspondence to:

Andrija ĆOSIĆ
Bulevar Dr Zorana Đinđića 52
18000 Niš, Serbia
cosa72@yahoo.com

in the literature, IRT is most commonly used in oncology for diagnosis and monitoring of breast cancer and melanoma [12, 13, 14], while the application in the maxillofacial region is scarce and rarely documented [9, 10].

This study aims to examine the diagnostic potential of IRT as an easily accessible tool for mass use, which can indicate the presence of tumors in the parotid region in the early stages. This can lead to the incorporation of thermal imaging examination as a part of the standard first clinical examination in daily routine practice. The simplicity of the procedure does not require the engagement of additional staff. If thermal imaging of a patient confirms temperature asymmetry, they will be referred to more sophisticated diagnostics with a higher priority level.

METHODS

This study included 36 patients aged 40 to 90 years, who were surgically treated for tumors in the parotid region at the Department of Maxillofacial Surgery of the Clinic for Dental Medicine in Niš.

Criteria for inclusion in the study were patients in whom, based on anamnestic data and clinical examination by a maxillofacial surgery specialist, a tumor in the parotid region was diagnosed with an initial diagnosis. After thermographic imaging procedure, standard surgical treatment with histopathological verification were performed in all patients. This study was approved by the Ethics Committee on Research of the Clinic of Dentistry University of Niš, (No. 20/3-2019-2, 01-1054/2). All participants in research signed informed consent form.

For data analysis, two groups of participants were formed. The first group consisted of patients with malignant tumors and the second comprised patients with benign tumors and non-tumor lesions in the parotid region.

All subjects underwent the same thermographic protocol based on The American Academy of Thermology (AAT) [15], and the medical infrared imaging guidelines outlined by Ring and Ammer [16], and Ammouh et al. [17]. According to the mentioned guidelines, the distance between the subject and the camera was 1 m. The room temperature was 23–24°C, and all subjects rested

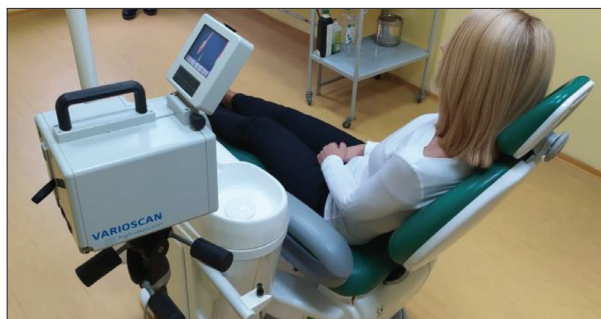


Figure 1. Experimental set-up for the thermal measurement

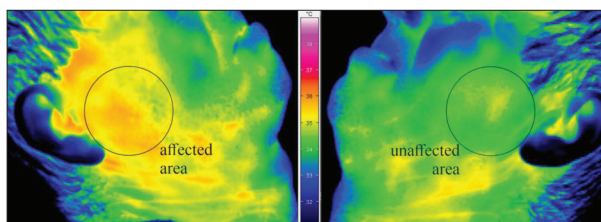


Figure 2. Thermograms of the affected area (left) and unaffected area (right) parotid regions

approximately 15 minutes before imaging, without physical activity, chewing or touching the skin of the face.

The biological behavior of tumors after histopathological verification was defined according to The International Classification of Diseases for Oncology (ICD-O-3) [18]. Malignant tumors, according to the classification above, included histomorphological codes: 8140/3 Adenocarcinoma; 8500/3 Salivary duct carcinoma (Intraductal carcinoma); 8200/3 Adenoid cystic carcinoma; 8805/3 Sarcoma; 9591/3 Non-Hodgkin's lymphoma; 8550/3 Acinic Cell Carcinoma; 9699/3 Mucosa-associated lymphoid tissue (MALT) lymphoma and histology codes 8000/6, 8010/6, 8070/6, which define various origins of metastatic carcinomas.

Benign tumors included histomorphological codes: 8561/0 Warthin's tumor; 8147/0 Basal cell adenoma; 8940/0 Pleomorphic adenoma, and 8850/0 Lipoma. The group of participants with benign tumors also included non-tumor lesions such as Lymphadenopathy and Sialadenitis. Cases where the pathologist did not clearly define the histopathological findings, were excluded from the study.

The infrared thermographic camera Varioscan high-resolution model 3021 (Jenoptik, Germany) was used.

Table 1. Distribution of the parotid region tumors according to tumor type and gender of the patient

Type	Malignant tumors				v	Benign tumors/lesions			
	Male	Female	Total	(%)		Male	Female	Total	(%)
Metastatic tumor	7	3	10	(52.6)	Warthin's tumor	6	3	9	(52.9)
MALT lymphomas	1	1	2	(10.5)	Pleomorphic adenoma	1	2	3	(17.7)
Adenocarcinoma	0	1	1	(5.3)	Basal cell adenoma	0	1	1	(5.9)
Intraductal carcinoma	1	0	1	(5.3)	Sialadenitis	1	1	2	(11.8)
Adenoid cystic carcinoma	0	2	2	(10.5)	Lipomatosis	1	0	1	(5.9)
Sarcoma	1	0	1	(5.3)	Lymphadenopathy	0	1	1	(5.9)
Non-Hodgkin's lymphoma	0	1	1	(5.3)					
Acinic Cell Carcinoma	0	1	1	(5.3)					
Total	10	9	19	(100)		9	8	17	(100)

MALT – mucosa-assisted lymphoid tissue

Table 2. Measurement results of the temperature of the parotid region according to the type of tumor and the gender of the patients

Patient ID	Gender	Pathohistological finding/ diagnosis	T1 (°C)	T2 (°C)	Difference: T1-T2 (°C)
Case 1	Female	Metastatic cSCC	33.67	33.52	+0.15
Case 2	Male	Metastatic cSCC	33.97	33.14	+0.83
Case 3	Female	Metastatic cSCC	34.51	33.98	+0.53
Case 4	Male	Metastatic cSCC	34.33	34.21	+0.12
Case 5	Male	Metastatic cSCC	35.38	34.60	+0.78
Case 6	Male	Metastatic cSCC	35.19	34.66	+0.53
Case 7	Male	Metastatic cSCC	34.46	33.91	+0.55
Case 8	Male	Metastatic cSCC	34.43	34.51	-0.08
Case 9	Female	MALT lymphoma	33.72	33.37	+0.45
Case 10	Male	MALT lymphoma	34.85	35	-0.15
Case 11	Female	Adenocarcinoma	33.18	33.02	+0.16
Case 12	Male	Metastatic urothelial carcinoma	34.98	33.66	+1.32
Case 13	Male	Sarcoma	33.83	33.65	+0.18
Case 14	Male	Intraductal carcinoma	33.21	33.02	-0.19
Case 15	Female	Adenoid cystic carcinoma	34.21	34.12	+0.09
Case 16	Female	Warthin's tumor	35.07	34.3	+0.77
Case 17	Male	Warthin's tumor	33.67	33.7	-0.03
Case 18	Male	Warthin's tumor	34.86	34.72	+0.16
Case 19	Female	Warthin's tumor	32.63	32.49	0.14
Case 20	Male	Warthin's tumor	35.22	34.43	0.79
Case 21	Male	Warthin's tumor	33.64	33.61	0.03
Case 22	Male	Warthin's tumor	34.64	34.42	+0.24
Case 23	Male	Warthin's tumor	33.46	33.44	+0.02
Case 24	Female	Warthin's tumor	33.72	33.12	+0.6
Case 25	Female	Adenoma pleomorpe	33.70	33.9	-0.2
Case 26	Male	Adenoma pleomorpe	34.02	33.39	+0.63
Case 27	Female	Adenoma pleomorpe	33.88	34.29	-0.41
Case 28	Female	Basal cell adenoma	33.93	33.58	0.35
Case 29	Female	Sialadenitis	34.27	35.21	-0.94
Case 30	Male	Sialadenitis	34.84	33.94	+0.90
Case 31	Female	Lymphadenopathy	35.26	34.36	+0.90
Case 32	Male	Lipomatosis	35.33	35.38	-0.05
Case 33	Female	Adenoid cystic carcinoma	34.21	34.12	+0.09
Case 34	Female	Non-Hodgkin's lymphoma	34.88	31.61	+3.27
Case 35	Female	Acinicell carcinoma	34.17	33.4	+0.77
Case 36	Female	Metastatic melanoma	33.16	33.05	+0.11

MALT – mucosa-assisted lymphoid tissue; cSCC – cutaneous squamous cell carcinoma; T1 – the temperature of the side affected by the tumor; T2 – temperature of the tumor-free side

The camera showed the real-time skin temperature on the display, recorded for each patient and each examined side (Figure 1).

The camera has a thermal resolution of $\pm 0.03^{\circ}\text{C}$, a temperature range from -40 to 1200°C , and a spectral range of $8\text{--}12\ \mu\text{m}$. Absolute accuracy of the temperature measurements (factory calibrated) up to 100°C , at an ambient temperature of $22 \pm 2^{\circ}\text{C}$, is less than $\pm 2\text{K}$; otherwise, the accuracy is less than $\pm 1\%$ of the full-scale value.

On the obtained thermograms (Figure 2) regions of interest were analyzed. An affected area represents the area with tumor, and an unaffected area is a contralateral parotid region of the same patient. Digital images of the skin temperature variations were analyzed by IRBIS Professional 2.2. graphics-oriented software package (InfraTec GmbH, Dresden, Germany).

The difference in the mean temperature of the affected and unaffected side of the parotid region was tested with a Paired Samples t-Test and Analysis of Variance (ANOVA) test. Previously, data were tested with the Kolmogorov-Smirnov test to check for normality of distribution.

The temperature difference was tested through four types of statistical tests, as follows: affected and unaffected side for all patients with tumors (Test 1); affected and unaffected side for patients with malignant tumors (Test 2); affected and unaffected side for patients with benign tumors (Test 3). The level of 0.05 was taken as the statistical significance threshold for all tests. All statistical tests were performed in SPSS v20.

RESULTS

Thirty-six patients with benign and malignant tumors in the parotid region participated in our study (17 women and 19 men). The average age was 61.4 years. Men were slightly older (61.9 years) than women (60.8 years) but without statistical significance. One tumor was registered in each patient. More than half (58.8%) of benign tumors were registered in patients younger than 50, while 68.4% of malignant tumors were in patients in their seventh decade of life and later. ANOVA showed no statistically significant interaction between the effects of gender and type of tumor ($F = 0.414$, $p = 0.526$). In contrast, the interaction between the effects of age and type of tumor was statistically significant ($F = 3.655$, $p = 0.017$). The probability of developing malignant tumors was higher in older patients (Eta-square is 0.36).

The most common benign tumor in our patients was Warthin's, which accounted for 52.9% of all registered benign tumors, followed by Pleomorphic adenomas with 17.7%. The most common malignant tumors were metastatic tumors, with 52.6% of the total malignant parotid region tumors (Table 1).

Table 2. shows the temperature difference between the parotid region where the tumor is located (T1) and the contralateral, unaffected parotid region (T2) according to the gender of the patient and the pathohistological findings, that is, the diagnosis. Regardless of biological behaviour, the temperature difference in all tumors ranged from -0.03°C to 3.27°C (mean value 0.37°C). The minimum temperature difference in patients with malignant tumors was -0.08°C (Intraductal carcinoma), while the maximum was $+3.27^{\circ}\text{C}$ (Non-Hodgkin's lymphoma). The mean temperature difference in patients with malignant tumors was $+0.5^{\circ}\text{C}$, regardless of gender. The minimum

Table 3. Paired samples t-test statistics output

Test type	Area descriptions	N	Mean value (°C)	Standard deviation	t-test	df	p-value
Test 1 (all tumors)	Affected area	36	34.27	0.70	3.577	35	0.001*
	Unaffected area	36	33.88	0.77			
Test 2 (malignant tumors)	Affected area	19	34.22	0.66	3.066	18	0.007*
	Unaffected area	19	33.69	0.78			
Test 3 (benign tumors)	Affected area	17	34.33	0.75	1.934	16	0.071
	Unaffected area	17	34.09	0.74			

*statistically significant difference; df- degrees of freedom

temperature difference in patients with benign tumors was -0.03°C (Warthin's tumor), and the maximum was 0.9°C (Sialadenitis and Lymphadenopathy). The mean temperature difference in patients with benign tumors was $+0.23^{\circ}\text{C}$, regardless of gender.

Table 3. shows the statistical significance in the temperature difference between the tumor-affected parotid region (affected area) and the contralateral side (unaffected area) in all tumors (Test 1), malignant tumors (Test 2) and benign tumors (Test 3).

There is a highly significant difference in temperature between tumor-affected parotid regions and the contralateral, unaffected side, compared to all tumors ($t_{35} = 3.577$, $p = 0.001$) (Test 1). The mean temperature difference is 0.39°C , while the CI (95% Confidence Interval of the Difference) shows that this difference can be found from 0.17°C to 0.61°C .

Test 2 shows that there is a significant difference in temperature between malignant tumour-affected parotid regions and the contralateral, unaffected side ($t_{18} = 3.066$, $p = 0.007$) and that this difference can be found in the range of 0.17°C to 0.9°C . For Test 3 p-value is just above the cut-off value of 0.05, and the CI is narrow enough, so there is a suggestion hint of an effect of statistical significance.

DISCUSSION

The age structure of our patients with benign and malignant parotid gland tumors mostly agrees with the findings of other authors [19, 20, 21]. However, some authors reported a significantly lower average age of patients in their research [22]. This difference in the mentioned articles is probably due to the different percentages of benign and malignant tumors. In our research, the percentage of malignant tumors is higher than in the studies mentioned.

The more frequent appearance of malignant parotid region tumors after the seventh decade can also be seen in the works of other authors [23, 24], who state that the average age of patients with malignant tumors is higher by approximately one decade compared to patients with benign tumors. Mayer et al. [20] found in their study, a large number of patients (average age 78.4 years) had infiltration or metastasis of squamous skin cancer in the parotid region.

In our research, the dominant types of benign tumors were Warthin's tumor and pleomorphic adenoma, which

corresponds to the works of other authors [25, 26], while the most common malignant parotid region tumor was secondary Metastatic tumor of cutaneous squamous cell carcinoma. Mucoepidermoid carcinomas, acinic cell carcinomas and adenoid cystic carcinomas are described in the literature [10, 22, 27] as the most common malignant parotid gland tumors, which contradicts our findings. Our results are in accordance with the research of Mayer et al. [20], where in surgically treated 164 patients with malignant parotid gland

tumors, 71.5% were secondary (metastatic) carcinomas. Reports on using an infrared thermographic camera in diagnosing pathological conditions of the parotid region are very scarce in the literature. According to our knowledge, only one report with a limited series of 17 patients refers to the analysis of the hyperthermic reaction of the pathological process of the parotid region. It also does not specify the temperature difference between the affected and contralateral, unaffected sides [28].

Our study showed that the mean temperature on the side of malignant tumors was higher by $+0.5^{\circ}\text{C}$ compared to the contralateral unaffected side, and on the side of benign tumors by $+0.23^{\circ}\text{C}$. The temperature difference in malignant tumors ranged from -0.08°C to $+3.27^{\circ}\text{C}$ and in benign tumors, from -0.03°C to 0.9°C (Table 2). Our results agree with the research of Durnovo et al. [10], who used thermographic analysis to include 250 patients with various pathological conditions of the maxillofacial region. In 96 patients with benign and malignant tumors (54 benign and 42 malignant) of the maxillofacial region, the authors registered higher temperature values in the region of the malignant tumor (on average $+3.2 \pm 0.4^{\circ}\text{C}$ compared to the contralateral side) than in the region of the benign tumors (from $+0.4$ - 1.4°C). Macianskyte et al. [8] also registered thermal asymmetry (temperature difference between tumor-affected and unaffected sides) in histopathologically and CT-verified tumors of the maxillofacial region. In their study, when pathology was not detected upon CT evaluation, as in the case of the healthy subjects, then there was no temperature asymmetry between the sides. In contrast, when CT delineated a tumour structure, later confirmed with histopathology, then the left-right asymmetry in temperature corresponded to the location of tumour detected on CT. The temperature difference between lesion and normal zones was of 0.4°C or higher. In our research, high statistical significance in thermal asymmetry (all tumors: T-test 3.577, $P = 0.001$; malignant tumors: T-test 3.066, $P = 0.007$) indicates the existence of a malignant parotid region tumor. Statistical significance was not found in benign tumors (Test 3), p-value is just above the cut-off value of 0.05, and the CI is narrow enough, so there is a suggestion hint of an effect of statistical significance. The lack of statistical significance does not mean there is no effect, because the true mean temperature difference could be 0.23°C , or even as large as 0.49°C (CI), and further studies with a larger sample size may help clarify the true difference.

Thermal symmetry of the face is a normal finding in healthy people and the thermogram of a healthy person shows a uniform and symmetrical change in skin temperature with a very small deviation between one side and the other, no more than 0.2–0.4°C [8]. Any asymmetric temperature distribution is an indication of dysfunction – malignant and benign tumors, inflammations, sports injuries, and myofascial pain syndrome [6, 7, 9]. Still, in our research, we considered temperature changes only as a consequence of confirmed tumor existence. Our results have shown that some histopathologically verified malignant tumors had lower thermal asymmetry than the above values. This asymmetry may be due to focusing on hypothermic necrotic zones in malignant tumors during the measurement. The change in metabolism and structural anatomical variations in the tumor region can explain the temperature asymmetry between the tumor-affected and the contralateral region. Tumors have increased metabolism, and in the tumor tissue, there are changes in the blood vessels that vascularize the tumor tissue, consequently leading to an increase in temperature in the tumor region [29]. Macianskyte et al. [8] point out that angiogenesis leading to vascularization within the tumor occurs long before any other clinical changes appear. Lahiri et al. [30] state that the reason for the hyperthermic reaction of the malignant tumor zone lies in the fact that the blood vessels formed by malignant tumors are endothelial tubes without a muscle layer and, therefore, cannot narrow upon sympathetic stimulation, which causes a hyperthermic reaction due to vasodilatation.

REFERENCES

- Bell RB, Fernandes R, Andersen P. Oral, Head and Neck Oncology and Reconstructive Surgery. Elsevier. 2018;850–1.
- Skálová A, Hyrcza MD, Leivo I. Update from the 5th Edition of the World Health Organization Classification of Head and Neck Tumors: Salivary Glands. *Head Neck Pathol.* 2022;16(1):40–53. [DOI: 10.1007/s12105-022-01420-1] [PMID: 35312980]
- Chang YJ, Huang TY, Liu YJ, Chung HW, Juan CJ. Classification of parotid gland tumors by using multimodal MRI and deep learning. *NMR Biomed.* 2021;34(1):e4408. [DOI: 10.1002/nbm.4408] [PMID: 32886955]
- Tiwari D, Dixit M. Deep Multi-View Breast Cancer Detection: A Multi-View Concatenated Infrared Thermal Images Based Breast Cancer Detection System using Deep Transfer Learning. *Traitement du Signal.* 2021;38(6):1699–711. [DOI: 10.18280/ts.380613]
- Verstockt J, Verspeek S, Thiessen F, Tjalma WA, Brochez L, Steenackers G. Skin Cancer Detection Using Infrared Thermography: Measurement Setup, Procedure and Equipment. *Sensors (Basel).* 2022;22(9):3327. [DOI: 10.3390/s22093327] [PMID: 35591018]
- Brenner M, Braun C, Oster M, Gulko PS. Thermal signature analysis as a novel method for evaluating inflammatory arthritis activity. *Ann Rheum Dis.* 2006;65(3):306–11. [DOI: 10.1136/ard.2004.035246] [PMID: 16150784]
- Moreira DG, Costello JT, Brito CJ, Adamczyk JG, Ammer K, Bach AJE, et al. Thermographic imaging in sports and exercise medicine: A Delphi study and consensus statement on the measurement of human skin temperature. *J Therm Biol.* 2017;69:155–62. [DOI: 10.1016/j.jtherbio.2017.07.006] [PMID: 29037377]
- Macianskyte D, Monastyreckiene E, Basevicius A, Adaskevicius R. Comparison of segmented thermal images versus a CT scanning for detection of maxillofacial pathology. *Dentomaxillofac Radiol.* 2019;48(4):20180075. [DOI: 10.1259/dmfr.20180075] [PMID: 30707623]
- Macianskyte D, Adaškevičius R. Automatic Detection of Human Maxillofacial Tumors by Using Thermal Imaging: A Preliminary Study. *Sensors (Basel).* 2022;22(5):1985. [DOI: 10.3390/s22051985] [PMID: 35271132]
- Durnovo EA, Potekhina YP, Marochkina MS, Yanova NA, Sahakyan MY, Ryzhevsky DV. Diagnostic Capabilities of Infrared Thermography in the Examination of Patients With Diseases of Maxillofacial Area. *Sovremennye Tehnologii v Medicine.* 2014;6(2):61–5.
- Haddad DS, Brioschi ML, Baladi MG, Arita ES. A new evaluation of heat distribution on facial skin surface by infrared thermography. *Dentomaxillofac Radiol.* 2016;45(4):20150264. [DOI: 10.1259/dmfr.20150264] [PMID: 26891669]
- Jessie B, Liang J, Li Y, Fahimi B. High-Frequency Excitation and Surface Temperature Analysis of Breast Tissue for Detection of Anomaly. *Biomed Res Int.* 2023;2023:4406235. [DOI: 10.1155/2023/4406235] [PMID: 36817859]
- Okabe T, Fujimura T, Okajima J, Kambayashi Y, Aiba S, Maruyama S. First-in-human clinical study of novel technique to diagnose malignant melanoma via thermal conductivity measurements. *Sci Rep.* 2019;9(1):3853. [DOI: 10.1038/s41598-019-40444-6] [PMID: 30846837]
- Verstockt J, Verspeek S, Thiessen F, Tjalma WA, Brochez L, Steenackers G. Skin Cancer Detection Using Infrared Thermography: Measurement Setup, Procedure and Equipment. *Sensors (Basel).* 2022;22(9):3327. [DOI: 10.3390/s22093327] [PMID: 35591018]
- The American Academy of Thermology. Guidelines For Dental-Oral And Systemic Health Infrared Thermography. *Pan Am J Med Thermol.* 2015;2(1):44–53. [DOI: 10.18073/2358-4696/pajmt.v2n1p44-53]
- Ring EF, Ammer K. Infrared Thermal Imaging in Medicine. *Physiol Meas.* 2012;33(3):R33–46. [DOI: 10.1088/0967-3334/33/3/R33] [PMID: 22370242]

CONCLUSION

Based on the statistical analysis of our results, we can conclude that determining the temperature difference between the tumor-affected and contralateral sides may be an appropriate tool in diagnosing parotid region malignant tumors. In our opinion, this non-invasive and safe method with appropriate software development has diagnostic potential for detecting parotid region tumors.

ACKNOWLEDGEMENT

This work has been supported by the Ministry of science, technological development and innovation of the Republic of Serbia, contract no. 451-03-47/2023-01/200102.

Conflict of interest: None declared.

17. Ammouh M, Gzawi AM, Warawreh A, Hijazin R, Jafar H. Clinical Evaluation of Thermography as a Diagnostic Tool in Oral and Maxillofacial Lesions. *Journal of the Royal Medical Services*. 2018;25(3):45–9. [DOI: 10.12816/00532]
18. Fritz A, Percy C, Jack A, Shanmugaratnam K, Sobin L, Parkin M, et al. (eds). *International Classification of Diseases for Oncology (ICD – O)*. Third Edition, First Revision. Geneva: World Health Organisation; 2013.
19. Cunha JL, Coimbra AC, Silva JV, Nascimento IS, Andrade ME, Oliveira CR, et al. Epidemiologic analysis of salivary gland tumors over a 10-years period diagnosed in a northeast Brazilian population. *Med Oral Patol Oral Cir Bucal*. 2020;25(4):e516–e522. [DOI: 10.4317/medoral.23532] [PMID: 32388524]
20. Mayer M, Thoenken R, Jering M, Märkl B, Zenk J. Metastases of Cutaneous Squamous Cell Carcinoma Seem to be the Most Frequent Malignancies in the Parotid Gland: A Hospital-Based Study From a Salivary Gland Center. *Head Neck Pathol*. 2021;15(3):843–51. [DOI: 10.1007/s12105-021-01294-9] [PMID: 33544379]
21. Dell'Aversana Orabona G, Salzano G, Abbate V, Bonavolontà P, Committeri U, Seidita F, et al. Malignant tumours of the parotid gland: management of the neck (including the clinically negative neck) and a literature review. *Br J Oral Maxillofac Surg*. 2021;59(6):665–71. [DOI: 10.1016/j.bjoms.2020.08.026] [PMID: 33952405]
22. Zuo H. The Clinical Characteristics and CT Findings of Parotid and Submandibular Gland Tumours. *J Oncol*. 2021;2021:8874100. [DOI: 10.1155/2021/8874100] [PMID: 34306079]
23. Fonseca FP, Carvalho Mde V, de Almeida OP, Rangel AL, Takizawa MC, Bueno AG, et al. Clinicopathologic analysis of 493 cases of salivary gland tumors in a Southern Brazilian population. *Oral Surg Oral Med Oral Pathol Oral Radiol*. 2012;114(2):230–9. [DOI: 10.1016/j.oooo.2012.04.008] [PMID: 22769409]
24. Kara M, Göze F, Ezirganli S, Polat S, Muderris S, Elagoz S. Neoplasms of the salivary glands in a Turkish adult population. *Med Oral Patol Oral Cir Bucal*. 2010;15(6):e880–5. [DOI: 10.4317/medoral.15.e880] [PMID: 20526249]
25. Barnes LB, Eveson JW, Reichart P, Sidransky D, editors. *Pathology and genetics of head and neck tumors*. Lyon: IARC Press, 2005. [PMID: 16579185]
26. Franzen AM, Funzel T, Lieder A. Parotid gland metastasis of distant primary tumours: a diagnostic challenge. *Auris Nasus Larynx*. 2016;43(2):187–91. [DOI: 10.1016/j.anl.2015.09.010] [PMID: 26526643]
27. Dimitrijevic M, Boricic I, Tomanovic N, Dimitrijevic A, Bjelogrić G, Krstić A, et al. Clinicopathological Analysis of 907 Major and Minor Salivary Gland Tumors. *J Craniofac Surg*. 2022;33(5):e507–e509. [DOI: 10.1097/SCS.00000000000008482] [PMID: 36041131]
28. Champy M, Bourjat P, Schnebelen JM. Thermographic exploration of the parotid region. *J Maxillofac Surg*. 1976;4(3):163–71. [DOI: 10.1016/s0301-0503(76)80026-4] [PMID: 1066416]
29. Stark AM, Way S. The screening of well women for the early detection of breast cancer using clinical examination with thermography and mammography. *Cancer*. 1974;33(6):1671–9. [DOI: 10.1002/1097-0142(197406)33:6<1671::aid-cnrc2820330630>3.0.co;2-4] [PMID: 4834162]
30. Lahiri BB, Bagavathiappan S, Jayakumar T, Philip J. Medical applications of infrared thermography: A review. *Infrared Phys Technol*. 2012;55(4):221–35. [DOI: 10.1016/j.infrared.2012.03.007] [PMID: 32288544]

Дијагностичке могућности инфрацрвене термовизијске камере у откривању тумора паротидног региона

Андрија Ћосић¹, Игор Јовановић², Миона Андрејевић-Стошовић², Драган Красић¹, Горан Виденовић³, Драган Манчић², Владимир Виденовић⁴

¹Универзитет у Нишу, Медицински факултет, Клиника за денталну медицину, Ниш, Србија;

²Универзитет у Нишу, Електронски факултет, Ниш, Србија;

³Универзитет у Приштини, Медицински факултет, Косовска Митровица, Србија;

⁴Клиничко-болнички центар „Звездара“, Служба за радиологију, Београд, Србија

САЖЕТАК

Увод/Циљ Правовремена и тачна дијагноза је од великог значаја за успешно лечење тумора пљувачних жлезда. Циљ овог рада је да се испита могућност примене инфрацрвене термалне камере у патологији паротидне регије.

Метод Код 36 болесника са хистопатолошки потврђеним туморима паротидног региона мерена је температура на страни тумора и на контралатералној, здравој страни. Разлика у температури је анализирана и упоређивана са контролном групом. Мерење је обављено помоћу инфрацрвене термографске камере високе резолуције. Статистичка

значајност је тестирана коришћењем т-теста и теста анализе варијансе (ANOVA).

Резултати Резултати су показали постојање високо значајне разлике у температури између тумором захваћене паротидне регије и контралатералне, здраве стране (сви тумори: $p = 0,001$; малигни тумори: $p = 0,007$).

Закључак Закључили смо да одређивање температурне разлике између тумором захваћене стране и контралатералне, захваћене стране може бити важан алат у дијагностици тумора паротидног региона.

Кључне речи: тумори паротидног региона; дијагноза; инфрацрвена камера