

## CASE REPORT / ПРИКАЗ БОЛЕСНИКА

# Resection of inferior vena cava leiomyosarcoma and reconstruction using ProxiCor patch

Aleksandar R. Karamarković, Vladica V. Ćuk, Jovan T. Juloski

Zvezdara University Clinical Center, Nikola Spasić Surgical Clinic, Belgrade, Serbia;  
University of Belgrade, Faculty of Medicine, Belgrade, Serbia**SUMMARY**

**Introduction** Leiomyosarcoma of the inferior vena cava (IVC) is a rare mesenchymal tumor originating from the endothelial smooth muscle of the intima and account for about 1–2% of all the sarcomas of the soft tissue.

The objective of this article is to show a case of IVC leiomyosarcoma, its resection and reconstruction using a ProxiCor patch.

**Case outlines** We showed a case of a 65-year-old woman presented with abdominal pain and mass in subhepatic space, who underwent surgery and resection of a leiomyosarcoma of IVC. IVC was reconstructed with ProxiCor patch, and histopathologically confirmed that it was leiomyosarcoma.

**Conclusion** Our experience has shown that the application of extracellular matrix is safe and has given a satisfactory treatment result. A comparison with a larger patient sample should give a true representation of the advantages and disadvantages of this type of material in vascular reconstructive procedures.

**Keywords:** inferior vena cava; leiomyosarcoma; ProxiCor

**INTRODUCTION**

Leiomyosarcoma (LMS) of the inferior vena cava (IVC) is a rare mesenchymal tumor originating from the endothelial smooth muscle of the intima and account for about 1–2% of all the soft tissue sarcomas [1]. From Perl and Virchow's first description in 1871 until today, less than 450 cases have been reported in literature [2]. Women in the fifth to sixth decade of life are dominantly affected [3]. Radical tumor resection was associated with better five- and 10-year survival rates 49.4% and 29.5%, respectively [3].

Because this disease is not common, data for management of this tumor are scarce and radical removal with grossly negative margins is considered the main treatment option [4]. Reconstruction techniques of IVC vary greatly in the published literature so far, which makes it difficult to form a consensus on the most appropriate reconstruction strategies, especially when achieving negative margins requires reconstruction in the form of interposition of different grafts [5, 6].

The purpose of this case report is to document our center's experience with IVC reconstruction using ProxiCor (Elutia, Silver Spring, MD, USA) patch after "en block" resection of LMS and the belonging segment of the IVC in order to achieve negative resection margins.

**CASE REPORT**

A 65-year-old female with a recent history of chronic abdominal pain was referred to our

clinic. An abdominal computed tomography scan showed a mass of 73 × 56 × 54 mm in the subhepatic space, just below the right adrenal gland in close relationship with the IVC (Figures 1a and 1b). Esophago-gastro-duodenoscopy and colonoscopy showed normal findings.

After multidisciplinary evaluation of the case, the patient was offered surgical treatment. Through midline incision, and after Cattell-Braasch and a Kocher maneuver, the infrahepatic IVC and renal veins were exposed. Intraoperative finding showed that previously described mass originated from the anterior aspect of the upper segment of the IVC, and it did not infiltrate the adjacent structures. Both renal veins and the right gonadal vein were prepared and reined in (Figure 1). A cranial and caudal clamping of the IVC was applied and the tumor was resected (Figure 2).

The vena cava defect of approximately 7 cm in size was reconstructed using a ProxiCor patch (Elutia).

The patch was sutured with two 5/0 polypropylene running sutures (Figure 3.). A heparinized solution was injected into the vessel and vascular clamp was then removed with good results.

The patient tolerated the procedure well and had no complications during her stay in the hospital. The patient was discharged on the ninth postoperative day with oral anticoagulant therapy.

No symptoms, nor complications were observed during the postoperative period and checkups.

**Received • Примљено:**  
February 6, 2023

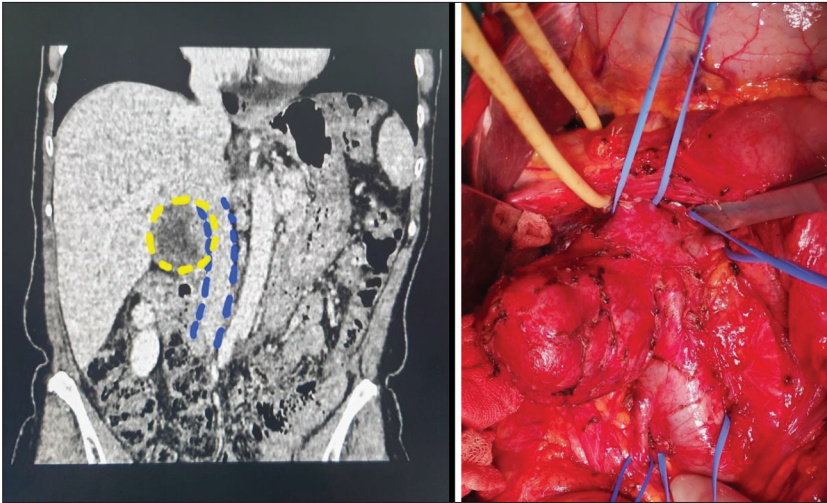
**Revised • Ревизија:**  
June 4, 2023

**Accepted • Прихваћено:**  
June 22, 2023

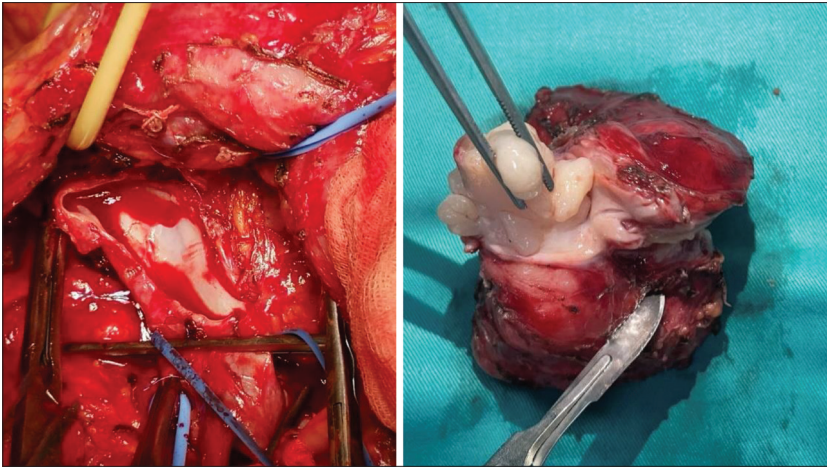
**Online first:** July 10, 2023

**Correspondence to:**

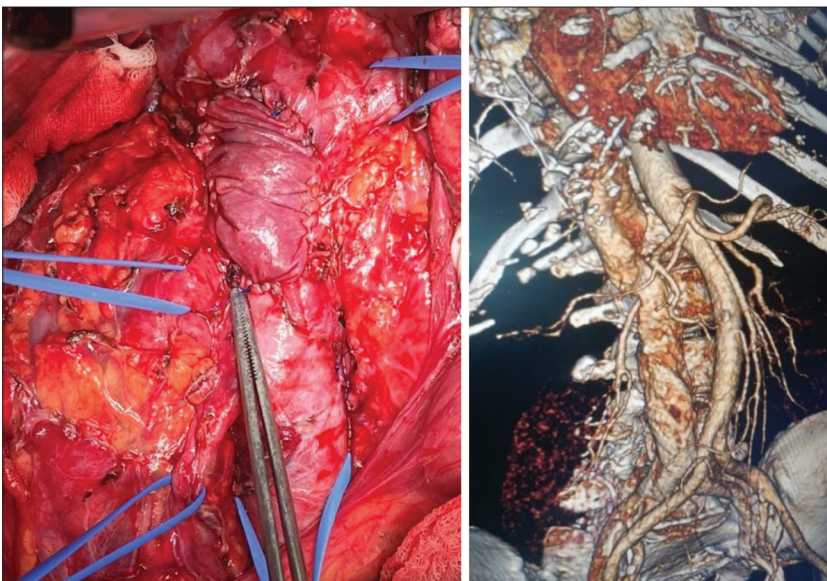
Jovan JULOSKI  
Zvezdara University Clinical  
Center  
Nikola Spasić Surgical Clinic  
Dimitrija Tucovića 161  
11050 Belgrade  
Serbia  
[jovan.juloski@gmail.com](mailto:jovan.juloski@gmail.com)



**Figure 1.** Multidetector computed tomography of the abdomen, coronal section; the yellow dashed lines mark the tumor; the blue dashed lines mark the border of the inferior vena cava (left); intraoperative finding (right); yellow tape is on the hepatoduodenal ligament, the uppermost blue tape on the inferior vena cava, left blue tape is on the left renal veins, two lower blue tapes are on the right gonadal vein and lower portion of the inferior vena cava



**Figure 2.** Resected inferior vena cava (left); resected tumor protruding into the lumen of the inferior vena cava (right)



**Figure 3.** Inferior vena cava reconstruction using ProxiCor patch (Elutia), intraoperative appearance (left); a three-dimensional multidetector computed tomography reconstruction during the postoperative period (right)

The histomorphological and immunohistochemical characteristics of the tumor correspond to a high-grade primary malignant mesenchymal tumor of smooth muscle differentiation of the LMS type, with the largest diameter of 67 mm.

No evidence of the disease at the time of this report, six months after the surgery.

This case report was approved by the institutional ethics committee, and written consent was obtained from the patient for the publication of this case report and any accompanying images.

## DISCUSSION

LMS of the IVC are exceedingly rare and with an incidence  $< 1/100,000$  of all adult malignancies [7]. Because of the rarity of the disease, case studies and case reports are making the majority of available literature, thus are clinical decisions in everyday practice so difficult and no consensus on ideal management of these tumors exist. To our knowledge, surgical resection with negative margins is currently the only curative treatment and the best predictor of long-term survivals for LMS of the IVC [8]. In study conducted by Hines et al. [9], which included 14 patients with IVC LMSs, a five-year survival rate in patients who had positive margins was 0%, while on the other hand, patients with negative margins had significantly higher five-year survival rate of 68%. Similar results were shown in a study by Hollenbeck et al. [10] that included 25 patients, which showed a three-year survival of 76% in patients with negative margins and 0% in group of patients with positive margins. On the other hand, a recent study has shown that neither disease-free survival rate, nor overall survival was not influenced by microscopic margin status [2].

In rare cases, the slow growth of the tumor causes complete obstruction of the IVC and promotes the development of numerous collaterals, and allows radical surgery without vascular reconstruction of IVC; however, low extremity edema is a frequent complication [11].

In the majority of cases, after resection of the IVC due to LMS, vascular reconstruction is often required. In the previous literature, the highest percentage of reconstruction involves the use of polytetrafluoroethylene graft [12]. In a study by Pan et al. [12] among the 315 cases (83.6%) with provided operative details, the IVC was ligated



in 20.3%, primarily repaired in 21.9%, and replaced by prosthetic graft in 49.2%. Other types of materials that were used in reconstruction of IVC included: cadaveric graft (3.2%), bovine pericardium (1.6%), autologous vein (3.5%), and autologous peritoneum (0.3%) [12].

The use of biological material in IVC reconstruction is extremely rare [12, 13]. Therefore, the main indication for the application of biological material remains after the removal of the infected prosthetic graft [13]. In our case, we used ProxiCor (Elutia) to reconstruct the IVC defect after resection. ProxiCor (Elutia) is an extracellular matrix (ECM) derived from submucosa of porcine small intestine.

The previous experience of this material is dominant in cardiac surgery in pericardial reconstruction and in cases such as repair of atrial or ventricular septal defect [14]. Unlike the synthetic alternative, this material has shown reduced foreign body reaction and postoperative inflammation [14]. Compared to other materials used in reconstructive procedures, ECM is significantly more expensive. To the best of our knowledge this is the first case of vascular reconstruction by ECM after IVC resection due to LMS. In our case, after the application of this material, there

were no postoperative complications in the form of IVC thrombosis, thromboembolic complications, or infections.

Intraoperative bleeding control with caudal and proximal IVC clamping has been shown to lead to stasis and increase the risk of thrombosis, and therefore intraoperative systemic heparinization prevents this complication [15]. In contrast, the use of postoperative systemic anticoagulants after IVC resection and reconstruction is still debated and there are no clear guidelines on this topic. During the hospitalization, our patient was prescribed low-molecular-weight heparin (0.4 ml twice a day), while in the postoperative period, novel anticoagulant drug was prescribed. Until the publication of the case report, the patency of the reconstructed segment of the vena cava was preserved.

Our experience has shown that the application of ECM is safe and has given a satisfactory treatment result. A comparison with a much larger number of patients will give a true presentation of the advantages and disadvantages of this type of material in vascular reconstructive procedures.

**Conflict of interest:** None declared.

## REFERENCES

- Dzsinich C, Gloviczki P, van Heerden JA, Nagorney DM, Pairolo PC, Johnson CM, et al. Primary venous leiomyosarcoma: a rare but lethal disease. *J Vasc Surg.* 1992;15(4):595–603. [DOI: 10.1016/0741-5214(92)90003-Q] [PMID: 1560548]
- Keller K, Jacobi B, Jabal M, Stavrou GA. Leiomyosarcoma of the inferior vena cava: A case report of a rare tumor entity. *Int J Surg Case Rep.* 2020;71:50–3. [DOI: 10.1016/j.ijscr.2020.04.094] [PMID: 32438337]
- Rusu CB, Gorbatâi L, Szatmari L, Koren R, Bungârdean CI, Feciche BO, et al. Leiomyosarcoma of the inferior vena cava. Our experience and a review of the literature. *Rom J Morphol Embryol.* 2020;61(1):227–33. [DOI: 10.47162/RJME.61.1.25] [PMID: 32747914]
- Gaignard E, Bergeat D, Robin F, Corbière L, Rayar M, Meunier B. Inferior Vena Cava Leiomyosarcoma: What Method of Reconstruction for Which Type of Resection? *World J Surg.* 2020;44(10):3537–44. [DOI: 10.1007/s00268-020-05602-2] [PMID: 32445073]
- Risaliti M, Fortuna L, Bartolini I, Taddei A, Muiesan P. Inferior vena cava resection and reconstruction with a peritoneal patch for a leiomyosarcoma: A case report. *Int J Surg Case Rep.* 2020;71:37–40. [DOI: 10.1016/j.ijscr.2020.04.031] [PMID: 32438334]
- Kalluri AG, Jain AK, Rodriguez HE, Eskandari MK. Polytetrafluoroethylene Is a Safe and Effective Interposition Conduit for Caval Reconstruction After Resection of Primary Leiomyosarcoma of the Inferior Vena Cava. *Ann Vasc Surg.* 2019;58:289–94. [DOI: 10.1016/j.avsg.2018.12.068] [PMID: 30769055]
- López-Ruiz JA, Tallón-Aguilar L, Marenco-de la Cuadra B, López-Pérez J, Oliva-Mompeán F, Padillo-Ruiz J. [Leiomyosarcoma of the inferior vena cava. Case report and literature review]. *Cir Cir.* 2017;85(4):361–5. [DOI: 10.1016/j.circir.2016.05.002] [PMID: 27318389]
- Zhou M, Javadi C, Charville GW, Bui NQ, Harris EJ, Poultsides GA, et al. Surgical resection of leiomyosarcoma of the inferior vena cava: A case series and literature review. *Surg Oncol.* 2021;39:101670. [DOI: 10.1016/j.suronc.2021.101670] [PMID: 34710646]
- Hines OJ, Nelson S, Quinones-Baldrich WJ, Eilber FR. Leiomyosarcoma of the inferior vena cava: prognosis and comparison with leiomyosarcoma of other anatomic sites. *Cancer.* 1999;85(5):1077–83. [PMID: 10091791]
- Hollenbeck ST, Grobmyer SR, Kent KC, Brennan MF. Surgical treatment and outcomes of patients with primary inferior vena cava leiomyosarcoma. *J Am Coll Surg.* 2003;197(4):575–9. [DOI: 10.1016/S1072-7515(03)00433-2] [PMID: 14522326]
- Daylami R, Amiri A, Goldsmith B, Troppmann C, Schneider PD, Khatri VP. Inferior vena cava leiomyosarcoma: is reconstruction necessary after resection? *J Am Coll Surg.* 2010;210(2):185–90. [DOI: 10.1016/j.jamcollsurg.2009.10.010] [PMID: 20113938]
- Pan J, Qiu CY, He YY, Xue X, Li DL, Tian L, et al. A 10-year experience of leiomyosarcoma of the inferior vena cava. *Phlebology.* 2022;37(8):572–8. [DOI: 10.1177/02683555221101706] [PMID: 35570826]
- Gaignard E, Bergeat D, Robin F, Corbière L, Rayar M, Meunier B. Inferior Vena Cava Leiomyosarcoma: What Method of Reconstruction for Which Type of Resection? *World J Surg.* 2020;44(10):3537–44. [DOI: 10.1007/s00268-020-05602-2] [PMID: 32445073]
- Rego A, Cheung PC, Harris WJ, Brady KM, Newman J, Still R. Pericardial closure with extracellular matrix scaffold following cardiac surgery associated with a reduction of postoperative complications and 30-day hospital readmissions. *J Cardiothor Surg.* 2019;14(1):61. [DOI: 10.1186/s13019-019-0871-5] [PMID: 30876459]
- Bower TC, Nagorney DM, Cherry KJ Jr, Toomey BJ, Hallett JW, Panneton JM, et al. Replacement of the inferior vena cava for malignancy: an update. *J Vasc Surg.* 2000;31(2):270–81. [DOI: 10.1016/s0741-5214(00)90158-7] [PMID: 10664496]

## Ресекција лејомиосаркома доње шупље вене и реконструкција *ProxiCor*-ом

Александар Р. Карамарковић, Владица В. Ђук, Јован Т. Јулоски

Клиничко-болнички центар „Звездара“, Клиника за хирургију „Никола Спасић“, Београд, Србија;  
Универзитет у Београду, Медицински факултет, Београд, Србија

### САЖЕТАК

**Увод** Лејомиосарком доње шупље вене је редак мезенхимални тумор порекла ендотелијалних глатких мишићних ћелија интима и чини око 1–2% свих саркома меких ткива. Циљ овог рада је да прикаже случај болеснице са лејомиосаркомом доње шупље вене, ресекцију тог тумора и реконструкцију закрпом *ProxiCor*.

**Приказ болесника** Приказан је случај болеснице старе 65 година, са боловима у трбуху и масом у субхепатичном простору, код које је урађена хируршка ресекција тумора,

са реконструкцијом доње шупље вене закрпом *ProxiCor*. Хистопатолошка анализа је потврдила да се ради и лејомиосакрому.

**Закључак** Наше искуство је показало да је употреба екстрацелуларног матрикса сигурна и да даје задовољавајуће резултате у лечењу. Поређење са знатно већим бројем болесника пружиће бољи увид у предности и мане овог материјала у васкуларним реконструктивним процедурама.

**Кључне речи:** доња шупља вена; лејомиосарком; *ProxiCor*