

## CASE REPORT / ПРИКАЗ БОЛЕСНИКА

# Rare ureteral injury in lumbar discectomy – two case reports

Emrah Keskin<sup>1</sup>, Altuğ Tuncel<sup>2</sup><sup>1</sup>Bülent Ecevit University, Faculty of Medicine, Department of Neurosurgery, Zonguldak, Turkey;<sup>2</sup>Bilkent University of Health Sciences, School of Medicine, Department of Urology, Ankara City Hospital, Ankara, Turkey**SUMMARY**

**Introduction** Iatrogenic ureteral injuries are an important part of all ureteral injuries. They occur primarily during urological, gynecological, vascular, and general procedures. Urethral injury during spinal surgery is a rare complication. We wanted to emphasize that there should be limitations during the use of surgical instruments used in spine surgery.

**Outlines of cases** We present ureteral injury cases that occurred in two patients with lumbar disc herniation who were treated surgically at the Department of Neurosurgery. Ureteral repair was performed in both patients by the urology department. Their postoperative course was uneventful.

**Conclusion** This report emphasizes the importance of ureteral injury complications which are rare, but can cause medicolegal problems during lumbar disc surgery. Surgeons should consider this potential complication, which has devastating consequences, particularly in patients with abdominal pain in the early postoperative period.

**Keywords:** herniated intervertebral disc; iatrogenic; surgery; ureteral injury

**INTRODUCTION**

The conventional surgical technique for lumbar disc hernias is lumbar discectomy. The main postoperative problems that may arise related to discectomy (open or percutaneous) include severe sequelae, cerebrospinal fluid (CSF) fistula, and wound-healing problems [1, 2]. Regardless of the anatomical aspect (anterior, lateral, or posterior) in the surgical approach to the spine, injury to adjacent anatomical structures may occur at varying rates. Various organ injuries, such as those of the bowel, ureter, and vascular system, have the following approaches considered as safe and widely performed by spine surgeons [3–6]. These injuries can be seen either alone or in combination [7, 8].

Ureteral injury is a rare complication of lumbar spine surgery. Since the first case of ureteral injury due to lumbar spine surgery was reported in 1954, 47 cases have been reported to date [6, 9]. In a meta-analysis, Turgut et al. [6] found that the reporting of these 47 cases was proportional to the socioeconomic development level of the countries.

Here, we present two cases of ureteral injury that occurred following lumbar disc surgery using different approaches (posterior in one, and far-lateral in the other) and discuss the levels of injury (one L5–S1 and the other L4–L5), diagnosis time, complaints, and treatments.

**CASE REPORTS****Patient 1**

A 45-year-old man presented to our Neurosurgery Clinic with the complaints of back pain, right leg pain, and walking difficulties. On physical examination, the Laségue–Lazarevic sign was positive on the right side, and the dorsiflexion muscle strength of the right foot was 2/5. Right far-lateral disc herniation at L5–S1 was detected in the lumbar magnetic resonance imaging (MRI), and he was operated on at this level using the paramedian intertransverse approach (Figure 1a, b). The back and leg pain regressed, but on postoperative day 1, he began experiencing severe abdominal pain and urgency but inability to urinate; thus, a bladder catheter was inserted. However, the abdominal pain worsened, he was unable to lie on his back, and there was swelling around the navel. On physical examination, he showed signs of abdominal guarding and rebound; thus, ultrasonography and contrast-enhanced abdominal computed tomography (CT) were undertaken. These examinations detected abdominal fluid, which was then evacuated by ultrasound-guided puncture (approximately four liters). However, the patient's complaints persisted. Over the next 15 days, weight loss (10 kg), anemia (preoperative and postoperative hemoglobin levels, 13.2 g/dL and 9.6 g/dL, respectively), elevation of kidney enzymes (blood urea nitrogen, 70 mg/dL; creatinine, 2.1 mg/dL), and elevation of liver enzymes (aspartate transaminase, 78 U/L;

**Received • Примљено:**

October 10, 2021

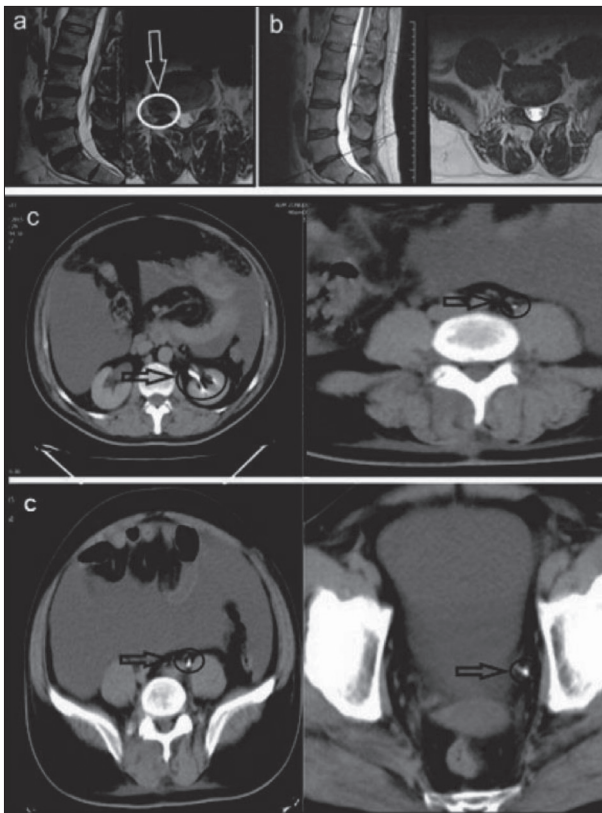
**Revised • Ревизија:**

February 5, 2023

**Accepted • Прихваћено:**

March 17, 2023

**Online first:** March 22, 2023**Correspondence to:**Emrah KESKIN  
Bülent Ecevit University  
Faculty of Medicine  
Department of Neurosurgery  
67600 Zonguldak  
Turkey  
[drkeskinemrah@gmail.com](mailto:drkeskinemrah@gmail.com)



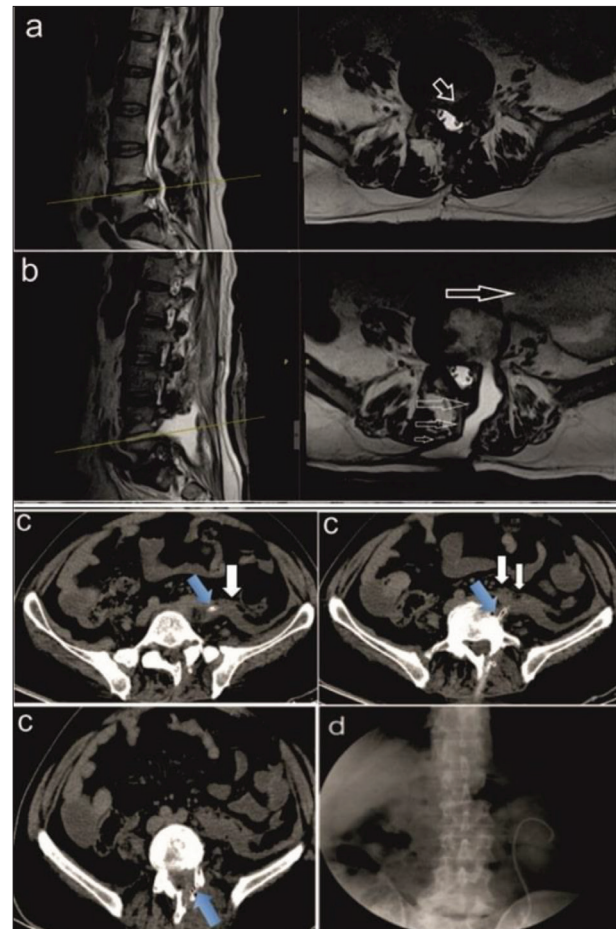
**Figure 1.** a – Preoperative magnetic resonance imaging showing L5–S1 right far-lateral disc herniation (white arrow and white circle); b – postoperative one-year control magnetic resonance imaging showing no disc; c – contrast-enhanced abdominal computed tomography performed on postoperative day one showing diffuse fluid in the abdomen and contrast enhancement in the left ureter at the edge of the psoas muscle (black arrow and black circle) but not on the side of the injury

alanine transaminase, 45 U/L) were observed. Abdominal fluid was continuously evacuated by puncture every other day (approximately one liter every time, 10 times in total). With the preliminary diagnoses of cirrhosis and stomach cancer, liver biopsy and endoscopy were performed by the gastroenterology department, which did not detect any pathologies. Following the fluid restriction, the frequency of the puncture procedure was proportionally reduced from every other day to every four days, and another contrast-enhanced CT was performed.

Contrast media extravasation was not observed on CT, but contrast enhancement was evident in the left ureter with extensive intra-abdominal fluid, whereas it was not seen in the right ureter (Figure 1c). Iatrogenic ureteral injury was considered. In addition, urine was found in the analysis of the fluid taken from the puncture. Two weeks after lumbar disc surgery, ureteral repair was performed with an end-to-end anastomosis by the urology department, which was due to the iatrogenic ureteral rupture on the right side. The patient did not have any complaints during his follow-up.

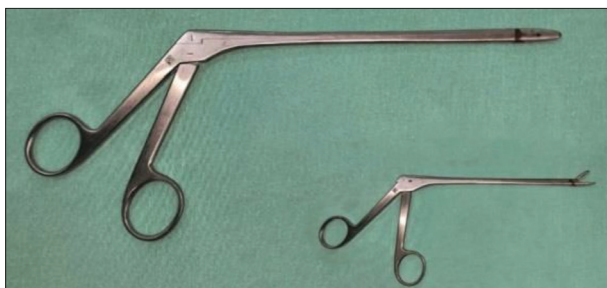## Patient 2

A 60-year-old man presented to our Neurosurgery Clinic with the complaint of lower back and left leg pain. On



**Figure 2.** a – preoperative magnetic resonance imaging showing right-sided extruded disc herniation at L4–L5 (white arrow); b – postoperative magnetic resonance imaging showing a urinary fistula (thin white arrow) extending from the urinoma sac (thick white arrow) to the disc height and further to the skin; c – postoperative computed tomography showing the drainage catheter (blue arrow) extending from the urinoma sac to the skin (white arrow); d – intravenous pyelography showing that the catheter cannot go above the disc height where the injury occurred

physical examination, left-sided Laségue–Lazarevic sign was positive, and the strengths of the tibialis anterior and extensor hallucis longus muscles of the left foot were 3/5 and 2/5, respectively. The patient was operated on for left-sided recurrent disc herniation at the L4–L5 level (Figure 2a). He recovered postoperatively and was discharged. On postoperative day 25, he presented to our clinic again with a clear color discharge from the wound site. He was operated on with the suspicion of a CSF fistula. During the operation, no dura defect was observed, but when the dura was pushed, a contralateral anterior longitudinal ligament (ALL) defect was observed. The fluid continuously flowed from the disc height where the defect was located, and approximately 1500 milliliters of clear and odorless fluid was aspirated. At this stage, a drain extending into the ALL defect was inserted (Figure 2c). After the operation, approximately 1000 milliliters of clean and odorless fluid was discharged from the drain every day for three days. Considering that the continuous amount of the drainage and amount and color were similar to the urine collected



**Figure 3.** Red line at the tip of the mouth of the straight and reverse-angled rongeur device

in the bladder bag, the drainage fluid was analyzed and confirmed to be urine.

On preoperative reassessment by MRI, a urinoma sac was found in the anterolateral neighborhood of the disc height at the edge of the psoas muscle (Figure 2b). Intravenous pyelography was later performed by the urology department, clearly showing iatrogenic ureteral injury (Figure 2d). The patient was referred to an external center for the repair of ureteral injury with end-to-end anastomosis. He did not have any complaints during his follow-up.

All procedures performed were in accordance with the ethical standards of the institutional and/or national research committee and with the 1964 Helsinki Declaration and its later amendments or comparable ethical standards. Written consent to publish all shown material was obtained from the patients.

## DISCUSSION

Instruments used in lumbar spine surgery may cause injury to retroperitoneal organs, such as the bowel, ureter, and vein, by damaging the prevertebral ligament [7, 8, 10]. Although the mechanism of this injury has not been explained in all cases reported in the literature, it most frequently occurs with the injury of ALL due to rongeur use [11]. Fomekong et al. [12] reported that ureteral injury occurred due to the use of Kirschner wire during the minimally invasive pedicle screw application.

Even in the most experienced hands, a rongeur can cause serious organ injuries at the stage of discectomy. In our opinion, two points should be considered while using this tool. The first and common mistake being the application of the tip of the rongeur in an open way, and more than the mouth of the instrument is inserted into the surgical field. The second is moving to inadvertently close the tool if the rongeur falls into the intertransverse space when withdrawing it. The first situation can be successfully controlled with experience. However, the second situation is extremely difficult to prevent, as it is a reflexive movement and dependent on personal skills. In this context, injuries may occur during the disc removal with a far-lateral approach, as in our first case, or they may occur when the rongeur accidentally falls into the intertransverse space while removing the tissues over the lamina before the discectomy stage [6].

During revision surgery, the risk of injury increases because of the adhesion of all tissues (such as the dura mater, vein, and ureter). Specifically, revisions of lumbar disc surgery performed with the anterior approach are more difficult than those performed with the posterior approach. In anterior revision surgery, ureteral catheterization is performed before the operation to minimize the risk of possible injury; however, despite these precautions, injuries have been reported [13]. In posterior surgery, ureter injury often occurs contralaterally [6, 11, 12]. Ipsilateral injury, as described in our second case, is usually rare. We attribute this to the use of a reverse-angled rongeur in this patient who underwent surgery due to recurrent disc herniation. It is relatively more possible to have full control over a straight rongeur. However, how far the tip can go when using a reverse-angled rongeur is entirely related to the surgeon's experience and satisfaction with disc removal. In recurrent lumbar disc surgery, the lateral of the disc is often approached due to the need for extra laminectomy and facetectomy. Accordingly, pushing the reverse-angled rongeur too far forward may result in the formation of ALL defects and ipsilateral ureteral injury. Therefore, rongeur-type tools should be manipulated in a controlled manner as much as possible.

To minimize organ injury in disc surgery after ureteral injury in both cases, we drew a straight red line at the end of the mouth part of the straight and reverse-angled rongeur device (Figure 3). We use this red line as a visual stopper. This line will provide a safer use of the rongeur device during training, especially in clinics that provide spinal surgery training. In this context, we recommend that companies manufacturing surgical hand tools place this line on the part of the rongeur, as we described above.

The duration of symptoms after ureteral injury varied (first 24 hours to one year) [6]. It may present with symptoms immediately after surgery, as in our first case, or as late as on postoperative day 25 in our second case. Among these symptoms, abdominal and flank pains are the most common, and hematuria, abdominal swelling, fever, and urinary fistula can be observed [6, 12]. These symptoms that can be encountered by spine surgeons, albeit rarely, may delay the diagnosis of an already rare ureteral injury. In our first case, a postoperative follow-up neurological examination should be a part of this routine after the patient who has undergone spine surgery recovers from anesthesia. In such cases, contrast-enhanced CT is recommended if ureteral injury is suspected.

A CSF fistula is a common complication during lumbar spine surgery [14]. Our second case presented to the Emergency Department with a discharge from the incision site, which may be because we did not focus on the urinoma sac in the lumbar MRI taken preoperatively to determine the formation of a CSF fistula. In both cases, in the presence of either fluid accumulation at a level that is more expected after lumbar disc surgery or a skin fistula, a fluid sample should be taken and urinalysis should be performed. In addition, contrast-enhanced CT is necessary to visualize the ruptured ureter. Finally, a urinoma incision

close to the surgical level can be seen on MRI, especially in late-stage cases.

Discussing the complaints, diagnosis, and treatment processes of iatrogenic urethral injury with these two cases would make it easier for spine surgeons to manage this

process by considering the possibility of this complication that generally has a good prognosis.

**Conflicts of interest:** None declared.

## REFERENCES

- Chen X, Chamoli U, Vargas Castillo J, Ramakrishna VAS, Diwan AD. Complication rates of different discectomy techniques for symptomatic lumbar disc herniation: a systematic review and meta-analysis. *Eur Spine J.* 2020;29(7):1752–70. [DOI: 10.1007/s00586-020-06389-5] [PMID: 32274586]
- Ahn Y. Endoscopic spine discectomy: indications and outcomes. *Int Orthop.* 2019;43(4):909–16. [DOI: 10.1007/s00264-018-04283-w] [PMID: 30612170]
- Lai CJ, Chang MY, Huang PC, Chu YC. Complete ureter avulsion causing a long defect as a complication of posterior spine fusion: a rare case treated with nonrobotic laparoscopic repair. *Res Rep Urol.* 2019;11:15–9. [DOI: 10.2147/RRU.S189259] [PMID: 30697534]
- Kwinta BM, Mysza AM, Bigaj MM, Dragan MR, Kenig J, Krzyżewski RM. Iatrogenic common iliac vessel injury during routine degenerative lumbar spine surgery: Report of 2 cases and review of literature. *World Neurosurg.* 2020;137:111–8. [DOI: 10.1016/j.wneu.2020.01.168] [PMID: 32006736]
- Sahinoglu M, Arun O, Orhan A, Nayman A, Calisir A, Böcü Y, et al. Iliac artery injury during lumbar disc hernia surgery. *World Neurosurg.* 2019;125:347–51. [DOI: 10.1016/j.wneu.2019.02.025] [PMID: 30797924]
- Turgut M, Turgut AT, Dogra VS. Iatrogenic ureteral injury as a complication of posterior or lateral lumbar spine surgery: A systematic review of the literature. *World Neurosurg.* 2020;135:280–96. [DOI: 10.1016/j.wneu.2019.12.107] [PMID: 31887462]
- Goel A, Kumar P, Bahadur R. Abdominal vascular injury during posterior lumbar discectomy, experience from three cases and review of literature. *Spine (Phila Pa 1976).* 2019;44(20):E1227–30. [DOI: 10.1097/BRS.0000000000003100] [PMID: 31095120]
- Khan M, Joyce E, Horn J, Scoville JP, Ravindra V, Menacho ST. Postoperative bowel complications after non-shunt-related neurosurgical procedures: case series and review of the literature. *Neurosurg Rev.* 2022;45(1):275–83. [DOI: 10.1007/s10143-021-01609-y] [PMID: 34297261]
- Taqi KM, Nassr MM, Al Jufaili JS, Abu-Qasida AI, Mathew J, Al-Qadhi H. Delayed diagnosis of ureteral injury following penetrating abdominal trauma: A case report and review of the literature. *Am J Case Rep.* 2017;18:1377–81. [DOI: 10.12659/ajcr.905702] [PMID: 29273706]
- Fuquan J, Gang Z, Jianlin X, Yin R. Complete ureteral necrosis after injury sustained during lumbar disc surgery: A case report. *Medicine (Baltimore).* 2020;99(33):e21727. [DOI: 10.1097/MD.00000000000021727] [PMID: 32872054]
- Akhaddar A, Alaoui M, Turgut M, Hall W. Iatrogenic vascular laceration during posterior lumbar disc surgery: a literature review. *Neurosurg Rev.* 2021;44(2):821–42. [DOI: 10.1007/s10143-020-01311-5] [PMID: 32399729]
- Fomekong E, Pierrard J, Danse E, Tombal B, Raftopoulos C. An unusual case of ureteral perforation in minimally invasive pedicle screw instrumentation: Case report and review of the literature. *World Neurosurg.* 2018;111:28–35. [DOI: 10.1016/j.wneu.2017.11.175] [PMID: 29229340]
- Huned D, Kumaran A, Lee LS, Tiwari RV. Case of flank pain from ureteral injury after lumbar laminectomy. *BMJ Case Rep.* 2021;14(4):e241170. [DOI: 10.1136/bcr-2020-241170] [PMID: 33910802]
- Banerjee C, Cross B, Rumley J, Devine J, Ritter E, Vender J. Multiple layer lumbosacral pseudomeningocele repair with bilateral paraspinous muscle flaps, and literature review. *World Neurosurg.* 2020;144:e693–e700. [DOI: 10.1016/j.wneu.2020.09.038] [PMID: 32942058]

## Ретка повреда мокраћног канала код лумбалне дискектомије – два приказа болесника

Емрах Кескин<sup>1</sup>, Алтунг Тунџел<sup>2</sup>

<sup>1</sup>Универзитет Булент Егевит, Медицински факултет, Одељење за неурохирургију, Зонгулдак, Турска;

<sup>2</sup>Универзитет здравствених наука Билкент, Медицински факултет, Одељење за урологију, Градска болница Анкара, Анкара, Турска

### САЖЕТАК

**Увод** Јатрогене повреде мокраћне цеви представљају важан део свих повреда мокраћних цеви. Јављају се углавном током уролошких, гинеколошких и општих хируршких и васкуларних захвата. Повреде мокраћне цеви током операције кичме се у литератури ретко јављају као компликација. Хтели смо да нагласимо да треба да постоје ограничења током употребе хируршких инструмената који се користе приликом операције кичме.

**Прикази болесника** Представљамо повреду мокраћног канала која се догодила у два случаја лумбалне дискус херније лечене хируршким путем на нашем Одељењу за неурохирургију. Уролози су у оба случаја извршили захват на мокраћном каналу. Постоперативни период је прошао без компликација код оба болесника.

**Закључак** У овом извештају смо нагласили важност компликација које се јављају услед повреда мокраћног канала, које су ретке и изазивају медицинске проблеме током операције лумбалног диска. Хирурзи треба да имају у виду ову могућу компликацију, која има разорне последице, посебно код болесника с боловима у абдомену у раном постоперативном периоду.

**Кључне речи:** дискус хернија; јатрогени; операција; повреда мокраћне цеви