

ORIGINAL ARTICLE / ОРИГИНАЛНИ РАД

Assessment of condylar position in asymptomatic individuals before and after neuromuscular deprogramming with a stabilization splint

Kenan Demirović¹, Elma Demirović², Vildana Džemidžić³, Enita Nakas³¹Demirović Private Practice for Orthodontics and Dentofacial Orthopedics, Sarajevo, Federation of Bosnia and Herzegovina, Bosnia and Herzegovina;²Prim. dr. Abdulah Nakas General Hospital, Emergency Department, Sarajevo, Federation of Bosnia and Herzegovina, Bosnia and Herzegovina;³University of Sarajevo, Faculty of Dentistry with Dental Clinical Center, Department of Orthodontics, Sarajevo, Federation of Bosnia and Herzegovina, Bosnia and Herzegovina**SUMMARY****Introduction/Objective** Deprogramming of the neuromuscular system with the use of stabilization splint might provide more precise evaluation of the centric relation (CR) – maximum intercuspation (MI) discrepancy.

The study aimed to evaluate the differences between the bite registrations obtained in the CR before and after the application of the stabilization splint therapy.

Methods The sample included 48 non-deprogrammed individuals without any apparent signs and symptoms of temporomandibular disorders (TMDs). The neuromuscular system was deprogrammed by employing stabilization splint therapy. A condylar displacement evaluation was performed on vertical, horizontal, and transverse planes of space, with the assistance of a condylar position indicator.**Results** The mean values of condylar displacements, which were obtained after the deprogramming of the neuromuscular system, were significantly greater than those obtained before neuromuscular deprogramming for vertical condylar displacement ($p < 0.0001$). A greater degree of condylar distraction was observed on the left side of the vertical plane before ($p < 0.01$) and after neuromuscular deprogramming ($p < 0.05$). The highest level of condylar displacement occurred in the postero-inferior direction subsequent to the muscle deprogramming.**Conclusion** It was observed that the level of average condylar displacements was significantly higher following the deprogramming of the neuromuscular system compared to that recorded before neuromuscular deprogramming using stabilization splint therapy. A more precise orthodontic diagnosis could have been obtained if the condyles were placed in a more exact CR position by muscle deprogramming.**Keywords:** centric relation; maximum intercuspation; stabilization splint; condylar displacement**INTRODUCTION**

From the perspective of condylar health, the centric relation is widely accepted as the most stable position of the condyles in the glenoid fossa [1–4]. Earlier studies concluded that the mandible in the centric relation (CR) is positioned by the elevator muscles in case no dental influences are present [1, 3, 5, 6, 7]. However, the actual condylar position is determined by the contact between the upper and the lower teeth in the maximum intercuspation (MI) position. Positions of CR and MI are rarely coincident, and small discrepancies are usually present between them. Discrepancies between the CR and MI can be evaluated at dental and condylar levels. Slides increased at the dental level should be confirmed through condylar measurement using the condylar position indicator (CPI) articulator. Significant slides might affect proper orthodontic diagnosis by changing the dentofacial features of dental malocclusions [2, 5, 7, 8]. Proffit [9] recommends mounting the orthodontic models on an articulator in case anterior slides of 2–3 mm and lateral slides of

any range exist between the MI and the CR positions at the dental level. Values of dental CR–MI discrepancies do not usually correspond to discrepancy in values obtained at the condylar level for the asymptomatic population [2, 3, 4, 10]. Therefore, the mounting of diagnostic models is recommended by several clinicians before the start of orthodontic treatment. This enables the observation of the real difference between the CR and MI [2, 3, 7, 11, 12]. Furthermore, if the positions of the CR and MI are close to each other, the possibility of temporomandibular disorders (TMDs) development is lower [6]. The stability of condyles in the CR is most commonly worsened by the presence of occlusal interferences located in the area of the posterior teeth, which might increase the CR–MI discrepancy and cause development of TMD [2, 3, 9, 11, 13]. In order to reach the most stable intercuspation position, the mandible must avoid these prematurities that lead to mandibular shifts on all three spatial planes [11]. These deviated positions of the mandible coerce the related muscles to adapt to various neuromuscular patterns of activity,

Received • Примљено:

February 27, 2022

Revised • Ревизија:

January 26, 2023

Accepted • Прихваћено:

February 21, 2023

Online first: March 8, 2023**Correspondence to:**Kenan DEMIROVIĆ
Demirović Private Practice for
Orthodontics and Dentofacial
Orthopedics
Bjelave 70
71000 Sarajevo
Federation of Bosnia and
Herzegovina
Bosnia and Herzegovina
kenandemirovic@hotmail.com

causing condylar instability [2, 3, 11]. In order to relieve the muscles of inadequate activity, neuromuscular deprogramming is required. Several researchers recommend the application of stabilization splint therapy for deprogramming of the neuromuscular system prior to the registration of the CR position [12, 14, 15]. Also, when compared to other methods, the most consistent and reproducible results of CR bite registration were obtained after deprogramming was performed with the occlusal stabilization splint [15, 16]. Ideal protocol calls for complete neuromuscular deprogramming of all subjects, with increased CR–MI discrepancy at the occlusal level (horizontal or vertical discrepancy greater than 2.0 mm between the CR and MI position), using a stabilization splint therapy before the registration of the CR position. Roth [11] suggested that even if asymptomatic individuals were deprogrammed with an occlusal splint, greater difference between CR and MI would be observed in comparison with non-deprogrammed asymptomatic individuals. Regarding the impact of the neuromuscular system on CR bite registration, it was hypothesized that asymptomatic patients could show greater condylar distraction if the neuromuscular system was deprogrammed using the stabilization splint therapy, compared to the case of absence of such deprogramming. The purpose of this study was to compare the condylar displacements between the CR and the MI positions across three planes of space, when measured before and after the deprogramming of the neuromuscular system using a stabilization splint. Additionally, the condylar positions among males and females were compared both before and after the neuromuscular deprogramming.

METHODS

A total of 48 non-deprogrammed individuals in the aged 18–30 years (24 females and 24 males), who did not show any obvious signs and symptoms of TMDs, participated in the study. The study was carried out at the Demirović Private Practice for Orthodontics and Dentofacial Orthopedics located in Sarajevo.

Exclusion criteria included history of trauma involving the temporomandibular joints, history of orthodontic treatment or orthognathic surgery, history of temporomandibular joints treatment, presence of any past major prosthetic treatments and presence of rheumatoid arthritis or other rheumatic disorders. The study protocol was approved by the Ethics Committee, Faculty of Dentistry with Dental Clinical Center, University of Sarajevo, Bosnia and Herzegovina.

All the subjects included in the study had increased CR–MI discrepancy (greater than 2 mm) in the horizontal or vertical plane, measured at the level of occlusion. Horizontal (overjet) and vertical (overbite) values were measured in the positions of MI and CR, obtained before and after the deprogramming of the neuromuscular system with stabilization splint. The measurement of these parameters was recorded to the nearest 0.1 mm with the help of a digital ruler.

Evaluation of condylar displacement between the centric relation and maximum intercuspation

Bite registration in the MI position was obtained using a single layer of extra-hard Beauty Pink Wax (Moyco Technologies Inc., Montgomeryville, PA, USA), prior to the deprogramming of the neuromuscular system. In order to register the CR position, blue bite registration wax (Delar Corp., Lake Oswego, OR, USA) was used in accordance with Roth's power-centric technique. Maxillary and mandibular diagnostic casts of all the participants were obtained before the neuromuscular deprogramming and mounted on an articulator (Panadent Corp, Colton, CA, USA) using an estimated face-bow and wax bite registered in the position of CR. The level of condylar displacement between the CR (Figure 1) and the MI (Figure 2) positions was evaluated before the neuromuscular deprogramming using initial CR and MI bite registration records. After the neuromuscular deprogramming with stabilization splint, newly obtained upper and lower diagnostic casts were mounted on an articulator using a new wax bite registered in the position of CR. The amount of condylar displacement between the CR and MI positions after the neuromuscular deprogramming was evaluated using the initial MI bite registration record, and the CR bite registration record taken after the neuromuscular deprogramming with stabilization splint.

Neuromuscular deprogramming with stabilization splint therapy

In order to find a more reliable CR position in patients with a large CR–MI discrepancy, neuromuscular system deprogramming was performed using an acrylic stabilization splint [7, 17] (Figure 3). This stabilization splint was constructed according to the principles of the mutually protected occlusion (Figure 4). All participants were instructed to wear the stabilization splints round the clock, except while eating and maintaining their oral hygiene. During each follow up, centric stops and the posterior eccentric disclusion were evaluated using 0.008 mm colored articulating paper Arti-Fol (Bausch Articulating Papers Inc., Nashua, NH, USA), and the splints were adjusted to optimum occlusal conditions for mutually protected occlusion. In order to track the condyles to a stable condylar position, centric relation records were taken every 15 days during the first two months of stabilization splint therapy and at one-week intervals during the third and/or fourth month of therapy. Stable condylar position was achieved when identical CPI values were obtained for three consecutive weeks. Neuromuscular deprogramming and stable condylar position in the fossa were obtained during the third or fourth month of splint application in all subjects. All mountings were performed on the same articulator. All the steps in this study were performed by the same trained operator. For statistical analysis, results were presented as mean \pm standard deviation and median, while the testing of differences was performed with the nonparametric Mann–Whitney U test. Analysis was performed using




Figure 1. Centric relation position in condylar position indicator instrumentation determined by bite registered in centric relation position

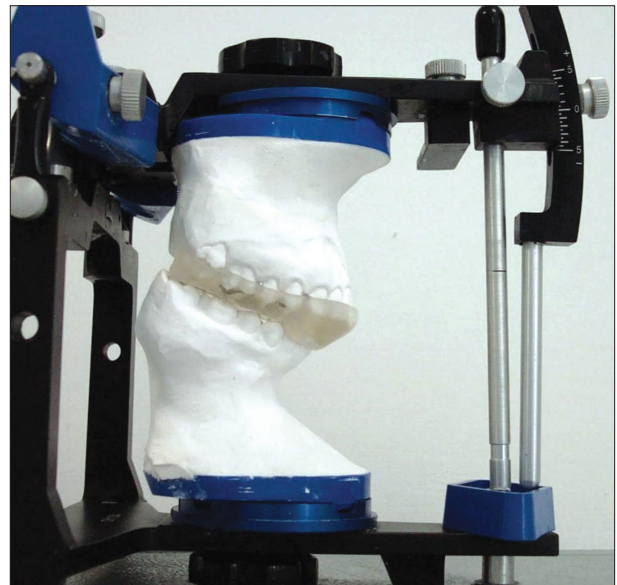


Figure 3. Acrylic stabilization splint constructed in a semi-adjustable articulator

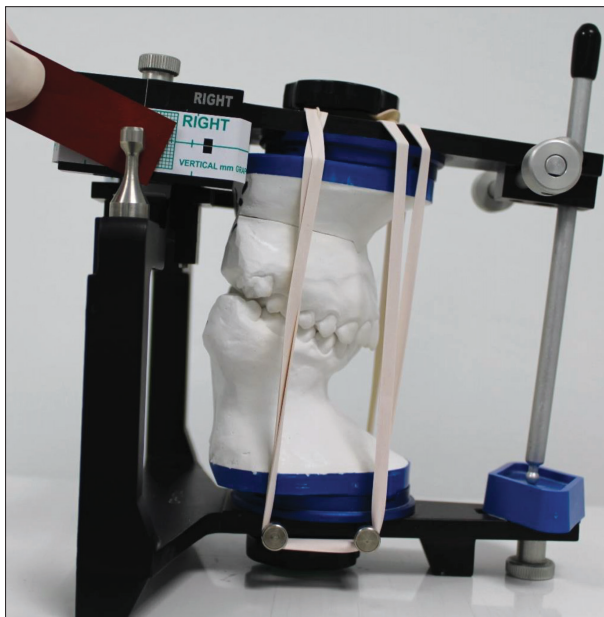


Figure 2. Maximum intercuspation position in condylar position indicator instrumentation determined by bite registered in the position of maximum intercuspation

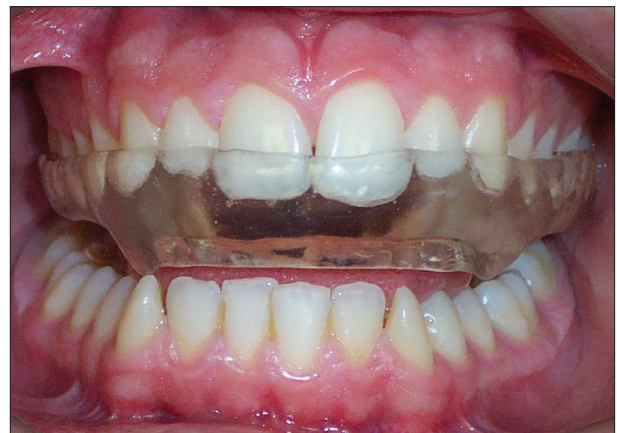

Figure 4. Occlusal scheme of the stabilization splint based on principles of mutually protected occlusion

the statistical package IBM SPSS Statistics for Windows, Version 23.0 (IBM Corp., Armonk, NY, USA).

The authors confirm that necessary patient’s written consent has been obtained.

RESULTS

The mean values of condylar displacements obtained after the deprogramming of the neuromuscular system proved to be significantly greater than those attained before neuromuscular deprogramming in the case of CPI vertical right (Vert R) ($p = 0.0001$) and CPI vertical left (Vert L) ($p = 0.0001$) but not for the CPI horizontal right (Hor R)

($p = 0.144$), CPI horizontal left (Hor L) ($p = 0.171$) and CPI transversal (Transv) ($p = 0.203$) (Table 1).

Table 1. Comparison of mean values, standard deviations and median, in mm, of vertical condylar displacement on the right (CPI Vert R) and left (CPI Vert L) side, horizontal condylar displacement on the right (CPI Hor R) and left (CPI Hor L) side, and transversal condylar displacement (CPI Transv) before (B) and after (A) neuromuscular deprogramming with stabilization splint

Parameters (mm)	n	Mean ± SD	Median	Z	p
B – CPI Vert R	48	1.54 ± 0.47	1.60	-3.532	0.0001
A – CPI Vert R	48	1.97 ± 0.69	1.80		
B – CPI Vert L	48	1.82 ± 0.54	1.80	-3.912	0.0001
A – CPI Vert L	48	2.20 ± 0.63	2.20		
B – CPI Hor R	48	-0.32 ± 0.69	-0.50	-1.460	0.144
A – CPI Hor R	48	-0.49 ± 0.92	-0.8		
B – CPI Hor L	48	-0.41 ± 0.62	-0.50	-1.368	0.171
A – CPI Hor L	48	-0.56 ± 0.85	-0.65		
B – Transv	48	0.20 ± 0.25	0.20	-1.274	0.203
A – Transv	48	0.27 ± 0.30	0.20		

CPI – condylar position indicator; Z – standard score

Table 2. Comparison of mean values, standard deviations and median, in mm, of vertical condylar displacement according to right (CPI Vert R) and left (CPI Vert L) side, and horizontal condylar displacement according to right (CPI Hor R) and left (CPI Hor L) side before (B) and after (A) neuromuscular deprogramming

Parameters (mm)	n	Mean ± SD	Median	Z	p
B – CPI Vert R	48	1.54 ± 0.47	1.60	-2.577	0.010
B – CPI Vert L	48	1.82 ± 0.54	1.80		
B – CPI Hor R	48	-0.32 ± 0.69	-0.50	-0.757	0.449
B – CPI Hor L	48	-0.41 ± 0.62	-0.50		
A – CPI Vert R	48	1.97 ± 0.69	1.80	-2.313	0.021
A – CPI Vert L	48	2.20 ± 0.63	2.20		
A – CPI Hor R	48	-0.49 ± 0.92	-0.80	-0.530	0.596
A – CPI Hor L	48	-0.56 ± 0.85	-0.65		

CPI – condylar position indicator; Z – standard score

Greater left-side inferior and posterior displacement of the condyles was observed after the neuromuscular deprogramming. These differences were statistically significant before ($p = 0.010$) and after ($p = 0.021$) in the vertical but not in the horizontal plane, neither before ($p = 0.449$) nor after (0.596) (Table 2). No statistical differences were observed between the genders (all $p > 0.05$) (Figure 5). Before neuromuscular deprogramming was performed, 70.8% of the subjects in the study had postero-inferior displacement of the condyles, 22.9% antero-inferior and 6.2% straight inferior on the left side, while on the right side, condyles were displaced postero-inferiorly in 60.4%, antero-inferiorly in 25% and straight inferiorly in 14.5% of the subjects. Evaluation of the direction of condylar displacement, after the deprogramming of the neuromuscular system, showed that 81.2% of the condyles were displaced in the postero-inferior direction and 18.7% in the antero-inferior direction on the left side. On the right side, 77.1% of the condyles were displaced in the postero-inferior direction, 20.8% in the antero-inferior direction and 2.8% in the straight inferior direction.

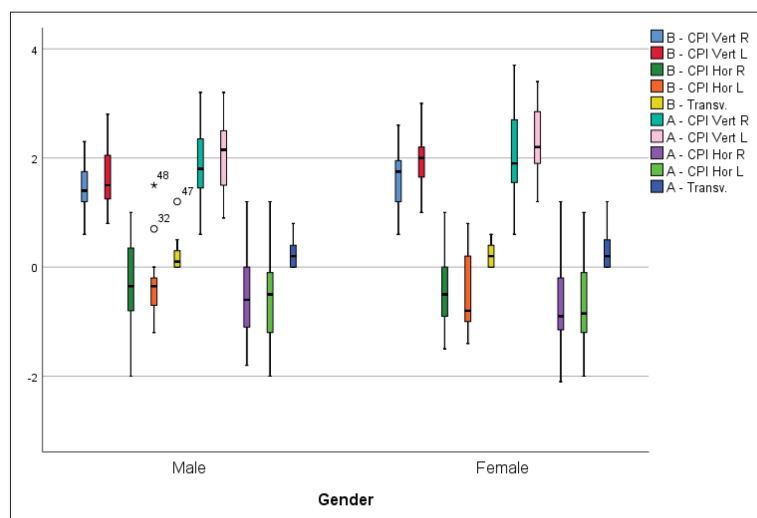


Figure 5. CPI – condylar position indicator; comparison of mean values, standard deviations and median, in mm, of vertical right (CPI Vert R) and left (CPI Vert L), horizontal (CPI Hor R) and left (CPI Hor L) and transverse (Transv) condylar displacement between genders, before (B) and after (A) neuromuscular deprogramming with stabilization splint

DISCUSSION

It is considered that mandibular stability is realized when the positions of CR and MI coincide [11]. This means that orthopedic stability is guaranteed if the musculoskeletal position of the condyles in the fossa is as much as possible harmonized with the position of the teeth in MI [6]. In the studies that evaluated CR–MI discrepancy in asymptomatic individuals using just a CPI instrumentation, significant differences between the CR and MI were found [4, 17, 18]. Previous studies indicate that asymptomatic individuals with a higher occlusal CR–MI discrepancy (greater than 2.0 mm in horizontal and vertical directions) also showed significant condylar CR and MI differences [2, 10]. Most commonly, the presence of occlusal interferences increases discrepancy between the CR and MI, thereby leading the mandible to deviated positions, indirectly causing neuromuscular reprogramming of the related muscles. Deprogramming of the neuromuscular system is needed before CR bite registration, in order to detect a true discrepancy between the CR and MI. Although Roth's power centric technique was recognized as the most reliable and reproducible technique of CR bite registration, Roth [11] himself stated that clinical mandibular manipulation is not reliable in determining condylar position because of neuromusculature. In a very recent study, authors concluded that "Dentists and dental experts are dependent not so much on the head posture but on an acceptably reproducible horizontal jaw relation in order to be able to repeatedly check the occlusion in reconstructions of the mandibular posture" [19]. In most of the earlier studies, CR bite registration was recorded without previous muscle deprogramming, although the impact of the neuromuscular system on CR registration had already been proved [3, 4, 12, 18]. In a study by Fantini et al. [7] vertical and horizontal condylar displacements in asymptomatic patients were found to be greater after neuromuscular deprogramming with the stabilization splint in comparison with the results

of previous studies, where no neuromuscular deprogramming methods were employed [12, 18]. In this study, it was hypothesized that stabilization splint therapy for approximately three months could lead to better seating of the condyles in the fossa, resulting in different CPI measurement results compared to those obtained before the deprogramming of the neuromuscular system in asymptomatic individuals. Statistically significant differences between the CR and MI were observed on the vertical plane. It was found that the mean vertical displacements on the right and left sides, obtained after the neuromuscular deprogramming, were significantly greater than those attained before the neuromuscular deprogramming (Table 1). These results are in close agreement with those derived in similar studies by Fantini et al. [7] and Yoon and Kim [17] who used identical methods. Vertical displacement of the condyles was more expressed on the left side before ($p < 0.01$) and

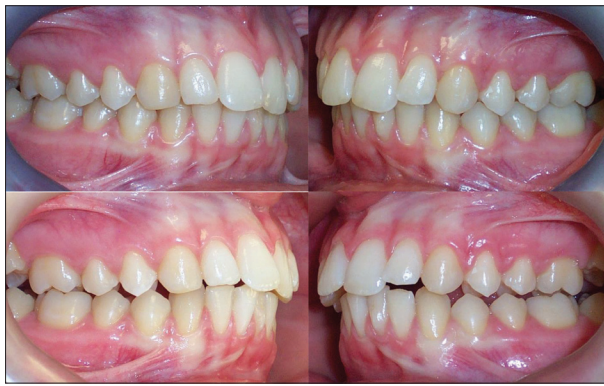

Figure 6. A – right lateral intraoral view of occlusion in maximum intercuspation before the stabilization splint therapy; B – right lateral intraoral view of occlusion after neuromuscular deprogramming with a stabilization splint; discrepancies between the upper and lower dental arch have increased in horizontal (overjet) and decreased in vertical (overbite) direction affecting the orthodontic diagnosis and plan of treatment; C – left lateral intraoral view of occlusion in maximum intercuspation before the stabilization splint therapy; D – left lateral intraoral view of occlusion after neuromuscular deprogramming with a stabilization splint; discrepancies between the upper and lower dental arch have increased in horizontal (overjet) and decreased in vertical (overbite) direction affecting the orthodontic diagnosis and plan of treatment

after ($p < 0.05$) the neuromuscular deprogramming (Table 2). On the other hand, Fantini et al. [7] found that after the neuromuscular deprogramming with the stabilization splint vertical condylar displacements were of greater magnitude on the right side. After the neuromuscular deprogramming, greater mean condylar displacements were observed on the horizontal plane too, but without statistical significance (Table 1). The condyles were displaced in postero-inferior, antero-inferior and straight inferior direction, which was corresponding with the findings of similar studies [2, 3, 11, 12, 18]. The results of this study are consistent with the findings of previous studies, confirming that the deprogramming with the stabilization splints significantly increases the amount of condylar distraction in vertical direction in asymptomatic patients [7, 17]. Also, before and after the neuromuscular deprogramming, patients showed higher mean values of condylar displacement than that it was found by other authors in non-deprogrammed asymptomatic groups [12, 18]. Statistically, no significant differences in condylar displacements were observed between males and females. In this study, it was shown that after the neuromuscular system was deprogrammed and the condyles were in a stable musculoskeletal position, the magnitude of discrepancy between the CR and MI at the level of occlusion might be significantly changed. The most common changes observed in inter-arch relations after the neuromuscular deprogramming included the following: the presence of localized occlusal interferences in premolar and molar areas, increased overjet, decreased overbite, and coincidence of transverse midlines (Figure 6 A–D), which corresponded with findings by other authors [2, 9, 5, 11, 20, 21]. These significant changes at the level of occlusion demonstrate the importance of neuromuscular deprogramming, especially from the aspect of making an accurate orthodontic diagnosis [2, 5, 7, 8, 21–25]. The use of occlusal splints for deprogramming of the neuromuscular system before orthodontic treatment is usually recommended

for patients with signs and symptoms of TMDs. Earlier investigations have demonstrated the efficacy of neuromuscular deprogramming with occlusal stabilization splint in the reduction of signs and symptoms of TMD in patients with a large CR–MI discrepancy [3, 5, 15, 26]. Padala et al. [20] and Lim et al. [22] indicated that the signs and symptoms of TMDs are more significantly expressed in individuals with large CR–MI discrepancy. The latest studies confirmed that the most common type of occlusal splint used for treatment of the patients with TMDs is occlusal stabilization splint [26–29]. A study by Crawford [3] showed how anamnestic and clinical symptomatology drastically increase as the CPI values in vertical and horizontal direction rise from 1 mm to 2 mm. Accordingly, this implies that orthodontic models of asymptomatic patients with increased slide between the CR and MI at the dental level (greater than 2 mm) need to be mounted on an articulator and measured at the condylar level. If condylar measurements detect vertical and horizontal displacements larger than 1 mm and transverse condylar displacements larger than 0.5 mm, these patients may be at potential risk of developing TMD after the orthodontic treatment [30]. In this context, the deprogramming of the neuromuscular system with a stabilization splint and the consequent placement of temporomandibular condyles in a more correct and reliable CR position within the fossa could prevent a possible TMD in asymptomatic patients who showed greater CR–MI discrepancy between maxillary and mandibular dentition. The results of this investigation demonstrated that the mounting of orthodontic models in the CR on a semi-adjustable articulator and muscle deprogramming with a stabilization splint is recommended in asymptomatic patients who show increased discrepancy between the CR and MI. Moreover, it was assumed that a more accurate orthodontic diagnosis could be obtained if these asymptomatic patients were neuromuscularly deprogrammed and analyzed in the CR position in comparison with patients diagnosed based on hand-held casts articulated in MI.

CONCLUSION

Measured on the same group of patients, greater mean condylar displacements on the vertical plane were observed after the neuromuscular system was deprogrammed in comparison with condylar displacements recorded before muscle deprogramming. The more significant vertical displacement of the condyles was present on the left side before and after neuromuscular deprogramming. It is recommended that patients without any existing signs and symptoms of TMDs but with condyles in unstable musculoskeletal position should be neuromuscularly deprogrammed prior to the commencement of orthodontic treatment. The use of stabilization splint therapy in asymptomatic patients with increased CR–MI discrepancy could prevent orthodontic misdiagnosis and possible development of TMD during or after the orthodontic treatment.

Conflicts of interest: None declared.

REFERENCES

- Kattadiyil MT, Alzaid AA, Campbell SD. The relationship between centric occlusion and the maximal intercuspal position and their use as treatment positions for complete mouth rehabilitation: Best evidence consensus statement. *J Prosthodont.* 2021;30(51):26–33. [DOI: 10.1111/jopr.13316] [PMID: 33783091]
- Cordray FE. Three-dimensional analysis of models articulated in the seated condylar position from a deprogrammed asymptomatic population: a prospective study. Part 1. *Am J Orthod Dentofacial Orthop.* 2006;129(5):619–30. [DOI: 10.1016/j.ajodo.2004.10.015] [PMID: 16679202]
- Crawford SD. Condylar axis position, as determined by the occlusion and measured by the CPI instrument, and signs and symptoms of temporomandibular dysfunction. *Angle Orthod.* 1999;69(2):103–16. [DOI: 10.1043/0003-3219(1999)069<0103:CAPADB>2.3.CO;2] [PMID: 10227550]
- Slavicek R. Clinical and instrumental functional analysis and treatment planning. Part 4. Instrumental analysis of mandibular casts using the mandibular position indicator. *J Clin Orthod.* 1988;22(9):566–75. [PMID: 3267702]
- Lee G-H, Park JH, Lee S-M, Kim E-J, Lim S-W, Moon D. An orthodontic treatment case of a TMD patient with maxillary posterior intrusion using TSADs. *Applied Sciences.* 2022;12(23):12098. [DOI: 10.3390/app122312098]
- Okeson JP. *Management of Temporomandibular Disorders and Occlusion.* 8th ed. St Louis, Mo: CV Mosby; 2020.
- Fantini SM, Paiva JB, Rino Neto J, Dominguez GC, Abrao J, Vigoritto JW. Increase of condylar displacement between centric relation and maximal habitual intercuspal position after occlusal splint therapy. *Braz Oral Res.* 2005;19(3):176–82. [DOI: 10.1590/s1806-83242005000300004] [PMID: 16308604]
- Park JH, Lee SM, Moon DN, Lee GH. Clinical application of a maximum intercuspal position-centric relation occlusion conversion of a lateral cephalogram in the treatment of orthodontic patients. *Am J Orthod Dentofac Orthop Clin Companion.* 2021;1(2):127–35. [DOI: 10.1016/j.xaor.2021.04.001]
- Proffit WR. *Contemporary Orthodontics.* St Louis, Mo: CV Mosby; 1986. p. 134.
- Cordray FE. Articulated dental cast analysis of asymptomatic and symptomatic populations. *Int J Oral Sci.* 2016;8(2):126–32. [DOI: 10.1038/ijos.2015.44] [PMID: 27357324]
- Roth RH. Functional occlusion for the orthodontist. *J Clin Orthod.* 1981a;15(1):32–51. [PMID: 6940863]
- Utt TW, Meyers CE Jr, Wierzbza TF, Hondrum SO. A three-dimensional comparison of condylar position changes between centric relation and centric occlusion using the mandibular position indicator. *Am J Orthod Dentofacial Orthop.* 1995;107(3):298–308. [DOI: 10.1016/s0889-5406(95)70146-x] [PMID: 7879763]
- Nokar S, Sadighpour L, Shirzad H, Shahrokhi Rad A, Keshvad A. Evaluation of signs, symptoms, and occlusal factors among patients with temporomandibular disorders according to Helkimo index. *Cranio.* 2019;37(6):383–8. [DOI: 10.1080/08869634.2018.1449781] [PMID: 29602287]
- Ramachandran A, Jose R, Tunkiwala A, Varma RB, M Shanmugham A, Nair PK, et al. Effect of deprogramming splint and occlusal equilibration on condylar position of TMD patients - A CBCT assessment. *Cranio.* 2021;39(4):294–302. [DOI: 10.1080/08869634.2019.1650216] [PMID: 31451061]
- Nemes B, Frank D, Puigdollers A, Martin D. Occlusal splint therapy followed by orthodontic molar intrusion as an effective treatment method to treat patients with temporomandibular disorder: A Retrospective study. *Appl Sci.* 2021;11:7249. [DOI: 10.3390/app11167249]
- Al-Moraissi EA, Farea R, Qasem KA, Al-Wadeai MS, Al-Sabahi ME, Al-Iryani GM. Effectiveness of occlusal splint therapy in the management of temporomandibular disorders: Network meta-analysis of randomized controlled trials. *Int J Oral Maxillofac Surg.* 2020;49(8):1042–56. [DOI: 10.1016/j.ijom.2020.01.004] [PMID: 31982236]
- Yoon YJ, Kim KW. The influence of stabilization splint on condylar position and craniofacial morphology. *Korea J Orthod.* 1995;25(6):675–88.
- Wood DP, Korne PH. Estimated and true hinge axis: a comparison of condylar displacements. *Angle Orthod.* 1992;62(3):167–75. [DOI: 10.1043/0003-3219(1992)062<0167:EATHAA>2.0.CO;2] [PMID: 1416235]
- Utz KH, Lückewath W, Schwarting P, Noethlich W, Buttner R, Gruner M, et al. Is there “a best” centric relation record? Centric relation records, condyle positions, and their practical significance. *Int J Prosthodont.* 2022;14(4):291–316. [DOI: 10.11607/ijp.7786] [PMID: 36484682]
- Padala S, Padmanabhan S, Chithranjan AB. Comparative evaluation of condylar position in symptomatic (TMJ dysfunction) and asymptomatic individuals. *Indian J Dent Res.* 2012;23(1):122. [DOI: 10.4103/0970-9290.99060] [PMID: 22842268]
- Oh JW, Ahn YW, Jeong SH, Ju HM, Song BS, Ok SM. Prediction of anterior open-bite development after stabilization splint treatment in patients with temporomandibular disorder. *Cranio.* 2022;40(4):324–33. [DOI: 10.1080/08869634.2020.1792220] [PMID: 32657259]
- Lim WH, Choi B, Lee JY, Ahn SJ. Dentofacial characteristics in orthodontic patients with centric relation-maximum intercuspal discrepancy. *Angle Orthod.* 2014;84(6):939–45. [DOI: 10.2319/123013-949.1] [PMID: 24673658]
- Parreiras Ferreira R, Isaias Seraidarian P, Santos Silveira G, Campolina Rebello Horta M, Martin Palomo J, Andrade I Jr. How a Discrepancy Between Centric Relation and Maximum Intercuspal Alters Cephalometric and Condylar Measurements. *Compend Contin Educ Dent.* 2020;41(4):e1–e6. [PMID: 32250125]
- Zhao M, Wang P, Wang H, Li X, Bai D, Tian Y. Diagnostic and treatment protocol for a patient with temporomandibular disorder using a stabilization splint and temporary anchorage devices. *Am J Orthod Dentofacial Orthop.* 2021;159(5):666–81. [DOI: 10.1016/j.ajodo.2020.05.015] [PMID: 33653641]
- Lee GH, Park JH, Lee SM, Moon DN. Orthodontic Treatment Protocols for Patients with Idiopathic Condylar Resorption. *J Clin Pediatr Dent.* 2019;43(4):292–303. [DOI: 10.17796/1053-4625-43.4.12] [PMID: 31094632]
- He S, Wang S, Song F, Wu S, Chen J, Chen S. Effect of the use of stabilization splint on masticatory muscle activities in TMD patients with centric relation-maximum intercuspal discrepancy and absence of anterior/lateral guidance. *Cranio.* 2021;39(5):424–32. [DOI: 10.1080/08869634.2019.1655861] [PMID: 31429383]
- Đorđević I, Todorović A, Lazić V, Obradović-Đuričić K, Milekić B, Stamenković D. Occlusal appliances – an alternative in pain treatment of temporomandibular disorders. *Srp Arh Celok Lek.* 2019;147(9–10):541–6. [DOI: 10.2298/SARH190118064D]
- Vrbanić E, Alajbeg IZ. Long-term effectiveness of occlusal splint therapy compared to placebo in patients with chronic temporomandibular disorders. *Acta Stomatol Croat.* 2019;53(3):195–206. [DOI: 10.15644/asc53/3/1] [PMID: 31749451]
- Milojević-Šamanović A, Zdravković D, Veličković S, Jovanović M, Milosavljević M. Non-invasive approach in the treatment of temporomandibular joint osteoarthritis. *Srp Arh Celok Lek.* 2021;149(1–2):97–101. [DOI: 10.2298/SARH200611079M]
- He SS, Deng X, Wamalwa P, Chen S. Correlation between centric relation-maximum intercuspal discrepancy and temporomandibular joint dysfunction. *Acta Odontol Scand.* 2010;68(6):368–76. [DOI: 10.3109/00016357.2010.517552] [PMID: 209426]

Процена кондиларне позиције код асимптоматских особа пре и после депрограмирања неуромишићног система помоћу стабилизационог спланта

Кенан Демировић¹, Елма Демировић², Вилдана Џемиџић³, Енита Накас³

¹Приватна специјалистичка ординација ортопедије вилица – ортодонције „Демировић“, Сарајево, Федерација Босне и Хрцеговине, Босна и Херцеговина;

²Општа болница „Прим. др. Абдулах Накаш“, Одељење за ургентну медицину, Сарајево, Федерација Босне и Хрцеговине, Босна и Херцеговина;

³Универзитет у Сарајеву, Стоматолошки факултет, Одељење за ортодонцију, Сарајево, Федерација Босне и Хрцеговине, Босна и Херцеговина

САЖЕТАК

Увод/Циљ Депрограмирање неуромишићног система помоћу стабилизационог спланта даје могућност добијања прецизнијих резултата мерења приликом евалуације дискрепанци између централне релације и максималне интеркуспидације.

Циљ ове студије је био да евалуирају разлике између загриза који су регистровани у положају централне релације пре и после примене терапије са стабилизационим сплнтом.

Метод Ова студија је обухватала 48 болесника (старости између 18 и 30 година) који нису били депрограмирани на неуромишићном нивоу и који нису имали очигледних знакова и симптома темпоромандибуларних поремећаја. Депрограмирање неуромишићног система је извршено помоћу терапије са стабилизационим сплнтом. Евалуација степена кондиларних одступања је извршена у вертикалној, хоризонталној и трансверзалној равни, уз помоћ индикатора положаја кондила.

Резултати Просечне вредности кондиларних одступања у вертикалној равни добијене после депрограмирања

неуромишићног система биле су значајно веће у односу на просечне кондиларне вредности добијене пре неуромишићног депрограмирања ($p < 0,0001$). Већи степен кондиларне дистракције примећен је на левој страни у вертикалној равни пре неуромишићног депрограмирања ($p < 0,01$), као и после њега ($p < 0,05$). После депрограмирања неуромишићног система највећи степен дистракције кондила забележен је у постериоинфериорном правцу.

Закључак У студији је утврђено да је ниво просечних кондиларних одступања био значајно већи после депрограмирања неуромишићног система у поређењу са нивоом кондиларних одступања забележених пре депрограмирања неуромишићног система. Постављањем кондила у правилнији положај централне релације после депрограмирања неуромишићног система повећава се могућност за постављање прецизније ортодонтске дијагнозе.

Кључне речи: централна релација; максимална интеркуспидација; стабилизациони сплнт; кондиларна одступања