



CASE REPORT / ПРИКАЗ БОЛЕСНИКА

Intraperitoneal onlay mesh laparoscopic repair of an incarcerated Spigelian hernia – case report and literature review

Vladimir Milosavljević¹, Bogdan Crnokrak^{1,2}, Aleksandar Gluhović³, Borislav Tošković^{1,2}

¹Bežanijska Kosa University Hospital Medical Center, Department for Hepato-Pancreato-Biliary Surgery, Belgrade, Serbia;

²University of Belgrade, Faculty of Medicine, Department for Surgery with Anesthesiology, Belgrade, Serbia;

³New Hospital General Hospital, Department for Surgery, Novi Sad, Serbia

SUMMARY

Introduction Spigelian hernia is a type of lateral ventral hernia, localized between the rectus abdominis muscle and the semilunar line. Current literary data indicate that the prevalence of Spigelian hernia is 1–2% of all hernias of the abdominal wall. Patients are most commonly asymptomatic.

Case outline We present a 63-year-old male patient admitted to our hospital as an emergency case due to lower abdominal pain. Upon hospital admission, radiological diagnostics, and a physical examination, the presence of a Spigelian hernia was verified, which, at the moment of the examination, was incarcerated. It was established that surgical treatment was indicated. We performed laparoscopic intraperitoneal onlay mesh plastic in the standard way. The patient was discharged from hospital on the following day with normal values of vital and laboratory parameters.

Conclusion The Spigelian hernia, although first described many years ago, remains a diagnostic challenge, which is why its occurrence requires a multidisciplinary approach for the purpose of establishing a timely and accurate diagnosis. Within the surgical treatment of this state, there are several surgical techniques, and special focus is placed on the minimally invasive surgical approach. Also, within the minimally invasive surgical approach, there are several operating techniques.

Keywords: Spigelian hernia; laparoscopy; surgery

INTRODUCTION

Spigelian hernia (SH) is a type of lateral ventral hernia, which presents as a tumefaction passing through the aponeurosis of the Spigelian fascia, localized between the rectus abdominis muscle and the semilunar line.

In literature, SH was first documented by Klinkosch in 1746. However, regardless of this first description, this hernia was named after the Flemish anatomist Adriaan van den Spiegel, who was the first to describe the semilunar line [1].

Current literary data indicate that the prevalence of SH is 1–2% of all hernias of the abdominal wall, with a higher prevalence in females. Age is a significant risk factor, which is why incidence is higher in the elderly [2, 3].

Patients with SH are most commonly asymptomatic. Rarely, they present with discomfort, abdominal pain, intestinal obstruction, etc. [4]. It is because of the abovementioned symptomatology that diagnostics regarding SH represents a challenge. In addition to a physical examination, appropriate anamnesis, abdominal ultrasound examination, especially of the anterior abdominal wall, as well as computed tomography (CT) imaging, represent an important step in establishing a timely and appropriate diagnosis.

Surgical treatment is the only curative treatment modality. Traditionally, open hernia repair

surgery is applied, and the defect is closed with or without a mesh. However, after the introduction of the minimally invasive surgical approach, views regarding the best approach have been changing over time, especially when the benefits of laparoscopic surgery are taken into account. Amongst the numerous techniques, the intraperitoneal onlay mesh (IPOM) repair laparoscopic technique has a particular place [1, 5].

The aim of our study is to present a rare case of an incarcerated SH, which was safely and efficiently resolved with a minimally invasive surgical approach, as well as to present the surgical technique applied to treat the said condition.

CASE REPORT

We present a 63-year-old male patient admitted to our hospital as an emergency case due to lower abdominal pain. The patient was in good general health without comorbidities, such as hypertension, diabetes, kidney disease, etc. He did not smoke or drink alcohol. The anamnesis showed that the patient had previously experienced similar symptoms which resolved on their own. However, this time the symptoms persisted, and the intensity of the pain gradually increased. After admission to the hospital, a physical examination was performed first,

Received • Примљено:

December 30, 2022

Revised • Ревизија:

February 5, 2023

Accepted • Прихваћено:

February 12, 2023

Online first: February 27, 2023

Correspondence to:

Borislav TOŠKOVIĆ
Department for HBP Surgery
Bežanijska Kosa University Hospital Medical Center
Dr Zorža Matea bb
11000 Belgrade, Serbia
toskeb@gmail.com

followed by an ultrasound examination of the abdomen. After the previously mentioned procedures, the presence of SH, which was incarcerated at the time of the investigation, was verified.

It was established that surgical treatment was indicated. Therefore, firstly, artificial pneumoperitoneum was created with the use of a Veress needle, in general endotracheal anesthesia. After this, a ten-millimeter-wide port was placed directly above the umbilicus, through which a camera was introduced, which was followed by the placement of a paraumbilical five-millimeter-wide working port, positioned on the left, as well as another working port, also five millimeters in diameter, positioned two centimeters above the anterior iliac spine, diagonally, in the direction of the umbilicus. After the optic instruments were introduced, a red, discolored segment of the small intestine, intensely hyperemic, as compared to the remaining part of the small intestine, was verified (Figure 1), which was the result of previous incarceration and spontaneous desincarceration that occurred at the moment when pneumoperitoneum was created.

Exploration of the abdomen was performed first, and a normal finding was noted. The vascularization of the observed red segment was not compromised, which is why, after a few minutes, it regained the same coloring and texture as the rest of the intestine. After the aforementioned steps were undertaken, the defect on the abdominal wall was first verified, after which the hernia sac was first prepared and then resected, with the use of the LigaSure dissector (Medtronic, Minneapolis, MN, USA) (Figure 2). The diameter of the defect on the abdominal wall was about 7×5 cm. The next step was introducing a composite polytetrafluoroethylene (PTFE) mesh size 14×11 cm into the abdomen via the widest port and positioning it in such a way as to cover the defect on the abdominal wall, after which it was fixed to the abdominal wall, from the inside, with the use of a tacker (Figure 3). Finally, the gas from the abdomen was released, and the surgical incisions were closed in anatomical layers.

The patient was discharged from hospital on the following day with normal values of vital and laboratory parameters. After regular follow-up visits, within the first month after surgery, the patient returned to normal everyday activities, without any limitations.

All procedures performed involving human participants were in accordance with the ethical standards of the institutional and national research committee and with the 1964 Helsinki declaration and its later amendments and comparable ethical standards.

DISCUSSION

SH itself is an uncommon occurrence, while it is safe to say that an incarcerated SH is a true rarity. The hernia sac usually encompasses the omentum, a segment of the small intestine, or the appendix [6, 7, 8].

In the case of our patient, a segment of the small intestine was incarcerated, which was found within the hernia sac.

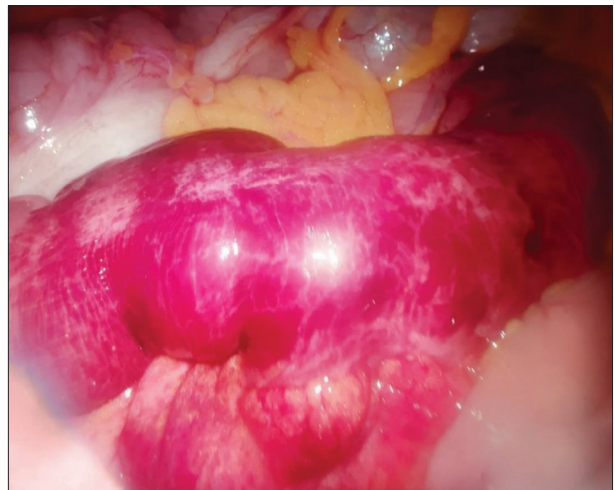

Figure 1. Intraoperative view of the segment of the small intestine that was in the hernial sac

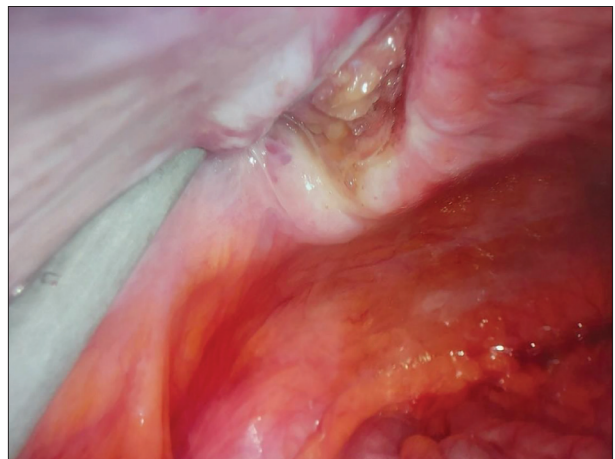


Figure 2. Intraoperative view of the hernial defect after resection of the hernial sac

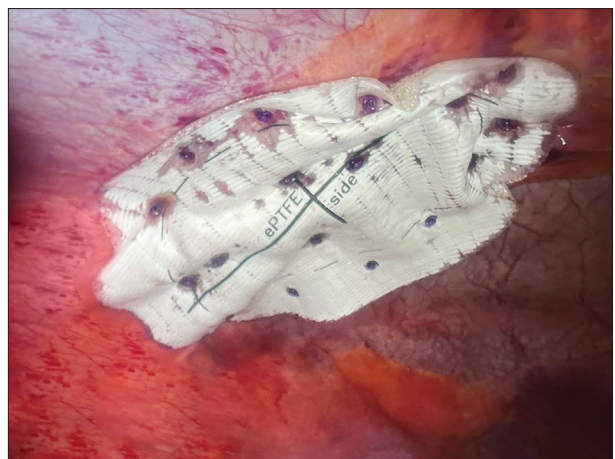


Figure 3. Intraoperative view of the placed and fixed composite mesh

The diagnosis of SH is a challenge, both surgically and radiologically. In our patient's case, we established a diagnosis based on a physical examination, which revealed a tumefaction in the region of the semilunar line. After this, an abdominal ultrasound examination was performed, which confirmed a defect of the anterior abdominal wall located in that particular site.

In patients with pronounced symptoms and in whom SH is suspected, some authors propose performing an abdominal CT scan as a diagnostic method very useful in establishing the definitive diagnosis [9, 10].

Most authors propose surgical treatment of SH, since, according to data from current literature, there is the possibility of the occurrence of incarceration and strangulation of the hernia. Specifically – incarceration occurs in 24–27% of the cases, while strangulation occurs in 2–14% of the cases [5, 9].

The first laparoscopic hernia reparation was performed and documented in literature by Carter and Mizes, in 1992. There are several laparoscopic techniques applied in the treatment of SH, with different benefits. Namely, the IPOM is considered to be the most popular approach (39.2%), followed by transabdominal preperitoneal patch plasty (TAPP) (26.1%), total extraperitoneal patch plasty (TEP) (19%), and the laparoscopic suturing technique (8.3%) [11].

In our case report, we present the application of the laparoscopic IPOM technique in the treatment of SH. We chose the mentioned technique primarily because of its safety, efficiency, and ease of application. Considering the previously mentioned size of the abdominal wall defect, we opted not to suture the SH defect before mesh placement. There was no need for additional fixation of the mesh to the abdominal wall.

In the current literature, there are opinions that the defect of the abdominal wall in SH should not be closed with

sutures, before placing the mesh, especially when it comes to PTFE mesh. In cases where the defect of the abdominal wall is up to 3 cm, a suture defect can be applied before placing the mesh, i.e. the IPOM-plus technique. According to the results of Moreno et al. [12], in emergency cases like the one we presented in our work, priority should be given to the IPOM and TAPP approach, because an examination of the abdominal cavity can be performed, and therefore an adequate decision on further surgical steps can be made [13].

Also, a review of current literature, in both English and Serbian, did not reveal a report on any cases or series of cases, in Serbia, documenting the treatment of an incarcerated SH with the minimally invasive surgical approach.

SH, although first described many years ago, remains a diagnostic challenge, which is why its occurrence requires a multidisciplinary approach for the purpose of establishing a timely and accurate diagnosis. Within the surgical treatment of this state, there are several surgical techniques, and special focus is placed on the minimally invasive surgical approach. Also, within the minimally invasive surgical approach, there are several operating techniques, amongst which the IPOM approach, due to its simplicity, safety, and efficiency, represents one of the most commonly applied procedures, with all its benefits.

Conflict of interest: None declared.

REFERENCES

- Barnes TG, McWhinnie DL. Laparoscopic Spigelian Hernia Repair: A Systematic Review. *Surg Laparosc Endosc Percutan Tech.* 2016;26(4):265–70. [DOI: 10.1097/SLE.0000000000000286] [PMID: 27438174]
- Mederos R, Lamas JR, Alvarado J, Matos M, Padron I, Ramos A. Laparoscopic diagnosis and repair of Spigelian hernia: A case report and literature review. *Int J Surg Case Rep.* 2017;31:184–7. [DOI: 10.1016/j.ijscr.2017.01.043] [PMID: 28167457]
- Leone PJ, Girotra M. Incarcerated Spigelian Hernia. *Clin Gastroenterol Hepatol.* 2020;18(3):e34. [DOI: 10.1016/j.cgh.2018.11.015] [PMID: 30453091]
- Azar SF, Jamadar DA, Wasnik AP, O'Rourke RW, Caoili EM, Gandikota G. MDCT imaging in Spigelian hernia, clinical, and surgical implications. *Clin Imaging.* 2021;74:131–8. [DOI: 10.1016/j.clinimag.2020.12.031] [PMID: 33493970]
- Zacharoulis D, Sioka E. Laparoscopic Spigelian Hernia Repair: Intraoperative Onlay Mesh-Plus Technique-Video Presentation. *J Laparoendosc Adv Surg Tech A.* 2018;28(2):201–3. [DOI: 10.1089/lap.2017.0009] [PMID: 28445099]
- Lavin A, Gupta A, Lopez-Viego M, Buicko JL. Incarcerated Spigelian Hernias: A Rare Cause of a High-grade Small Bowel Obstruction. *Cureus.* 2020;24(12(3):e7397. [DOI: 10.7759/cureus.7397] [PMID: 32337123]
- Carbonell-Morote S, Maturana-Ibañez V, Zamora-Soler JA, Barreras-Mateos JA, Ramia JM. Incarcerated Spigelian hernia containing the gangrenous gallbladder. *ANZ J Surg.* 2022;92(10):2704–5. [DOI: 10.1111/ans.17499] [PMID: 35107872]
- Beroukhim G, Hosier H, Cho Y. Spigelian Hernia with Small Bowel Obstruction: Lateral Port Site Complication from Laparoscopic Gynecologic Surgery. *J Minim Invasive Gynecol.* 2022;29(3):334–5. [DOI: 10.1016/j.jmig.2021.11.010] [PMID: 34808383]
- Rankin A, Kostusiak M, Sokker A. Spigelian Hernia: Case Series and Review of the Literature. *Visc Med.* 2019;35(2):133–6. [DOI: 10.1159/000494280] [PMID: 31192247]
- Hanzalova I, Schäfer M, Demartines N, Clerc D. Spigelian hernia: current approaches to surgical treatment-a review. *Hernia.* 2022;26(6):1427–33. [DOI: 10.1007/s10029-021-02511-8] [PMID: 34665343]
- Barnes TG, McWhinnie DL. Laparoscopic Spigelian Hernia Repair: A Systematic Review. *Surg Laparosc Endosc Percutan Tech.* 2016;26(4):265–70. [DOI: 10.1097/SLE.0000000000000286] [PMID: 27438174]
- Moreno-Egea A, Campillo-Soto Á, Morales-Cuenca G. Which should be the gold standard laparoscopic technique for handling Spigelian hernias? *Surg Endosc.* 2015;29(4):856–62. [DOI: 10.1007/s00464-014-3738-9] [PMID: 25060686]
- Haji Rahman R, Punjwani A, Notario-Ringwald J, Taneja S, Fahim S, Varghese R, et al. Non-strangulated Spigelian Hernia: A Case Report. *Cureus.* 2022;14(8):e27699. [DOI: 10.7759/cureus.27699] [PMID: 36081961]

Лапароскопска техника интраперитонеално положене мрежице у лечењу уклештене Спигелове киле – приказ болесника и преглед литературе

Владимир Милосављевић¹, Богдан Црнокрак^{1,2}, Александар Глуховић³, Борислав Тошковић^{1,2}

¹Клиничко-болнички центар „Бежанијска коса“, Одељење за хепато-билио-панкреатичну хирургију, Београд, Србија;

²Универзитет у Београду, Медицински факултет, Катедра за хирургију са анестезиологијом, Београд, Србија;

³Општа болница *New Hospital*, Одељење за хирургију, Нови Сад, Србија

САЖЕТАК

Увод Спигелова кила је врста латералне вентралне киле, која је локализована између мишића *rectus abdominis* и семилунарне линије. Актуелни литерарни подаци указују да је инциденца Спигелове киле између 1% и 2% свих кила трбушног зида. Болесници најчешће немају симптоме.

Приказ болесника Представљамо болесника старог 63 године, који је хитно примљен у нашу болницу због болова у доњем делу трбуха. Приликом пријема у болницу, радио-лошке дијагностике и физикалног прегледа, констатовано је присуство Спигелове киле, која је у тренутку прегледа била уклештена. Постављена је индикација за хируршко лечење. Урадили смо лапароскопску пластику интраперитонеално

положене мрежице на стандардни начин. Болесник је наредног дана отпуштен из болнице са уредним виталним и лабораторијским параметрима.

Закључак Спигелова кила, иако је први пут описана пре много година, остаје дијагностички изазов, због чега њена појава захтева мултидисциплинарни приступ у циљу постављања правовремене и тачне дијагнозе. У оквиру хируршког лечења овог стања постоји неколико хируршких техника, а посебан фокус је на минимално инвазивном хируршком приступу. Такође, у оквиру минимално инвазивног хируршког приступа постоји неколико оперативних техника.

Кључне речи: Спигелова кила; лапароскопија; хирургија