

ORIGINAL ARTICLE / ОРИГИНАЛНИ РАД

Concentrated triamcinolone acetonide suprachoroidally administered for the treatment of diabetic macular oedema

Nenad Petrović^{1,2}, Dušan Todorović^{1,2}, Sunčica Srećković^{1,2}, Mihailo Jovanović³,
Tatjana Šarenac-Vulović^{1,2}

¹University of Kragujevac, Faculty of Medical Sciences, Department of Ophthalmology, Kragujevac, Serbia;

²Kragujevac Clinical Centre, Clinic of Ophthalmology, Kragujevac, Serbia;

³University of Kragujevac, Faculty of Medical Sciences, Kragujevac, Serbia



SUMMARY

Introduction/Objective Diabetic macular oedema is the accumulation of fluid in the macular tissue leading to its thickening. The aim of the study was to evaluate the efficacy of concentrated triamcinolone acetonide 10 mg / 0.1 ml injection into the suprachoroidal space in patients with diabetic macular oedema and decreased visual acuity.

Methods In 12 eyes with diabetic macular oedema, without any prior treatment, using a small-diameter 26G needle, an injection of 10 mg / 0.1 ml triamcinolone acetonide was applied into the suprachoroidal space in the superotemporal quadrant of the eye 4 mm from the limbus. Prior to the injection, as well as one, three, six, nine, and 12 months after the injection, visual acuity and intraocular pressure were measured, and central subfield thickness was recorded using optical coherence tomography.

Results After one, three, six, and nine post-injection months there was a statistically significant reduction in central subfield thickness (315.92 μ m, 257.66 μ m, 281.08 μ m and 295.51 μ m, respectively) compared to the baseline of 447.67 μ m. At the end of the 12th month an increase in central subfield thickness was observed again (392.16 μ m). Visual acuity improved significantly from the baseline (0.32) during the first three months (0.61) and remained stable until the end of the ninth month (0.51), but at the end of 12 months it decreased again (0.39). No significant intraocular pressure elevation and cataract development were observed in either eye during the entire follow-up period.

Conclusion A single dose of 10 mg / 0.1 ml triamcinolone acetonide injected in suprachoroidal space can significantly stabilize diabetic macular oedema and maintain satisfactory visual acuity for up to nine months.

Keywords: diabetic macular oedema; triamcinolone acetonide; suprachoroidal injection

INTRODUCTION

In patients with diabetes mellitus, especially in type 2, the visual loss is mainly caused by the development of diabetic macular oedema (DMO). Nowadays, anti-vascular endothelial growth factor (anti-VEGF) agents, intravitreally applied, are the most effective treatment for DMO, especially for the eyes in which the central part of the macula is affected by oedema [1]. The time-limited effect of these drugs, the need for frequent repeated intravitreal injections, as well as possible adverse events related to the intravitreal application itself make it difficult to maintain such treatment for a long period of time.

Numerous inflammatory mediators have been implemented in the development of diabetic retinopathy, so it can be considered a form of chronic inflammation [2]. For this reason, corticosteroids are important drugs for the treatment of DMO patients, but mostly as a second-line option. Intravitreal injection of triamcinolone acetonide (TA) has been shown to be very effective in reducing DMO and improving visual acuity (VA); however, its use

has also been associated with frequent adverse ocular effects, such as the increased intraocular pressure (IOP) and cataract progression [3, 4].

In order to achieve higher therapeutic doses in the target layers of the eye, i.e., in the retina, retinal pigment epithelium, and choriocapillaris, administration of drugs in the suprachoroidal space (SCS) may represent a new path of their application. The SCS is a virtual potential space between the choroid and sclera that may expand and become real in various pathological conditions such as suprachoroidal hemorrhage, choroidal detachment, and uveal effusion syndrome, but also by applying therapeutic fluids or suspensions to it. The animal studies have shown that SCS expansion is volume-dependent; larger volumes lead to greater expansion of this space. Also, these studies have shown that this space can receive up to 1 ml of fluid, which is a much larger volume than the volume needed to achieve the therapeutic level of common drugs that are used for the treatment of retinal diseases [5].

Suprachoroidal injection of TA represents a relatively new approach for the treatment of various retinal diseases. Numerous pre-clinical

Received • Примљено:

October 16, 2021

Revised • Ревизија:

March 22, 2023

Accepted • Прихваћено:

March 29, 2023

Online first: May 15, 2023

Correspondence to:

Dusan TODOROVIĆ
University of Kragujevac
Faculty of Medical Sciences
Department of Ophthalmology
Svetozara Markovića 69
34000 Kragujevac, Serbia
drdusantodorovic@yahoo.com

and clinical trials have confirmed the high efficacy of TA used in this way in the treatment of DMO and macular oedema in retinal vein occlusion and noninfectious uveitis [6–9]. It has been noted that the concentration of TA in the posterior eye tissues is 10 times higher than in the anterior segment of the eye, so the occurrence of side effects such as cataracts and IOP elevation is significantly lower [10]. Pharmacokinetic studies have confirmed a longer duration of activity of TA applied in this way to macular oedema and a longer stabilization of VA, which requires their less frequent application.

The SCS injection can be performed by using the standard small-gauge needles (26G, 27G) or specially designed micro needles (30G) and in both cases these needles penetrate through the sclera only 1 mm in length reaching the SCS [11]. In that way, the risk of injury to intraocular structures, retinal tear, retinal detachment, vitreous hemorrhage, and endophthalmitis, is much lower compared to intravitreal injections since the needle does not penetrate through the retina and vitreous cavity.

So far, several studies have mainly examined the efficacy and safety of suprachoroidal application of 4 mg / 0.1 ml TA in the treatment of DMO [9]. Our study evaluated the efficacy and length of therapeutic effect of concentrated 10 mg / 0.1 ml TA injected into the SCS on DMO, VA, IOP, cataract development, as well as the safety profile of this treatment.

METHODS

The study was conducted at the Clinic of Ophthalmology, University Clinical Center of Kragujevac, Serbia, in a period from June 2020 to August 2021. This was a prospective, observational, interventional, non-randomized follow-up study of 12 diabetic patients with clinically significant DMO and consequently decreased VA. This study was approved by the Medical Ethics Committee of the Kragujevac University Clinical Center. The technique, purpose, possible complications of the procedure were explained to all the patients included in the study, who were also informed about the fact that it is an off-label use of TA. After that, at the beginning of the investigation, the written informed consent from all patients was obtained.

The main inclusion criterion was the presence of clinically significant macular oedema (CSMO). It is defined by one or more statements: retinal thickening in the area within 500 μm from the center of the fovea; hard exudates in the area within 500 μm from the fovea combined with adjacent retinal thickening; retinal thickening size of one optic disc diameter (1500 μm) which is at least in part within the one disc diameter from the foveal center [12]. CSMO is confirmed by the biomicroscopic fundus examination, fluorescein angiography, and optical coherence tomography (OCT) scan, with a concomitant decrease in VA ≤ 0.5 Snellen lines. The study included only eyes that had not previously undergone any laser treatment or intravitreal application of anti-VEGF drugs. Only the eyes with transparent ocular media were included in this study.

Eyes with glaucoma, pre-existing other ocular diseases or previous ocular surgery were excluded.

Full ophthalmologic examination, including VA measurement, IOP measurement, biomicroscopy of ocular media, fundus biomicroscopy with Goldmann three-mirror contact lens and Volk 78 lenses and spectral domain OCT (SD-OCT) scanning was performed in all the patients before suprachoroidal injection of TA and at each follow-up examination after one, six, nine, and 12 months. On the first post-injection day, only a biomicroscopic examination of the anterior ocular segment and measurement of IOP were performed, while during the subsequent control examinations complete ophthalmological examinations were performed as described above. It was decided that anti-glaucoma drugs should be prescribed only in the case of an IOP increase by more than 5 mmHg compared to pre-injection values. A fixed combination of dorzolamide hydrochloride-timolol maleate (Cosopt, MSD, Haarlem, The Netherlands) was chosen as the initial antiglaucoma-tous drug.

All the analyzed eyes had CSMO, confirmed and documented by fundus photography and fluorescein angiography (Carl Zeiss, Meditec, Inc., Dublin, CA, USA). SD-OCT examination was performed before the SCS TA injection and then after one, six, nine, and 12 months using SD-OCT (Optopol REVO NX 130 SD OCT, OPTOPOL Technology, Zawiercie, Poland). The central subfield thickness (CST) was measured and as its thickening ≥ 305 μm for males and ≥ 290 μm for females was considered pathological according to the OCT 3 definition [13].

Suprachoroidal injection of TA was performed in the operating room in sterile conditions, under local anesthesia. For TA injection, preservative-free 40 mg / 1 ml Kenalog was used (Kenalog, Bristol Myers Squibb, Athens, Greece). Since 0.1 ml of the original Kenalog solution contains 4 mg of triamcinolone, in order to achieve a higher concentration of the drug, we applied the technique of triple sedimentation, described by Jonas et al. [3]. The entire volume of the 1 ml Kenalog bottle was aspirated into a 1-ml tuberculin syringe. The syringe was vertically positioned on the operating table for at least 15 minutes, because of sedimentation. Then, upper 0.8 ml were eliminated out of the syringe and only the 0.2 ml sedimentary part of the crystal was left in the syringe. Ringer's solution was used to refill the 1 ml syringe, and then the syringe was repositioned in the vertical position for 5 minutes for additional sedimentation. This procedure of removing upper 0.8 ml of the suspension, refilling with Ringer's solution and re-sedimenting was repeated twice. In the end, upper 0.9 ml was eliminated out of the syringe while the remaining 0.1 ml, containing about 10 mg of TA, was injected into the SCS.

For suprachoroidal TA injection we used a standard 1-ml tuberculin syringe with a 26G needle, 0.45 mm in diameter and 12 mm in length (Chirana, Stara Tura, Slovakia). In order to ensure adequate penetration into the SPC, the preparation of this needle was performed as follows. The needle was passed through the lumen of the plastic sheath of the intravenous cannula 24G with an outer

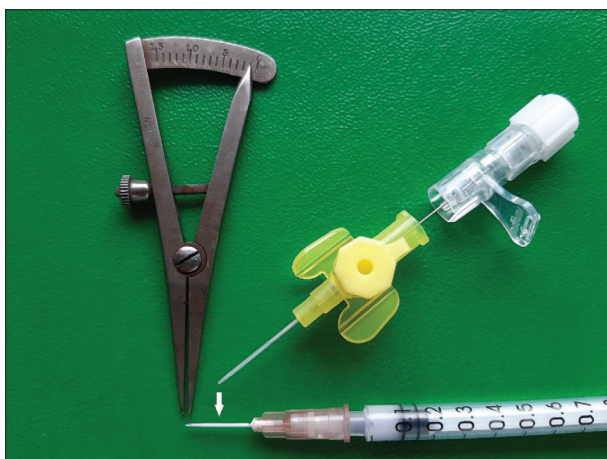

Figure 1. The preparation of small-gauge needles (26G) for suprachoroidal injection

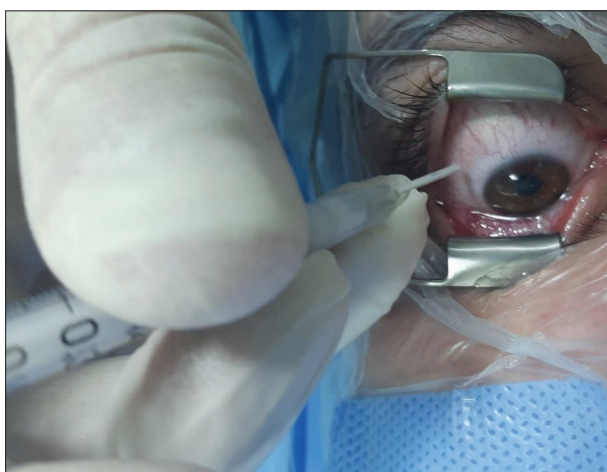

Figure 2. The suprachoroidal space application of 10 mg / 0.1 ml triamcinolone acetonide in the superotemporal quadrant 4 mm from the limbus

diameter of 0.7 mm (B Braun, Melsungen, Germany). This plastic sheath of the branula was cut to an approximate length of 11 mm so that only the tip of the needle up to the bevelled edge was exposed, only 0.9–1 mm. Thus, only the terminal tip of the needle was available for manipulation, which was only long enough to penetrate through the scleral thickness and reach the SPC. All these measurements were performed using a sterile caliper. Figure

1 shows the preparation of a small-gauge needle (26G) for suprachoroidal injection.

Before the intervention, the eye was cleaned with a solution of 5% povidone iodine. In the inferotemporal quadrant, 1% lidocaine was injected subconjunctivally. The lid speculum was placed and patients were instructed to look down and toward their nose. In the superotemporal quadrant, a distance of 4 mm from the limbus was measured with a caliper and injection of TA was applied at that point. The needle was inserted perpendicular to the sclera wherein the bevel of the needle was pointed to the opposite side of the limbus towards the posterior part of the eyeball. In this way, the diffusion of the drug posteriorly to the macular area is ensured. The TA suspension was injected slowly and during the entire time of administration, it was checked whether there was any backflow from the injection site. If this was observed, additional pressure was applied with the needle to create a small hole in the sclera to ensure sufficient penetration through the scleral thickness. After the injection is completed, the tip of the needle is slowly pulled out of the injection site that is gently pressed with a cotton swab to prevent spillage of the suspension. Figure 2 shows the SCS application of 10 mg / 0.1 ml TA in the superotemporal quadrant 4 mm from the limbus. Immediately after the intervention, the presence of cortisone crystals in the vitreal cavity was checked with an indirect ophthalmoscope, which would indicate an accidental unplanned intravitreal placement of TA. At the end of the procedure, tobramycin 0.3%-dexamethasone 0.1% ointment was instilled. Ofloxacin 0.3% drops were applied topically five times a day as the prophylactic treatment for five days.

In analyzing statistical data, IBM SPSS Statistics, Version 22.0 (IBM Corp., Armonk, NY, USA) was used. The Kruskal–Wallis test was used for testing the changes in macular thickness and VA during the follow-up period. The value of $p < 0.05$ was considered to be statistically significant.

RESULTS

The current study included 12 eyes of 12 diabetic patients. Seven (58.3%) patients were female and five (41.7%) were

Table 1. The mean values of central subfield thickness, visual acuity, and intraocular pressure before suprachoroidal space injection of 10 mg / 0.1 ml triamcinolone acetonide and during the follow-up period after one, three, six, nine, and 12 post-injection months

| Parameter | Baseline | > 1 month | > 3 months | > 6 months | > 9 months | > 12 months |
|-------------------|----------------------------------|---------------------------------|---------------------------------|---------------------------------|---------------------------------|---------------------------------|
| CST μm | 447.67 \pm 117.48 (315–802) | 315.92 \pm 45.49 (301–452) | 257.66 \pm 46.79 (241–403) | 281.08 \pm 43.11 (264–438) | 295.51 \pm 38.62 (265–452) | 392.16 \pm 57.27 (307–547) |
| p | – | 0.017* | 0.000* | 0.005* | 0.012* | 0.058 |
| VA (Snellen) | 0.32 \pm 0.15 (0.08–0.4) | 0.49 \pm 0.27 (0.2–0.7) | 0.61 \pm 0.28 (0.3–0.8) | 0.56 \pm 0.25 (0.3–0.7) | 0.51 \pm 0.2 (0.2–0.6) | 0.37 \pm 0.19 (0.1–0.5) |
| p | – | 0.017* | 0.000* | 0.011* | 0.019* | 0.055 |
| IOP mmHg | 15.67 \pm 2.25 (12–20) | 19.42 \pm 2.64 (15–22) | 18.08 \pm 2.05 (15–21) | 17.08 \pm 2.02 (14–21) | 16.42 \pm 1.68 (14–21) | 15.92 \pm 1.97 (14–20) |
| p | – | 0.048* | 0.085 | 0.132 | 0.256 | 0.423 |

CST – central subfield thickness, VA – visual acuity, IOP – intraocular pressure;
p – values compared to baseline
*statistical significance

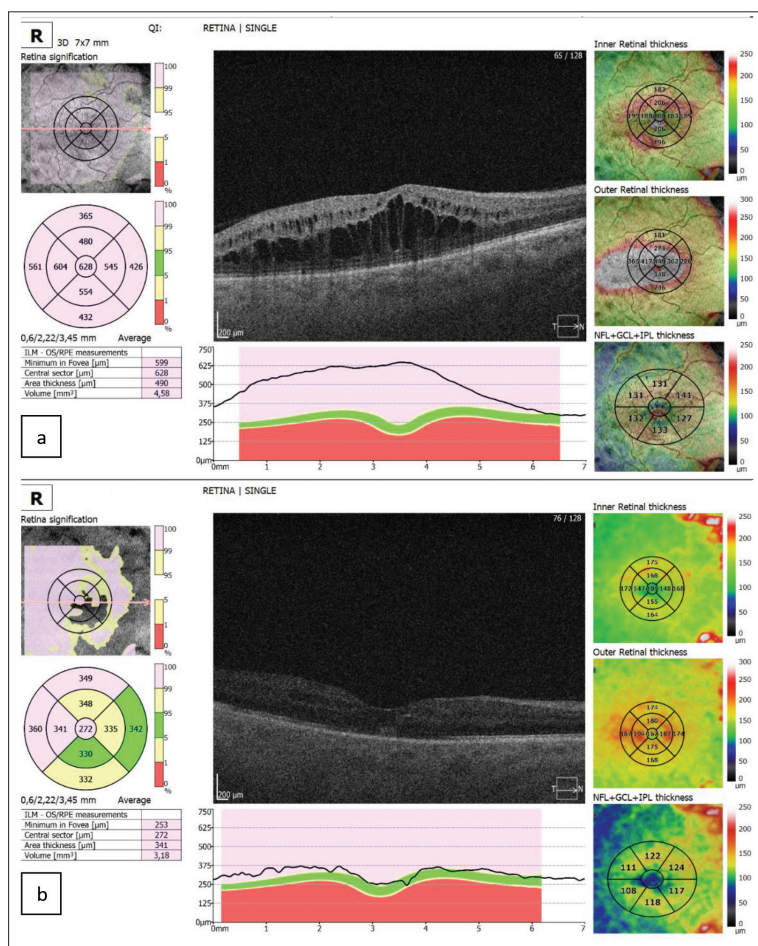


Figure 3. a – Clinically significant macular oedema with very increased central subfield thickness (628 µm) before suprachoroidal space injection; b – significant resolution of oedema in the central foveal zone (272 µm) even six months after injection

male. The mean age of patients was 65.42 ± 5.82 years (53–73 years) and all had type 2 diabetes mellitus. The average duration of diabetes mellitus in the examined patients was 17.42 ± 2.87 years. CSMO which involves central subfield of macula was confirmed in the right eye in seven and in the left eye in five patients. All examined eyes were phakic without or with very incipient cataract. In all the eyes, the initial value of IOP was lower than 22 mmHg. No laser treatment or intravitreal administration of anti-VEGF agents were performed in any of the examined eyes until the moment of SCS injection of TA.

Table 1 shows the mean values of CST, VA, and IOP before SCS injection of 10 mg / 0.1 ml TA and during the follow-up period after one, three, six, nine, and 12 post-injection months.

The mean pre-injection value of CST was 447.67 ± 117.48 µm (321–696 µm), the average VA was 0.32 ± 0.15 (0.08–0.5), and the mean IOP was 15.67 ± 2.35 mmHg (12–20 mmHg).

OCT measurements at the end of the first post-injection month showed a statistically significant reduction in CST 315.92 ± 45.49 µm compared to pre-injection values of 447.67 ± 117.48 µm ($p = 0.017$). CST was especially statistically reduced at the end of the third post-injection month

compared to baseline (257.66 ± 46.79 µm, $p = 0.000$), and remained stable at the end of the sixth (281.08 ± 43.11 µm, $p < 0.001$) and ninth month (295.51 ± 38.62 µm, $p = 0.012$). Figure 3a shows CSMO with very increased CST (628 µm) before the SCS injection, while Figure 3b shows the significant resolution of oedema in the central foveal zone (272 µm) even six months after the injection. At the end of the 12th month, an increase in the CST was observed (392.16 ± 57.27 µm), and no longer differed statistically from the initial thickness ($p = 0.058$).

VA improved significantly at the end of the first month in relation to the initial values (0.49 ± 0.27 , $p = 0.018$), and at the end of the third post-injection month this difference was the most pronounced (0.61 ± 0.28 , $p = 0.000$). During the sixth and ninth month, VA remained stable (0.56 ± 0.25 , $p = 0.011$; 0.51 ± 0.20 , $p = 0.019$), but at the end of the monitoring period, its decrease was noticed and there was no longer a significant difference from baseline (0.39 ± 0.19 , $p = 0.055$).

At the end of the first post-injection month, a moderate statistically significant increase in IOP in relation to the initial values was observed (19.42 ± 2.64 mmHg, $p = 0.048$), but neither eye required the use of anti-glaucoma therapy. During the entire remaining follow-up period there was no significant difference in the level of IOP compared to baseline (after three months 18.08 ± 2.05 mmHg, $p = 0.085$; after six months 17.08 ± 2.02 mmHg, $p = 0.132$; after nine months 16.42 ± 1.68 mmHg, $p = 0.256$; after 12 months 15.92 ± 1.97 mmHg, $p = 0.423$).

No significant cataract development occurred in either eye during the follow-up period. The subconjunctival hemorrhage at the injection site is the only side effect during this intervention and was observed in five eyes. Three patients felt mild pain during the injection, most likely due to expansion of the SCS. Immediately after the given injection, by indirect ophthalmoscopy, we did not notice in any of the eyes inadvertently intravitreal penetration of TA and subretinal or choroidal hemorrhages, but in two eyes dilation of vascular vessels at the injection site was observed. In our study, during the follow-up period, no eye had choroidal hemorrhage, retinal or choroidal detachment or endophthalmitis.

DISCUSSION

Although intravitreal drug administration, especially of anti-VEGF agents, is currently the major mode in the treatment of retinal diseases, it has recently been shown that drug administration to the SCS may represent a new route for drug administration to the posterior ocular tissue [5, 6]. Nowadays, the advanced OCT technology using

the ultra-high-resolution OCT (UHR-OCT), that has far deeper scanning penetration of the posterior eye segment, the SCS can be identified as hyporeflective band between the outer border of the choroid and the sclera [14].

Clinical trials have shown promising results in the application of TA via this route in reducing macular oedema in patients with various retinal diseases [7, 8, 9, 15, 16, 17]. Our results are in complete agreement with the findings of other researchers that this type of treatment of DMO is very effective. However, the design of these studies differed somewhat. Some of them used the SCS TA injection as mono-therapy and some combined it with simultaneous SCS application of anti-VEGF drugs [9, 16, 17]. Some studies have used the SCS TA injection in patients with no previous therapeutic exposure (primary naïve patients), and others in patients with persistent retinal thickening despite anti-VEGF therapy [9, 16]. As reported in previous studies, a single SCS injection of 4 mg / 0.1 ml TA is highly effective in reducing DMO for up to six months; at six months after SCS TA injection, the mean CST in the HULK trial was about 22%, while in the study by Yousef et al. [17] it was 36.6% lower than the initial values [16]. In our work, at the end of the sixth post-injection month, we noticed that CST was about 35% lower than the pre-injection values. Similar to the reduction in CSFT, both of these studies showed that there was a significant improvement in VA after injection: after 6 months in the HULK trial, the mean best-corrected visual acuity gain was +1.7 Snellen lines, while in the study by Yousef et al. [17], the mean best-corrected visual acuity gain was +2.0 Snellen lines [16]. In our study, this increase in VA after six months was about +2.4 Snellen lines.

The length of therapeutic effect of the SCS injected with 4 mg / 0.1 ml TA has not yet been determined. The conclusions of different studies are very different from each other. In the HULK trial, patients received the mean of 2.6 SCS TA injections during the six months of follow-up, i.e., every 2.5 months [16]. The MAGNOLIA study reported that approximately 50% of patients did not require additional treatment until nine months after the last SCS TA injection [7]. The PEACHTREE study that followed patients for 16 weeks after the SCS TA injection found that after four months, only 13.5% of them required repeated treatment [15]. All the above studies used a dose of 4 mg / 0.1 ml TA. The results of our study indicate that with a higher dose (10 mg / 0.1 ml TA), DMO can be successfully regulated with a single injection even for up to nine months.

Fluid from SCS can be cleared via physiological pathways by passive diffusion through the scleral canals around the vortex veins or through fenestrated choroidal capillaries. However, the particles of a suspension cannot be cleared by diffusion before they degrade [18]. Since experimental works have shown that large molecules can be retained in the SCS for a longer period of time due to slow clearance, this leads to the conclusion that the liquids in the form of a suspension are a better option for sustained drug delivery than solutions. Since TA particles have an average size of 11.8–18.8 µm, and their aggregates can be as large as 100–200 µm, the clearance rate of TA crystals

is very slow [19]. Slow clearance of TA suspension can sustain the release of the drug over a long period of time, enabling high therapeutic concentrations within the retina, retinal pigment epithelium, and choroid.

All the previous studies had in common that they all used the same dose of 4 mg / 0.1 ml TA for the SCS injection and all showed that DMO could be successfully regulated for up to six months. In our study we used a 2.5-times higher concentration of TA (10 mg / 0.1 ml) and our results indicate that DMO can be successfully controlled with this dose for up to nine months. It was only after nine months that we noticed the recurrence of oedema, followed by a consecutive decrease in VA which would require a repeated injection.

Two most common side effects of intravitreal injection of TA are the increase of IOP and cataract development. In the report by the Diabetic Retinopathy Clinical Research (DRCR) network, the use of intravitreal triamcinolone acetonide 4 mg was associated with 40–50% incidence of IOP elevation, and 51–59% incidence of cataract [4]. As reported by previous studies, the SCS of TA injection significantly less often leads to these complications. This can be explained by the fact that the anterior propagation of the TA is restricted by the scleral spur, so the structures in the anterior part of the eye, especially the crystalline lens and trabecular meshwork, are spared from high drug exposure. In the PEACHTREE study, IOP elevation was recorded in 11.5%, in the TANZANITE study in 8.7%, and in the TYBEE study in only 8.3% of the eyes [8, 9, 15]. Also, the incidence of cataract is significantly lower compared to intravitreal use of TA: in the PEACHTREE study cataract development was recorded in 11.5%, while in the TANZANITE study in only 4.4% of the eyes [8, 15]. Some studies did not show an IOP elevation and cataract development at all during the follow-up period [17]. In our study, a slight increase in IOP was observed at the end of the first post-injection month, but the IOP values by the end of the monitoring period did not differ statistically from the initial values.

We did not observe significant side effects in any of the analyzed eyes, either during the SCS TA injection or during the entire follow-up period. Our results support the fact that such a high concentration of TA is well tolerated and safe for diabetics. Although our study had a small number of eyes analyzed, due to the delicacy of the design and examination procedures, its results led us to the conclusion that only one concentrated (10 mg / 0.1 ml) TA SCS injection can stabilize macular oedema very effectively for nine months and maintain satisfactory VA. According to the newest data, our results confirm that a high concentration of SCS-applied TA can stabilize DMO over a much longer period compared to lower doses, without any additional side effects [20]. The main limitation of our study was the small number of eyes analyzed to draw a reliable conclusion that a concentrated dose of 10 mg / 0.1 ml TA is effective over a long period of time in the majority of eyes with clinically significant diabetic macular edema, and the fact that we were not able to use the UHR-OCT instrument for evaluation of the SCS after injection.

CONCLUSION

Suprachoroidal injection of TA provides high therapeutic drug concentrations in the target tissues i.e., the retina, retinal pigment epithelium, and choriocapillaris. In the treatment of DMO, the SCS application of TA leads to significant reduction of oedema and significant improvement of VA. Slow clearance of TA suspension can allow the sustained release of the drug over a long period of time. The single dose of 10 mg / 0.1 ml TA injected into the SCS can significantly stabilize macular oedema and

maintain satisfactory VA for up to nine months. Since the propagation of TA applied in this way to the anterior ocular structures is very limited compared to intravitreal application of TA, the incidence of IOP elevation and the cataract development is much lower. A greater number of participants, a longer period of monitoring, and the use of an UHR-OCT instrument to assess the SCS after injection are necessary to conclude the benefit of the suprachoroidal-applied high-dose TA in the treatment of DMO.

Conflict of interest: None declared.

REFERENCES

- Babiuch AS, Conti TF, Conti FF, Silva FQ, Rachitskaya A, Yuan A, et al. Diabetic macular oedema treated with intravitreal aflibercept injection after treatment with other anti-VEGF agents (SWAP-TWO study): 6-month interim analysis. *Int J Retina Vitreous*. 2019;5:17. [DOI: 10.1186/s40942-019-0167-x] [PMID: 31367468]
- Tang J, Kern TS. Inflammation in diabetic retinopathy. *Prog Retin Eye Res*. 2011;30(5):343–58. [DOI: 10.1016/j.preteyeres.2011.05.002] [PMID: 21635964]
- Jonas JB, Hayler JK, Panda-Jonas S. Intravitreal injection of crystalline cortisone as adjunctive treatment of proliferative vitreoretinopathy. *Br J Ophthalmol*. 2000;84(9):1064–7. [DOI: 10.1136/bjo.84.9.1064] [PMID: 10966969]
- Diabetic Retinopathy Clinical Research Network. A randomized trial comparing intravitreal triamcinolone acetonide and focal/grid photocoagulation for diabetic macular oedema. *Ophthalmology*. 2008;115(9):1447–9. [DOI: 10.1016/j.ophtha.2008.06.015] [PMID: 18662829]
- Moisseiev E, Loewenstein A, Yiu G. The suprachoroidal space: from potential space to a space with potential. *Clin Ophthalmol*. 2016;10:173–8. [DOI: 10.2147/OPHT.S89784] [PMID: 26869750]
- Naftali Ben Haim L, Moisseiev E. Drug Delivery via the Suprachoroidal Space for the Treatment of Retinal Diseases. *Pharmaceutics*. 2021;13(7):967. [DOI: 10.3390/pharmaceutics13070967] [PMID: 34206925]
- Khurana RN, Merrill P, Yeh S, Suhler E, Barakat MR, Uchiyama E, et al. Extension study of the safety and efficacy of CLS-TA for treatment of macular oedema associated with non-infectious uveitis (MAGNOLIA). *Br J Ophthalmol*. 2022;106(8):1139–44. [DOI: 10.1136/bjophthalmol-2020-317560] [PMID: 33712478]
- Campochiaro PA, Wykoff CC, Brown DM, Boyer DS, Barakat M, Taraborelli D, et al. Suprachoroidal Triamcinolone Acetonide for Retinal Vein Occlusion: Results of the Tanzanite Study. *Ophthalmol Retin*. 2018;2(4):320–8. [DOI: 10.1016/j.oret.2017.07.013] [PMID: 31047241]
- Barakat MR, Wykoff CC, Gonzalez V, Hu A, Marcus D, Zavaleta E, et al. Suprachoroidal CLS-TA plus Intravitreal Aflibercept for Diabetic Macular Oedema: A Randomized, Double-Masked, Parallel-Design, Controlled Study. *Ophthalmol Retin*. 2021;5(1):60–70. [DOI: 10.1016/j.oret.2020.08.007] [PMID: 32829027]
- Gilger BC, Abarca EM, Salmon JH, Patel S. Treatment of acute posterior uveitis in a porcine model by injection of triamcinolone acetonide into the suprachoroidal space using microneedles. *Invest Ophthalmol Vis Sci*. 2013;54(4):2483–92. [DOI: 10.1167/iops.13-11747] [PMID: 23532526]
- Oli A, Waikar S. Modified inexpensive needle for suprachoroidal triamcinolone acetonide injections in pseudophakic cystoid macular oedema. *Indian J Ophthalmol*. 2021;69(3):765–7. [DOI: 10.4103/ijo.IJO_1464_20] [PMID: 33595522]
- Classification of diabetic retinopathy from fluorescein angiograms. ETDRS report number 11. Early Treatment Diabetic Retinopathy Study Research Group. *Ophthalmology*. 1991;98(5 Suppl):807–22. [DOI: 10.1016/S0161-6420(13)38013-0] [PMID: 2062514]
- Bressler NM, Edwards AR, Antoszyk AN, Beck RW, Browning DJ, Ciardella AP, et al; Diabetic Retinopathy Clinical Research Network. Retinal thickness on Stratus optical coherence tomography in people with diabetes and minimal or no diabetic retinopathy. *Am J Ophthalmol*. 2008;145(5):894–901. [DOI: 10.1016/j.ajo.2007.12.025] [PMID: 18294608]
- Gu B, Liu J, Li X, Ma QK, Shen M, Cheng L. Real-Time Monitoring of Suprachoroidal Space (SCS) Following SCS Injection Using Ultra-High Resolution Optical Coherence Tomography in Guinea Pig Eyes. *Invest Ophthalmol Vis Sci*. 2015;56(6):3623–34. [DOI: 10.1167/iops.15-16597] [PMID: 26047049]
- Yeh S, Khurana RN, Shah M, Henry CR, Wang RC, Kissner JM, et al; PEACHTREE Study Investigators. Efficacy and Safety of Suprachoroidal CLS-TA for Macular Edema Secondary to Noninfectious Uveitis: Phase 3 Randomized Trial. *Ophthalmology*. 2020;127(7):948–55. [DOI: 10.1016/j.ophtha.2020.01.006] [PMID: 32173113]
- Lampen SIR, Khurana RN, Noronha G, Brown DM, Wykoff CC. Suprachoroidal space alterations following delivery of triamcinolone acetonide: Post-hoc analysis of the phase 1/2 HULK study of patients with diabetic macular oedema. *Ophthalmic Surg Lasers Imaging Retin*. 2018;49(9):692–7. [DOI: 10.3928/23258160-20180831-07] [PMID: 30222804]
- Yousef MS, Elhafaiz YS, Farag MH. Assessment of Suprachoroidal Injection of Triamcinolone Acetonide in Cases of Diabetic Macular Oedema. *IJMA*. 2021;3(2):1384–9. [DOI: 10.21608/IJMA.2021.55079.1230]
- Chiang B, Wang K, Ethier CR, Prausnitz MR. Clearance Kinetics and Clearance Routes of Molecules From the Suprachoroidal Space After Microneedle Injection. *Invest Ophthalmol Vis Sci*. 2017;58(1):545–54. [DOI: 10.1167/iops.16-20679] [PMID: 28125841]
- Chen H, Sun S, Li J, Du W, Zhao C, Hou J, et al. Different intravitreal properties of three triamcinolone formulations and their possible impact on retina practice. *Invest Ophthalmol Vis Sci*. 2013;54(3):2178–85. [DOI: 10.1167/iops.12-11460] [PMID: 23449717]
- Zakaria YG, Salman AG, Said AMA, Abdelatif MK. Suprachoroidal versus Intravitreal Triamcinolone Acetonide for the Treatment of Diabetic Macular Edema. *Clin Ophthalmol*. 2022;16:733–46. [DOI: 10.2147/OPHT.S351853] [PMID: 35300032]

Супрахороидално апликован концентровани триамцинолон-ацетонид у лечењу дијабетичког макуларног едема

Ненад Петровић^{1,2}, Душан Тодоровић^{1,2}, Сунчица Срећковић^{1,2}, Михаило Јовановић³, Татјана Шаренац-Вуловић^{1,2}

¹Универзитет у Крагујевцу, Факултет медицинских наука, Катедра за офталмологију, Крагујевац, Србија;

²Клинички центар Крагујевац, Клиника за офталмологију, Крагујевац, Србија;

³Универзитет у Крагујевцу, Факултет медицинских наука, Крагујевац, Србија

САЖЕТАК

Увод/Циљ Дијабетички макуларни едем је абнормално акумулација течности у макуларном ткиву које доводи до његовог задебљања.

Циљ студије је био да се процени ефикасност инјекције концентрованог триамцинолон-ацетонида од 10 mg / 0,1 ml у супрахороидални простор код болесника са дијабетичким макуларним едемом и сниженом видном оштрином.

Метод Код 12 очију са дијабетичким макуларним едемом, које до тада нису имале никакав претходни третман, употребом игле малог пречника (26G) апликована је инјекција од 10 mg / 0,1 ml триамцинолон-ацетонида у супрахороидални простор у суперотемпоралном квадранту ока, 4 mm од лимбуса. Пре инјекције, као и један месец, три, шест, девет и 12 месеци после инјекције, проверавани су видна оштрина и интраокуларни притисак, а централна фовеална дебљина је мерена помоћу оптичке кохерентне томографије.

Резултати Један месец, три, шест и девет месеци после инјекције дошло је до статистички значајног смањења централне фовеалне дебљине (315,92 μ m, 257,66 μ m, 281,08 μ m и 295,51 μ m респективно) у односу на њену почетну вредност од 447,67 μ m. Крајем 12. месеца поново је примећен пораст централне фовеалне дебљине до 392,16 μ m. Видна оштрина се значајно побољшала у односу на почетну вредност (0,32) током прва три месеца (0,61) и остала је стабилна до краја деветог месеца (0,51), али се на крају 12. месеца поново смањила (0,39). Током читавог периода праћења ни код једног ока нису примећени значајно повишење интраокуларног притиска и развој катаракте.

Закључак Једна доза од 10 mg / 0,1 ml триамцинолон-ацетонида убризгана у супрахороидални простор може значајно стабилизovati дијабетички макуларни едем и одржати задовољавајућу видну оштрину до девет месеци.

Кључне речи: дијабетички макуларни едем; триамцинолон-ацетонид; супрахороидална инјекција