



## ORIGINAL ARTICLE / ОРИГИНАЛНИ РАД

# A retrospective analysis of different treatments of posterior acetabular wall fracture

Branislav Starčević<sup>1</sup>, Stefan Korica<sup>1</sup>, Zoran Radojičić<sup>2</sup>, Igor Đorić<sup>3</sup>, Marko Kadija<sup>1</sup>, Ana Starčević<sup>4</sup>

<sup>1</sup>University of Belgrade, Faculty of Medicine, University Clinical Center of Serbia, Clinic for Orthopaedic Surgery and Traumatology, Belgrade, Serbia;

<sup>2</sup>University of Belgrade, Faculty of Organizational Sciences, Belgrade, Serbia;

<sup>3</sup>University of Belgrade, Faculty of Medicine, University Clinical Center of Serbia, Clinic for Neurosurgery, Radiology Department, Belgrade, Serbia;

<sup>4</sup>University of Belgrade, Faculty of Medicine, Institute of Anatomy, Belgrade, Serbia

## SUMMARY

**Introduction/Objective** The objective of the paper is an analysis of clinical outcomes of non-surgical conservative and operative management of patients with posterior acetabular wall fractures.

**Methods** We investigated 88 fractures of the acetabular joint, 31 of which were treated surgically and 57 non-surgically. Only screws or reconstruction plates and screws were used for surgical treatment and traction in patients who underwent nonsurgical treatment. The study period lasted at least three years. The measures used to assess the outcome of operative, surgical and non-operative, conservative approach were Merle d'Aubigné modified score, Harris hip score, and Matta's radiometric criteria.

**Results** Matta's evaluation criteria showed an excellent score of 40.4% in conservatively treated patients; 19.4% in patients who underwent surgery; a good score of 49.1% in conservatively treated patients; and 48.4% in patients who underwent surgery. Comparison between two patient groups differently treated, by Merle d'Aubigné tool, showed excellent results for 56.1% conservatively treated patients and 25.8% in those patients who underwent surgery, and good results in 29.8% conservatively treated patients and 38.7% in patients who underwent surgery. Harris hip score (excellent results were showed in 54.4% for non-operative-treated patients) also showed statistical significance,  $p < 0.005$ .

**Conclusion** Proper diagnostics and a proper definitive diagnosis can help avoid surgical treatment if the fracture cannot be treated surgically, making the postoperative period more comfortable for the patient.

**Keywords:** acetabulum; fracture; non-operative treatment; operative treatment

## INTRODUCTION

Acetabular fractures have always been difficult for orthopedic surgeons to treat, as many post-operative complications may occur. Fractures of the posterior wall of the acetabulum are the most common among acetabular fractures and instability of the hip itself may depend on the size of a fragment. Standard protocol implies, after non-operative or operative treatment, immobilization for an average of at least 12 weeks [1, 2, 3]. In a situation of acetabular fracture with hip luxation and the absence of luxated fracture fragments, closed reposition could be managed, followed by traction during the next two months for acetabular relief [4]. Operative treatment includes reposition of the fragments with osteosynthesis by screws and plate [5, 6]. The most common approach used in operative treatment is Kocher–Langenbeck approach. Post-operatively, physical therapy is recommended. After operative treatment, it is recommended to avoid the loading of the injured hip at least up to 12 weeks [7]. Varying results by different authors have been published about the outcomes in the case of operative treatment. Closed reduction in short-term anesthesia can be made in the case of acetabular fracture with dislocation of the joint, and the absence of displacement of bone

fragments, followed by application of traction up to two months for acetabular relief [4]. In the case of operative treatment that includes repositioning of fragments, their osteosynthesis with screw or plate with screws, the most commonly used is the Kocher–Langenbeck approach. More papers present operative treatment as a better solution than the non-operative one [8–11]. When the remaining intact part of the acetabulum is sufficient to keep the femoral head in a normal position with the roof of the acetabulum, non-operative treatment is indicated. There is no standard protocol regarding the use of solely screws or screws with plates in operative treatment [5, 6]. Most of the clinicians use the Harris hip score (HHS) and the Merle d'Aubigné and Postel method in the assessments of functional results [12].

Overall rise in high-energy trauma has resulted in an increase in acetabular fractures in Serbia.

The aim of this retrospective study was to analyze and correlate functional results and scores of non-operative, conservative management of patients with fractures of posterior acetabular wall with operative management of fractures of posterior acetabular wall, at the Orthopaedic Department of the University Clinical Centre of Serbia.

**Received • Примљено:**  
December 14, 2022

**Revised • Ревизија:**  
March 30, 2023

**Accepted • Прихваћено:**  
April 2, 2023

**Online first:** April 21, 2023

### Correspondence to:

Branislav STARČEVIĆ  
University of Belgrade  
University Clinical Centre of Serbia  
Clinic for Orthopaedic Surgery and  
Traumatology  
11000 Belgrade  
Serbia  
[medicusbane@hotmail.com](mailto:medicusbane@hotmail.com)

## METHODS

Our investigation included 81 patients with posterior wall acetabular fractures out of which 31 underwent operative treatment at the Orthopaedic Department Emergency Centre, University Clinical Centre of Serbia, Belgrade, Serbia. Conservative, non-operative management took 57 patients. The study was approved by the Ethics Committee of the University Clinical Centre of Serbia, Belgrade, Serbia (approval number 29/V-15).

The inclusion criteria for both groups of this study were as follows:

1. Injury of the posterior wall of the acetabulum;
2. Follow-up of at least three years;
3. No other surgical interventions on the injured hip.

Exclusion criteria for both examined groups were as follows:

1. Inadequate patient's history;
2. Insufficient follow-up period of the patient;
3. Patients who were treated in other hospitals.

The inclusion criteria for operative group of this study were as follows:

1. Unstable hip joint after repositions;
2. Fragment dislocation bigger than 3 mm;
3. Not a demanding patient, with no high expectations.

All of the patients were evaluated with three-dimensional computed tomography (CT) besides conventional, golden standard, X-ray examination, in order to define the type of fracture, bone fragment size, fragment quantity, and dislocation severity.

After patients' physical condition was determined as stable, those indicated for operative treatment underwent operative treatment. Closed reduction of the hip dislocation was performed under general anesthesia. Hip was flexed to 90°, then rotated internally for 20°, and, finally, maximally adducted in order to establish stability. One of the indications for surgery was re-dislocated hip fracture when more than 50°. We used Kocher–Langenbeck exposure with special attention to the sciatic nerve, which we preserved and protected from possible injuries. There were two types of fixations that we used. First, we used multiple screws in the case of comminute fractures, with a bone fragment large enough to accommodate at least two screws. In that case, the main fracture was on the superior-posterior side of the acetabulum. Secondly, we used reconstruction plating in cases of very severe comminute fracture, in which case the main fracture was determined at the middle-inferior side of the acetabulum. The X-ray established the reposition of the fragments and reduction after the operative procedure was done. The immobilization period was four weeks. Partial weight-bearing was suggested afterwards, with a recommendation for a gradual progression to total-body weight-bearing 12 weeks after surgery was performed.

Those patients who were not indicated to be treated operatively stayed at the hospital for a short follow-up and additional diagnostics. Those who did not have hip luxation were discharged from the hospital. Traction was also used as a non-operative treatment.

Modified Merle d'Aubigné and Postel method, HHS, and radiological grading criteria by Matta were the tools that we used to analyze and estimate hip function during regular medical check-ups. Modified Merle d'Aubigné and Postel method include verification of different ranges of movement manifested and scored as the percentage normal hip score, measured by evaluating the total range of the movements (flexion–extension, abduction, adduction, external rotation, and internal rotation for the injured hip) in degrees, divided by the total score of the normal, healthy hip. The overall clinical score is formed as a sum of pain values, walking, and range of movements. Post-operative follow-up is very often evaluated by HHS, referring to greater dysfunction if the score is higher (total score of 70 – poor results, 70–80 – good, moderate results, 90–100 is an excellent result in postoperative follow-up).

## RESULTS

In the group of operatively treated patients, there were 28 male (90.3%) and three female (9.7%) patients. In the group of non-operatively treated patients, there were 51 male (89.5%) and six female (10.5%) patients.

Core mechanism of the injury was traffic accident and the percentage was 56.8%. The left hip was injured in 46 patients (52.3%), and associated hip luxation was present in 77 patients (87.5%). There was also associated injury to another system observed. Conjoint injuries were present in two cases (2.3%), who had sciatic injury, eight (9.1%) had head injury, and seven (8%) had chest injury. Fragment displacement of less than 3 mm, which was evaluated by preoperative CT, was seen in 51.1% of patients, and more than 3 mm in 48.9% of patients. Fractures were fixed with screws alone in 21 patients (23.9%), and with screws and plates in 10 patients (11.4%) (Table 1).

**Table 1.** Comparing the type of treatment with other parameters

| Type of treatment vs.            | p            |
|----------------------------------|--------------|
| Sex                              | 0.900        |
| Injury                           | <b>0.037</b> |
| Hip                              | 0.422        |
| Conjoint with hip luxation       | <b>0.001</b> |
| Other conjoint                   | 0.503        |
| Type of injury                   | 0.125        |
| Early complications              | 0.213        |
| CT/RTG post-operative evaluation | <b>0.000</b> |
| Late complications               | 0.096        |
| Ossification                     | <b>0.008</b> |
| Traction                         | 0.967        |
| Matti                            | <b>0.049</b> |
| Merle d'Aubigné – Postel score   | <b>0.023</b> |
| Harris hip score                 | <b>0.030</b> |

Post-operative CT showed anatomical reposition in 48 patients (54.5%), fragments luxation less than 3 mm in 34 patients (38.6%), and more than 3 mm in six patients (6.8%). Avascular necrosis as a post-operative complication

was observed in four patients (4.5%), and post-traumatic arthrosis in 84 patients (95.5%). Ossification was found in 54 patients (61.4%). Results of different treatment approaches were estimated by different specific tools very sensitive to this orthopedic pathology. If we analyze Merle d'Aubigné values, the percentage results were 45.5% (excellent), 33% (good), 11.4% (fair), and 10.2% (poor). Observing and estimating HHS, the results were 44.3% (excellent), 34.1% (good), 11.4% (fair), and 10.2% (poor). The Matta grading scale percentage of excellent, good, fair, and poor was 33%, 48.9%, 9.1%, and 9.1%, respectively (Table 2).

**Table 2.** Level of efficiency of different treatments used by three scales

| Type of treatment | Good % | Poor % | Total % | Test and p-value |
|-------------------|--------|--------|---------|------------------|
| Operatively       | 67.7   | 22.3   | 100     | <i>Matta2</i>    |
| Non-operatively   | 89.5   | 10.5   | 100     | <b>0.012</b>     |
| Operatively       | 64.5   | 35.5   | 100     | <i>Merle2</i>    |
| Non-operatively   | 86     | 14     | 100     | <b>0.019</b>     |
| Operatively       | 64.5   | 35.5   | 100     | <i>Harris2</i>   |
| Non-operatively   | 86     | 14     | 100     | <b>0.019</b>     |

On comparing the methods of treatment of the operative and the non-operative groups of patients, we found statistical significance of  $p = 0.037$ .

Statistical significance was shown when a comparison was made between the operative and the non-operative groups of patients in relation to the methods of treatment and conjointment with the hip luxation ( $p = 0.001$ ) (Table 2).

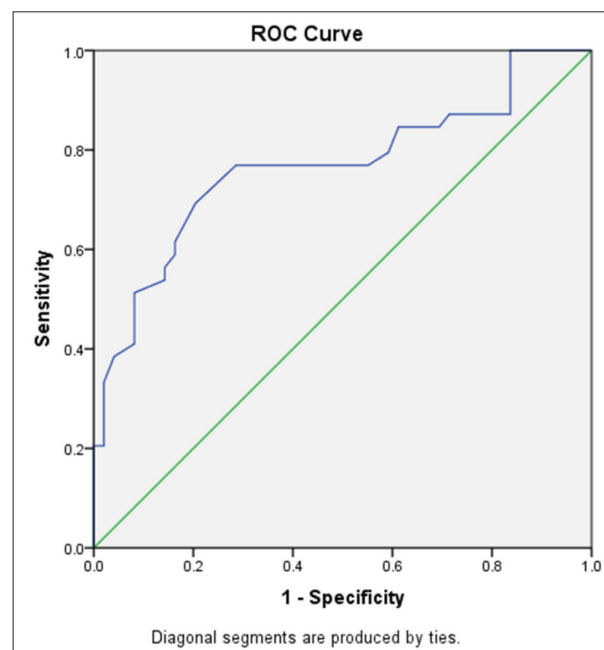
Statistical significance was also shown when using Pearson's  $\chi^2$ -compared methods of treatment and level of ossification ( $p = 0.008$ ).

Our results showed excellent scores of 40.4% in the group of conservatively treated, non-operative patients, and 19.4% in the group of patients who were treated operatively, referring to Matta values analysis. Good results were estimated at 49.1% for the conservatively managed group of patients and at 48.4% for the patients who underwent surgery. In analysis of modified Merle d'Aubigné scores, statistical parameters that manifested significance ( $p < 0.005$ ) were excellent results in 56.1% of the conservatively treated and in 25.8% of those who underwent surgery. We found statistical significance in results of HHS; there were excellent results of 54.4% for non-operatively treated patients. Pearson's  $\chi^2$  showed statistical significance for the association methods of treatment and Matta radiographic grading ( $p = 0.012$ ).

**Table 3.** Receiver operating characteristic curve results for the duration of not supporting the injured leg after the surgery

| Test result variable(s) |                 | Duration of not supporting         |             | P/N ratio     |
|-------------------------|-----------------|------------------------------------|-------------|---------------|
| Area                    | Asymptotic sig. | Asymptotic 95% confidence interval |             |               |
|                         |                 | Lower bound                        | Upper bound | Cut-off point |
| 0.767                   | 0.000           | 0.662                              | 0.872       | 63 days       |

Using the receiver operating characteristic (ROC) curve, we found high statistical significance for the duration of not supporting the injured leg after the surgery ( $p = 0.000$ ).



**Figure 1.** Sensitivity and specificity for the treatment and duration of support

The cut-off point was 63 days given by the P/N ratio (Table 3) and area under the ROC curve is 0.767 (95% confidence interval: 0.662, 0.872).

High sensitivity and specificity were shown using the ROC curve for the treatment and duration of support to the injured leg after the surgery (Figure 1).

## DISCUSSION

Acetabular fractures present a complex situation in which operative treatment is recommended unless the medical indication for nonoperative, conservative treatment is met and if it is not, the final decision depends on the patients' comorbidities and their expectations after treatment. There is also one more variable in this equation related to medical technical support and the surgeon's experience according to which the decision is going to be made. In each way chosen, the treatment should be based on early mobilization in order to avoid postoperative complications. Acetabular fractures generally remain an enigma for orthopedic surgeons, especially for those coming from developing countries. The posterior wall of the acetabulum presents very specific anatomical substrate and its fractures and classification can be very difficult to observe, partially due to poor technical support [13]. Previous investigations showed that even when a satisfying management of the posterior acetabular wall fractures was performed, not all of them presented efficient clinical and functional result [13, 14]. The emphasis of this result was osteonecrosis manifestation and difficulties in managing the reconstruction of heavy comminuted fractures [14, 15, 16]. Our research focused on the analysis of conservative-treatment results and correlate them to operative-treatment results. According to our results analysis, in the case of Matta radiographic grading,

we had 81.9% good-to-excellent clinical result when the patients were conservatively treated, in the case of HHS we had 78.4%, and in the case of Merle d'Aubigné we had 75.5% good-to-excellent clinical results [17]. Results of clinical investigation performed by Matta et al. [18] showed poor results, and only 15 patients had good-to-excellent results. Possible causes were irregular congruence of articulation surfaces, patient's age and injury to the femoral neurovascular bundle. Previous studies suggest that postoperative outcomes were better in younger- than in older-age patients, as they had greater percentage of postoperative complications and therefore physical therapy went poorly. Moreover, adjacent conditions such as obesity, diabetes, and heart disease present important risk factors that may predispose the direction of postoperative follow-up. Present adjacent arthritis presents a condition which leads to non-satisfying overall functional results if the operative technique includes internal fixation. The mental status of the patient is of great importance as it may impact the determination to be activated physically and a will to overcome bad painful periods of the postoperative period.

The follow-up period was not less than three years and included contacts with the patients through regular medical controls and check-ups. Patients followed for less than three years with a poor clinical result were not excluded from the study.

As previously mentioned, there are many factors that make a great impact on treatment plan of posterior wall acetabular fractures, such as medical equipment and technical support, which is always lacking, especially in developing countries. We might consider the above mentioned as a limitation of our study. Anatomical reposition can be a very demanding and important predicting factor related to postoperative outcomes. Previous experimental studies

showed that proper anatomical reposition with internal fixation does not intentionally improve posterior acetabular wall fracture specifically. Our study results analysis support previous study conclusions of great importance of anatomically correct reposition in a fast overall restitution of a patient's health. Time management is of great importance if we want satisfying clinical results; therefore, less than 12 hours from the initial differential diagnosis would be borderline time to start a specific treatment [19, 20, 21].

Clinically excellent or very good functional results of fracture treatment generally remain stable over time, but when arthritis is present, the results which were satisfying may decrease or deteriorate [22]. Previous investigations defined core risk factors for disappointing results regardless of the treatment going in the non-operative or the operative direction. These factors were postponement of more than 12 hours before the reduction of a hip fragment dislocation, age of 55 years and older, femoral head osteonecrosis, and intra-articular comminution [22, 23, 24]. Femoral head osteonecrosis is not present as a complication in every patient if a delayed reduction management of a hip dislocation is done, or if an early reduction does not induce its presentation. Previous evidence points to the fact that any unnecessary delay of treatment of any kind should be evaded.

## CONCLUSION

Our study suggests that non-operative treatment with early movement activation, weight-bearing, may avoid serious complications that can be related to surgical management.

**Conflict of interest:** None declared.

## REFERENCES

- Mitsionis GI, Lykissas MG, Moutsis E, Mitsiou D, Gkiatas I, Xenakis TA, et al. Surgical management of posterior hip dislocations associated with posterior wall acetabular fracture: a study with a minimum follow-up of 15 years. *J Orthop Trauma*. 2012;26(8):460–5. [DOI: 10.1097/BOT.0b013e31822c4d6c] [PMID: 22357088]
- Li Y, Ge Y, Liu H, Zhu S, Wu X. Midterm results of digastric trochanteric flip osteotomy for high acetabular posterior wall fracture. *Int Orthop*. 2022;46(8):1881–9. [DOI: 10.1007/s00264-022-05446-6] [PMID: 35610389]
- Qi X, Liu JG, Gong YB, Yang C, Li SQ, Feng W. Treatment of posterior wall fractures of acetabulum. *Chin J Traumatol*. 2009;12(2):113–7. [PMID: 19321057]
- Magu NK, Rohilla R, Arora S. Conservatively treated acetabular fractures: A retrospective analysis. *Indian J Orthop*. 2012;46(1):36–45. [DOI: 10.4103/0019-5413.91633] [PMID: 22345805]
- Im GI, Shin YW, Song YJ. Fractures to the posterior wall of the acetabulum managed with screws alone. *J Trauma*. 2005;58(2):300–3. [DOI: 10.1097/01.ta.0000149329.86361.ce] [PMID: 15706191]
- Vale J, Diniz S, Leite PS, Soares D. Surgical Treatment of Acetabular Posterior Wall Fracture with Hip Arthroscopy: A Case Report. *Hip Pelvis*. 2022;34(1):62–7. [DOI: 10.5371/hp.2022.34.1.62] [PMID: 35355629]
- Heimke IM, Scarcella NR, Simske NM, Furdock R, Vallier HA. Surgical Versus Nonsurgical Management of Acetabular Fractures With Associated Patterns in Elderly Patients: Factors Affecting Outcomes. *J Am Acad Orthop Surg Glob Res Rev*. 2022;6(3):e22.00014. [DOI: 10.5435/JAAOSGlobal-D-22-00014] [PMID: 35245237]
- Meesters AML, Ten Duis K, Kraeima J, Banierink H, Stirlor VMA, Wouters PCR, et al. The accuracy of gap and step-off measurements in acetabular fracture treatment. *Sci Rep*. 2021;11(1):18294. [DOI: 10.1038/s41598-021-97837-9] [PMID: 34521962]
- Kelly J, Ladurner A, Rickman M. Surgical management of acetabular fractures - A contemporary literature review. *Injury*. 2020;51(10):2267–77. [DOI: 10.1016/j.injury.2020.06.016] [PMID: 32646650]
- Castano Betancourt MC, Maia CR, Munhoz M, Morais CL, Machado EG. A review of Risk Factors for Post-traumatic hip and knee osteoarthritis following musculoskeletal injuries other than anterior cruciate ligament rupture. *Orthop Rev (Pavia)*. 2022;14(4):38747. [DOI: 10.52965/001c.38747] [PMID: 36349350]
- Perdue PW Jr, Tainter D, Toney C, Lee C. Evaluation and Management of Posterior Wall Acetabulum Fractures. *J Am Acad Orthop Surg*. 2021;29(21):e1057–e1067. [DOI: 10.5435/JAAOS-D-20-01301] [PMID: 34323866]
- D'Aubigne RM, Postel M. Functional results of hip arthroplasty with acrylic prosthesis. *J Bone Joint Surg Am*. 1954;36-A(3):451–75. [PMID: 13163078]
- Matta JM. Fractures of the acetabulum: accuracy of reduction and clinical results in patients managed operatively within three weeks after the injury. *J Bone Joint Surg Am*. 1996;78(11):1632–45. [PMID: 8934477]



14. Letournel E. Surgical repair of acetabular fractures more than three weeks after injury, apart from total hip replacement. *Int Orthop*. 1978;2:305–13. [DOI: 10.1007/BF00571814]
15. Letournel E, Judet R, Elson RA. *Fractures of the acetabulum*. 2nd ed. Berlin, Heidelberg, New York: Springer; 1993. p. 428.
16. Bueno TSP, Godoy GP, Furukava RB, Gaggioli NT, Tamaoki MJS, Matsunaga FT, et al. Heterotopic ossification in acetabular fractures: systematic review and meta-analysis of prophylaxis. *Acta Ortop Bras*. 2021;29(6):331–40. [DOI: 10.1590/1413-785220212906244689] [PMID: 34849100]
17. Islam MN, Rahman MM, Islam MS, Kabir SJ, Alamgir MK, Kashem MT, et al. Outcome of Open Reduction and Internal Fixation of Posterior Wall Fracture of Acetabulum. *Mymensingh Med J*. 2020;29(3):502–8. [PMID: 32844786]
18. Matta JM, Mehne DK, Roffi R. Fractures of the acetabulum. Early results of a prospective study. *Clin Orthop Relat Res*. 1986;(205):241–50. [PMID: 3698383]
19. Perumal R, Valleri DP, Gessesse MT, Jayaramaraju D, Rajasekaran S. Marginal impaction in complex posterior wall acetabular fractures: role of allograft and mid-term results. *Eur J Orthop Surg Traumatol*. 2020;30(3):435–40. [DOI: 10.1007/s00590-019-02584-3] [PMID: 31679048]
20. Elnahal WA, Ward AJ, Acharya MR, Chesser TJS. Does Routine Postoperative Computerized Tomography After Acetabular Fracture Fixation Affect Management? *J Orthop Trauma*. 2019;33 Suppl 2:S43–S48. [DOI: 10.1097/BOT.0000000000001405] [PMID: 30688859]
21. Manson TT. Open Reduction and Internal Fixation Plus Total Hip Arthroplasty for the Acute Treatment of Older Patients with Acetabular Fracture: Surgical Techniques. *Orthop Clin North Am*. 2020;51(1):13–26. [DOI: 10.1016/j.ocl.2019.08.006] [PMID: 31739876]
22. Moed BR, WillsonCarr SE, Watson JT. Results of operative treatment of fractures of the posterior wall of the acetabulum. *J Bone Joint Surg Am*. 2002;84(5):752–8. [DOI: 10.2106/00004623-200205000-00008] [PMID: 12004016]
23. Warner SJ. Prone Versus Lateral Positioning for Posterior Acetabular Fracture Surgery. *J Orthop Trauma*. 2023;37(1):e51–e52. [DOI: 10.1097/BOT.0000000000002501] [PMID: 36518069]
24. Graulich T, Gräff P, Omar Pacha T, Örgel M, Macke C, Omar M, et al. Posterior acetabular wall morphology is an independent risk factor that affects the occurrence of acetabular wall fracture in patients with traumatic, posterior hip dislocation. *Eur J Trauma Emerg Surg*. 2023;49(1):343–9. [DOI: 10.1007/s00068-022-02072-0] [PMID: 36194242]

## Ретроспективна анализа различитих начина лечења прелома задњег зида ацетабулума

Бранислав Старчевић<sup>1</sup>, Стефан Корица<sup>1</sup>, Зоран Радојичић<sup>2</sup>, Игор Ђорић<sup>3</sup>, Марко Кадија<sup>1</sup>, Ана Старчевић<sup>4</sup>

<sup>1</sup>Универзитет у Београду, Медицински факултет, Универзитетски клинички центар Србије, Клиника за ортопедску хирургију и трауматологију, Београд, Србија;

<sup>2</sup>Универзитет у Београду, Факултет организационих наука, Београд, Србија;

<sup>3</sup>Универзитет у Београду, Медицински факултет, Универзитетски клинички центар Србије, Клиника за неурохирургију, Одељење радиологије, Београд, Србија;

<sup>4</sup>Универзитет у Београду, Медицински факултет, Институт за анатомију, Београд, Србија

### САЖЕТАК

**Увод/Циљ** Циљ рада је процена исхода неоперативно и оперативно лечених болесника са преломима задњег зида ацетабулума.

**Метод** Процењено је укупно 88 прелома ацетабулума, 31 оперативно и 57 неоперативно лечених. У оперативном лечењу коришћени су или само шрафови или реконструктивне плоче и шрафови. Тракција као метода коришћена је код болесника који су лечени неоперативно. Период праћења је био најмање три године. Инструменти коришћени за процену исхода оперативног и неоперативног лечења били су модификовани скор Мерл д'Обиње (*Merle d'Aubigne*), Харисов скор кука и радиолошки критеријуми за оцењивање по Мати (*Matta*).

**Резултати** Имали смо статистичку значајност  $p < 0,005$  и одличне резултате са 40,4% у неоперативној групи и 19,4% у оперативној групи болесника користећи Мата евалуацију;

добре резултате са 49,1% за неоперативну групу и 48,4% за оперативну групу. Помоћу модификованог инструмента Мерл д'Обиње поређење две групе, неоперативне и оперативне, показало је одличне резултате: 56,1% за неоперативно лечене болеснике и 25,8% за оперативно лечене болеснике. Добри резултати су били код 29,8% неоперативних и код 38,7% оперативно лечених болесника. Када смо повезали неоперативне и оперативне болеснике, пронашли смо статистичку значајност  $p < 0,005$  у случају Харисовог скор кука; одлични резултати су били код 54,4% неоперативно лечених болесника.

**Закључак** Адекватну дијагностику и тачну коначну дијагнозу треба поставити на начин да се избегне оперативно лечење уколико се прелом може лечити неоперативно.

**Кључне речи:** ацетабулум; прелом; неоперативно лечење; оперативно лечење