

ORIGINAL ARTICLE / ОРИГИНАЛНИ РАД

Low-level laser efficiency in reparation of bone defects

Radmila Obradović¹, Sanja Vujović², Jana Desnica², Momir Stevanović², Dragana Stanišić², Irena Ognjanović², Mirko Mikić³, Borivoj Bijelić⁴, Ljiljana Šubarić⁵, Vladan Đorđević⁶

¹University of Niš, Faculty of Medicine, Niš, Serbia;

²University of Kragujevac, Faculty of Medical Sciences, Kragujevac, Serbia;

³University of Montenegro, Faculty of Medicine, Podgorica, Montenegro;

⁴University of Belgrade, School of Dental Medicine, Belgrade, Serbia;

⁵University of Priština – Kosovska Mitrovica, Faculty of Medicine, Kosovska Mitrovica, Serbia;

⁶University of Travnik, Faculty of Pharmacy and Health, Travnik, Federation of Bosnia and Herzegovina, Bosnia and Herzegovina



SUMMARY

Introduction/Objective Bone resorption is a common problem in dentistry, and bone reparation cannot be easily achieved. Several techniques of bone grafting and the use of low-level laser treatment (LLLT) as a new therapeutic optional recommended for improving bone repair were applied. The aim of the study was to investigate the influence of LLLT in bone repair of artificially made bone defects in the rat mandible using histomorphometry.

Methods The research was carried out on 60 female rats. Bone defects were made in the mandible, and animals were divided into two groups, each containing 30 animals. In the study group, the implantation site was submitted to GaAlAs laser irradiation 670 nm, 5 mW, 4 minutes per day for 5 days. The control group had no postoperative treatment. The animals were sacrificed after two, six, and eight weeks post LLLT, and preparations were analysed by histomorphometry, determining bone area fraction, bone area, integral density, mean density, and density variation.

Results Histomorphometric analysis revealed statistically higher values of area fraction, area, and integral density in the study group after two and six weeks. However, no beneficial laser effect was noticed after eight weeks.

Conclusion Low-level lasers have a stimulating effect on reparatory mechanisms in the early regeneration stage of artificially made bone defects in the rat mandible and can be used as a useful helping method in bone treatment.

Keywords: bone; low-level laser treatment; osteogenesis

INTRODUCTION

Alveolar bone resorption is a common problem in dentistry that occurs due to several pathologic and physiologic conditions. In such cases, reparative potentials of bone vary, and reparation cannot be easily achieved. Many techniques of bone grafting have been recommended for improving bone repair; the use of low-level laser treatment (LLLT) is a new therapeutic option [1]. The use of LLLT as a bio-modulation tool in dentistry has been continuously growing, and many studies have demonstrated its positive results on bone tissue healing after dental extraction, bone fractures, orthodontic treatments, and implant placement [2, 3]. When laser light enters the tissue and is absorbed, i.e. triggers biochemical processes that lead to activation of the mitochondrial chain and cell activities. LLLT induces proliferation of fibroblasts and production of collagen and increases enzyme activity and vascularisation of the treated area [3]. LLLT is painless and non-invasive, has no adverse effects, and there are almost no contraindications for its use [4].

Although LLLT is widely used, its effects on bone are still controversial. It is thought that LLLT stimulates bone through activation of osteoblasts, which induce faster formation and maturation of young bone. Yet, there is no universal opinion regarding the use of specific therapeutic dosage and time. Unlike pharmaceutical agents, LLLT involves a wide range of parameters in terms of laser properties and dosage, which has been shown to be important for the effects to occur. Under-dosage results in poor cellular response, but overdosage may paradoxically inhibit cell proliferation or induce apoptosis.

Different laser types with different wavelengths, including helium–neon (He-Ne), gallium aluminium arsenide (GaAlAs), and gallium arsenide (GaAs), have been used at different doses and different treatment schedules for the LLLT. In recent studies, the GaAlAs type of diode lasers has been shown to be more effective in bio-stimulation than He-Ne lasers due to the higher penetration ability into the deep tissues [5, 6]. The dose-dependent nature of LLLT results in stimulating effects at low doses

Received • Примљено:

September 22, 2022

Revised • Ревизија:

December 28, 2022

Accepted • Прихваћено:

December 29, 2022

Online first: January 11, 2023

Correspondence to:

Radmila OBRADOVIĆ
Faculty of Medicine
University of Niš
Department of Oral Medicine and
Periodontology
Bledska 2/19
18000 Niš
Serbia
dr.rada@yahoo.com

(0.05–10 J/cm²), while higher doses (over 10 J/cm²) lead to bio-inhibition. It is difficult to compare studies about LLLT of bone because the dosage parameters, models, and duration of therapy are very distinct [2]. Thus, it is important that the cellular effects of LLLT are better understood and considered before formulation of clinical treatment protocols. Research is currently in progress and leads to finding common ground with universal recommendations for LLLT in everyday dental practice.

The aim of this study was to histomorphometrically investigate the influence of the LLLT on bone repair of artificial bone defects made in the rat mandible.

METHODS

This prospective randomized trial was carried out at the Faculty of Medicine, University of Niš, for nine weeks. The study was conducted according to the ethical principles in animal experimentation of the International Council for Laboratory Animal Science and the Committee for the Purpose of Control And Supervision of Experiments on Animals [7]. The study protocol was approved by the Faculty of Medicine Institutional Ethics Committee (No. 01-2800-7).

Sixty healthy white female rats of Wistar type, age 10 weeks, participated in the study. All of the animals were prepared for intervention by applying diazepam (Bensedin, ICN Galenika, Belgrade, Serbia) at a dose of 1.5 ml per animal and anesthetized with ketamine hydrochloride USP (Ketalar, Rotexmedica GmbH, Trittau, Germany) at a dose of 0.5 ml per animal. Later on, defects 1.2 mm in diameter and 1.5 mm deep were made in the region between the medial line and mental foramen (region of maximum load in the mandible of rats) on the right side of the mandible. The animals were then divided into two equal groups. In the study group, the implantation site was submitted to GaAlAs laser irradiation (model Mils 94, Optica Laser, Sofia, Bulgaria), using 670 nm, power 5 mW, 4 minutes per day, for five consecutive days. The control group of animals had no postoperative treatment. Defects in the mandible were not large and did not require postoperative analgesia, nor were a threat of infection due to good vascularization of the treated area. Periodontal flap operation was a model after which the bone preparations in rat mandible were made, and it did not require the use of analgesics or antibiotics. The animals were kept in cages under appropriate conditions of light and temperature, and had water and food *ad libitum* according to institutional guidelines relating to animal experiments. The postoperative period was with no adverse consequences.

Animals were sacrificed two, six, and eight weeks post LLLT, with profound sedation and overdose of ketamine and xilazine, 0.5 ml each. Bone samples of the mandible, from the medial line to the mental foramen, were cut in the vestibulo-oral direction, washed in physiological solution, and fixed in 10% formaldehyde. Chemical decalcification was performed in a 15% solution of nitric acid, and the decalcification time ranged 24–72 hours. Decalcification

by electrolysis was performed in an electrophoresis power supply MA 8903 apparatus (Elektronska industrija, Niš, Serbia), in an aqueous solution of 8% concentrated hydrochloric acid and 10% formic acid. The decalcification process by electrolysis was carried out for two hours at a voltage of 100 V and a current of 50 mA.

Afterwards, the samples were dehydrated in alcohol, molded into paraplast, cut and dyed. Thus 2–4 µm thick histological sections were dyed by haematoxylin-eosin (HE) and PAS methods. Digital pictures (640 × 480 pixels) were taken with a 63 × magnification objective of a NU-2 microscope (Carl Zeiss, Jena, Germany) and analysed by a Lucia 3.2G system (Laboratory Imaging, Prague, Czech Republic).

For histomorphometric analysis, the test area was determined (one field of view of each preparation), which included both the newly created bone tissue and the bone tissue immediately adjacent to the prepared defect. The following were measured: area fraction (the percentage of bone tissue at each visual area); area (the bone area which could be seen at each visual area); integral density (integrally collected optical density of investigated bone part); mean density (mean value of optical density), and density variation (density variation of newly formed compact and spongy bone).

Statistical processing of the results was performed with the SPSS 15.0 program (SPSS Inc., Chicago, IL, USA). MANOVA and t-test have been used for the analysis of the obtained results, which were shown as a mean value and standard deviation. The level of significance was set at $p \leq 0.05$.

RESULTS

After two weeks, histomorphometric analysis of bone revealed statistically higher values of area fraction, bone area, and integral density in the study group, while density variation was statistically higher in the control group (Table 1). A histological analysis of the mandibular cortical alveolar bone after two weeks in the study group showed a noticeable increase in bone tissue, with numerous cement lines and reduction of Haversian canals compared to the cortical bone of the control group of animals (Figure 1).

After six weeks in the study group, submitted to the LLLT, histomorphometric analysis of bone still showed statistically higher values of area fraction, bone area, and integral density compared to the control group – in the study group, an increase in compact and cancellous bone tissue with numerous cement lines was noticeable, compared to the samples of the control group of animals (Figure 2; Table 2).

There was no difference in histomorphometric findings between experimental groups after eight weeks (Table 3).

DISCUSSION

Alveolar bone loss represents a problem in dental rehabilitation. Although bone has good regenerative properties,

Table 1. Mean histomorphometric values of investigated bone after two weeks

Variable	Study group	Control group	P
	$\bar{x} \pm SD$		
area fraction (%)	0.59 ± 0.32	0.39 ± 0.16	< 0.05
area (µm ²)	16,213.41 ± 3,133.04	11,072.31 ± 3,071.47	< 0.05
integral density (a.u.)	1,031,998.54 ± 42,443.07	82,724.4 ± 10,222.92	< 0.05
mean density (g/cm ²)	0.29 ± 0.06	0.27 ± 0.03	n.s.
density variation	0.02 ± 0.02	0.05 ± 0.02	< 0.05

Table 2. Mean histomorphometric values of experimental bone after six weeks

Variable	Study group	Control group	p
	$\bar{x} \pm SD$		
area fraction (%)	0.78 ± 0.06	0.58 ± 0.16	< 0.05
area (µm ²)	133,810.9 ± 12,007.13	108,499.9 ± 26,455.46	< 0.05
integral density (a.u.)	143,883.6 ± 20,550.68	1,100,468 ± 28,079.01	< 0.05
mean density (g/cm ²)	0.28 ± 0.03	0.28 ± 0.02	n.s.
density variation	0.08 ± 0.01	0.08 ± 0.02	n.s.

Table 3. Mean histomorphometric values of experimental bone after eight weeks

Variable	Study group	Control group	P
	$\bar{x} \pm SD$		
area fraction (%)	0.78 ± 0.17	0.68 ± 0.22	n.s.
area (µm ²)	136,174.4 ± 32,014.07	127,461.6 ± 36,342.66	n.s.
integral density (a.u.)	155,337.1 ± 55,853.52	133,247.3 ± 40,935.74	n.s.
mean density (g/cm ²)	0.28 ± 0.11	0.28 ± 0.04	n.s.
density variation	0.08 ± 0.35	0.08 ± 0.03	n.s.

a 650-nm wavelength increases orthodontic tooth movement more than other wavelengths (405 nm, 532 nm, and 940 nm). A similar wavelength was used in our investigation (670 nm).

It is widely accepted today that inflammation and bone resorption are basic responses of periodontal tissue to damage. LLLT reduces gingival inflammation, and many studies indicate that LLLT has capacity to alter bone cellular behaviour [8, 11]. Faster callus formation, revascularization, promotion of bone formation and denser trabecular networks have also been reported [12]. Liu et al. [13] investigated the healing of rat tibiae fractures irradiated with a low-level laser (830 nm, CW, 40 J/cm² once daily for five weeks) and suggested that LLLT causes an increase in callus volume. Lirani-Galvão et al. [14] investigated the effects of LLLT (GaAlAs laser, 780 nm, 30 mW) on bone repair in rats and noticed a significant increase in osteoblast number. Nagasawa et al. [15] irradiated bone defects with GaAlAs laser and noticed the active formation of spongy bone. Diker et al. [9] showed, through histomorphometry, that applying 10 sessions of LLLT

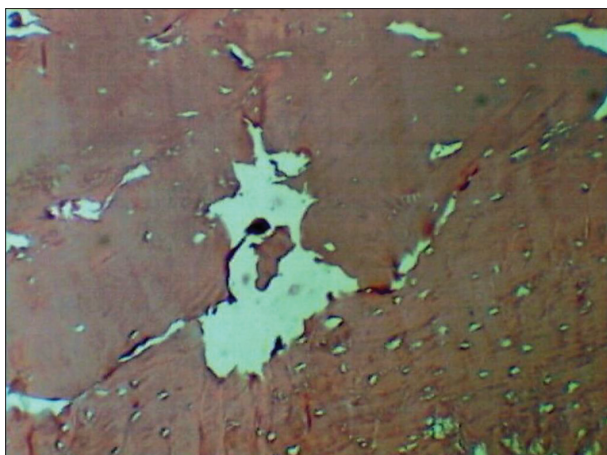


Figure 1. Intensive osteogenesis of compact bone two weeks after the completed low-level laser treatment; 25 ×

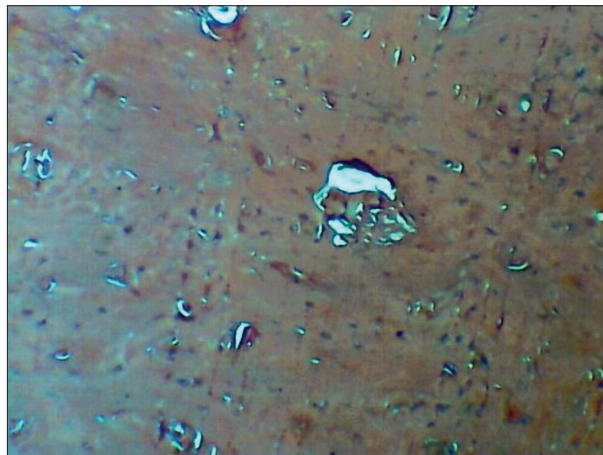

Figure 2. Osteogenesis of compact bone six weeks after the completed low-level laser treatment; 25 ×

its repair capacity may be impaired due to mechanical instability and the presence of other tissues with higher proliferative activity. The use of several techniques, including LLLT, has been studied in order to improve regeneration of alveolar bone and upgrading routine dental rehabilitation [8, 9]. In periodontal, oral, and maxillofacial rehabilitation, application of LLLT for assisting the treatment with bone grafts, distraction osteogenesis, peri-implant tissue healing, and wound healing, becomes an emerging trend, and has shown promising results [9]. It includes wavelengths 500–1100 nm and a dose of 1–4 J/cm², using lasers with output powers of 5–90 mW. The infrared portions of the spectrum have been shown to provide the best therapeutic results [2, 10]. Keklicki et al. [2] noticed that LLLT with

stimulated osteoblastogenesis in bone defects of diabetic rats. Taha et al. [16] showed that LLLT (970 nm) could enhance the bone healing mechanisms and improve the outcome of the treatment in an animal study. These histological findings are similar to findings from our study, which emphasize the stimulating effect of LLLT on bone healing and reparation.

LLLT can stimulate bone cellular proliferation, which reflects osteoblastic activity. It is assumed that depending on the phase of bone repair, LLLT can accelerate bone resorption or formation [17, 18]. Prado et al. [1] evaluated *in vivo* osteogenesis on rough treated dental implants alone or in association with LLLT. LLLT was applied for seven days at the surgical site before and after placing the

implant. Bone-implant contact was measured after one, two, and six weeks using scanning electron microscopy and energy dispersion spectrophotometry. In short periods, significantly greater bone-implant contact was noticed. The investigators concluded that inducing cellular stimulation and improving bone-implant contact in short-term healing should be considered in clinical practice due to low cost and high effectiveness of the LLLT [1]. In our research, similar results have been shown through histomorphometric parameters during the investigated period of two and six weeks. In contrast, no differences between the groups were noticed during the later-investigated period of eight weeks. Pretel et al. [18] evaluated bone repair in artificially made rat mandible defects in three evaluation periods (15, 45, and 60 days) after stimulation with infrared LLLT. The histological results showed an advanced bone tissue response compared to the control group, abbreviating the initial inflammatory reaction and promoting rapid new bone matrix formation at 15 and 45 days. There were no significant differences between the groups after 60 days. The authors concluded that LLLT showed a stimulating effect on bone remodelling by stimulating modulation of the initial inflammatory response. In our study, histomorphometric analysis revealed statistically higher values of bone area fraction, bone area, and integral density in the group submitted to LLLT. Based on the obtained results, it has been noticed that LLLT's beneficial effect was more pronounced in a shorter investigated period [19]. However, it is still difficult to compare LLLT studies on bone due to different dosimetrical parameters, experimental models and duration of treatments [4, 20, 21].

The treatment protocol used in our study is in agreement with other authors, as no existing LLLT parameters are universally accepted [1]. It is possible that laser

treatment's effect on bone regeneration depends not only on the total dose of irradiation but also on the duration and mode of irradiation. Further studies are needed to determine optimal parameters, particularly dosage and treatment period, to establish universal recommendations for the use of LLLT in everyday dental practice. The increase of knowledge about the low-level laser influence on regeneration and reparation of bone defects creates a sound basis for a broader application of this therapeutic procedure that involves the implantation of artificial bone in regeneration. In such a way, impaired regeneration present in patients with poor general health, like in certain systemic diseases, could be successfully overcome and regeneration of alveolar bone achieved.

CONCLUSION

Histomorphometric analysis of artificially made defects in rat mandible revealed that low-level lasers have a stimulating effect on reparatory mechanisms in the early bone regeneration stage, after two and six weeks of the applied treatment. No beneficial laser effect was noticed after an investigated period of eight weeks. These findings suggest that LLLT can be useful as a helping method in the early stages of alveolar bone regeneration.

ACKNOWLEDGEMENT

This study was supported by the grant from the Internal Project No. 47 of the Faculty of Medicine, University of Niš.

Conflict of interest: None declared.

REFERENCES

- Prado RF, Anka MVEA, Griti BDA, Santos ELS, Tini IRP, Ramos CJ, et al. CaP coating and low-level laser therapy to stimulate early bone formation and improve fixation of rough treated implants. *Implant Dent.* 2018;27(6):660–6. [DOI: 10.1097/ID.0000000000000824] [PMID: 30281536]
- Keklicki HB, Yagci A, Yay AH, Goktepe O. Effects of 405-, 532-, 650-, and 940-nm wavelengths of low-level laser therapies on orthodontic tooth movement in rats. *Prog Orthod.* 2020;21(43):2–14. [DOI: 10.1186/s40510-020-00343-3] [PMID: 33258041]
- Cunha JLS, de Carvalho FMA, Filho RNP, Ribeiro MAG, de Albuquerque-Junior RLC. Effects of different protocols of low-level laser therapy on collagen deposition in wound healing. *Braz Dent J.* 2019;30(4):317–74. [DOI: 10.1590/0103-6440201902400] [PMID: 31340220]
- Fini MB, Olyaei P, Homayouni A. The effect of low-level laser therapy on the acceleration of orthodontic tooth movement. *J Lasers Med Sci.* 2020;11(2):204–11. [DOI: 10.34172/jlms.2020.34] [PMID: 32273964]
- Al-Shamiri HM, Al-Maweri SA, AlAhmary AW, Aljunayh MS, Aldosari AO, Alqahtani NM, et al. Efficacy of laser therapy for alveolar osteitis: a systematic review of the available evidence. *J Evid-Based Dent Pr.* 2022;22(2):101711. [DOI: 10.1016/j.jebdp.2022.101711]
- Çirak E, Ozyurt A, Peker T, Ömeroğlu S, Güngör MN. Comparative evaluation of various low-level laser therapies on bone healing following tooth extraction: An experimental animal study. *J CranioMaxill Surg.* 2018;46(7):1147–52. [DOI: 10.1016/j.jcms.2018.05.012] [PMID: 29805068]
- International Council for Laboratory Animal Science (ICLAS). Available at: www.iclas.org. [Date accessed: April 29, 2022]
- Alinica SB, Saglam E, Celik TZ, Haciosalihoglu P, Dogan MA. Is low level laser therapy or ozone therapy more effective for bone healing? Understanding the mechanisms of HIF-1 α , RANKL or OPG. *Biotech Histochem.* 2020;95(8):597–604. [DOI: 10.1080/10520295.2020.1743360] [PMID: 32292090]
- Diker N, Aytac D, Heklvacioglu F, Dagdelen C, Oguz Y. Evaluation of the effects of low-level laser therapy on diabetic bone healing. *J Craniofac Surg.* 2019;30(7):1994–8. [DOI: 10.1097/SCS.00000000000005654] [PMID: 31232987]
- Jafarpour T, Smith F. Design of multi-wavelength low-level laser therapy device for assisting bone reconstruction applications. *Majlesi J Electr Eng.* 2020;14(2):117–25. Available at: https://mjee.isfahan.iau.ir/article_696412_aa66ffbd0b3851ead7b50eb54c18a0f8.pdf
- Ribeiro LNS, de Figueiredo FAT, da Silva Mira PC, Arez MFM, Matsumoto MAN, de Menezes LM, et al. Low-level laser therapy (LLLT) improves alveolar bone healing in rats. *Lasers Med Sci.* 2022;37(2):961–9. [DOI: 10.1007/s10103-021-03340-y] [PMID: 34002343]
- Dhiman S, Khan S. Effect of low-level laser therapy (LLLT) on orthodontic tooth movement – cellular level. *Adv Dent & Oral Health.* 2018;7(5):1–5. [DOI: 10.19080/ADOH.2018.07.555723]
- Liu X, Lyon R, Meier HT, Thometz J, Haworth ST. Effect of low-level laser therapy on rabbit tibial fracture. *Photomed Las Surg.* 2007;25(6):487–94. [DOI: 10.1089/pho.2006.2075] [PMID: 18158750]

14. Lirani-Galvão AP, Jorgetti V, da Silva OL. Comparative study of how low-level laser therapy and low-intensity pulsed ultrasound affect bone repair in rats. *Photomed Las Surg.* 2006;24(6):735–40. [DOI: 10.1089/pho.2006.24.735] [PMID: 17199474]
15. Nagasawa A, Negishi A, Kato K. Clinical applications of LLLT in dental and oral surgery in the Urawa Clinic. *Laser therapy. An Int J of Low Level Laser Therapy.* 1991;3(3):119–21. [DOI: 10.5978/islm.91-OR-17]
16. Taha SK, Abd El Fattah S, Said E, Abdel-Hamid MA, Nemat AH, Shenawy HE. Effect of laser bio-stimulation on mandibular distraction osteogenesis: an experimental study. *J Oral Maxillofac Surg.* 2018;76(11):2411–21. [DOI: 10.1016/j.joms.2018.04.030] [PMID: 29856939]
17. Zheng J, Yang K. Clinical research: ow level laser therapy in accelerating orthodontic tooth movement. *BMC Oral Health.* 2021;21(1):324. [DOI: 10.1186/s12903-021-01684-z] [PMID: 34182967]
18. Pretel H, Lizarelli RFZ, Ramalho LTO. Effect of low-level laser therapy on bone repair: histological study in rats. *Las Surg Med.* 2007;39(10):788–96. [DOI: 10.1002/lsm.20585] [PMID: 18081142]
19. Farzan A, Khaleghi K, Pirayesh Z. Effect of low-level laser therapy on bone formation in rapid palatal expansion: A systematic review. *J Lasers Med Sci.* 2022;13:e13. [DOI: 10.34172/jlms.2022.13] [PMID: 35996494]
20. Hanna R, Dalvi S, Amaroli A, De Angelis N, Benedicenti S. Effects of photobiomodulation on bone defects grafted with bone substitutes: A systematic review of in vivo animal studies. *Journal Biophotonics.* 2021;14(1):e202000267. [DOI: 10.1002/jbio.202000267] [PMID: 32857463]
21. Khalil NM, Noureldin MG. Comparison of single versus multiple low-level laser applications on bone formation in extraction socket healing in rabbits (histologic and histomorphometric study). *J Oral Maxillofac Surg.* 2019;77(9):1760–8. [DOI: 10.1016/j.joms.2019.03.037] [PMID: 31042458]

Ефикасност ласера мале снаге у репарацији коштаних дефеката

Радмила Обрадовић¹, Сања Вујовић², Јана Десница², Момир Стевановић², Драгана Станишић², Ирена Огњановић², Мирко Микић³, Боривој Бијелић⁴, Љиљана Шубарић⁵, Владан Ђорђевић⁶

¹Универзитет у Нишу, Медицински факултет, Ниш, Србија;

²Универзитет у Крагујевцу, Факултет медицинских наука, Крагујевац, Србија;

³Универзитет у Црној Гори, Медицински факултет, Подгорица, Црна Гора;

⁴Универзитет у Београду, Стоматолошки факултет, Београд, Србија;

⁵Универзитет у Приштини – Косовска Митровица, Медицински факултет, Косовска Митровица, Србија;

⁶Универзитет у Травнику, Фармацеутско-здравствени факултет, Травник, Федерација Босне и Херцеговине, Босна и Херцеговина

САЖЕТАК

Увод/Циљ Ресорпција кости представља чест проблем у стоматологији, а тешко се постиже надокнада коштаног ткива. Као нови терапијски приступ у побољшању регенерације кости сада се препоручују различите технике коштане трансплантације и третман ласером мале снаге (*low-level laser treatment – LLLT*).

Циљ овог истраживања је био да се хистоморфометријски испита утицај *LLLT* на регенерацију кости вештачки направљених коштаних дефеката мандибуле пацова.

Метод У истраживању је учествовало 60 пацова женског пола. После препарације коштаних дефеката доње вилице, животиње су подељене у две групе од по 30 животиња. У студијској групи, место имплантације је подвргнуто зрачењу ласером *GaAlAs 670 nm, 5 mW*, четири минута дневно, пет дана, док у контролној групи није било постоперативног

третмана. Животиње су жртвоване после две, шест и осам недеља од завршене *LLLT*. Исечци су хистоморфометријски анализирани мерењем ареалне фракције кости, ареје кости, интегрисане густине, средње густине и варијације густине. **Резултати** Хистоморфометријска анализа је показала статистички значајно веће вредности ареалне фракције, ареје и интегрисане оптичке густине у групи подвргнутој ласеротерапији после две и шест недеља. Није уочено посебно дејство ласера у периоду после осам недеља.

Закључак Ласери мале снаге имају биостимулативни ефекат на процесе репарације у раној фази регенерације вештачки направљених дефеката кости мандибуле пацова и могу се користити као помоћно средство у третману кости.

Кључне речи: кост; терапија ласерима мале снаге; остео-генеза