



CASE REPORT / ПРИКАЗ БОЛЕСНИКА

Bilateral atypical femoral fracture related to bisphosphonate therapy

Aleksandra Savić^{1,2}, Radmila Matijević^{2,3}, Dragan Savić^{2,3}, Jelena Miok⁴, Aleksandra Glavčić^{1,2}¹Special Hospital for Rheumatic Diseases, Novi Sad, Serbia;²University of Novi Sad, Faculty of Medicine, Novi Sad, Serbia;³Clinical Center of Vojvodina, Clinic for Orthopedic Surgery and Traumatology, Novi Sad, Serbia;⁴Dr Miličević Internal Medicine Practice, Novi Sad, Serbia**SUMMARY**

Introduction Although bisphosphonates represent the most commonly prescribed antiresorptive therapy for the treatment of osteoporosis and fracture prevention, paradoxically, their continuous use in some patients can lead to an atypical femoral fracture. This type of fracture is characterized by specific features regarding clinical presentation, mechanism of injury and radiological manifestations. The objective of this article was to present a case of a bilateral femoral fracture associated with bisphosphonate usage.

Case outline A 70-year-old female patient was admitted to the emergency department with a severe, throbbing pain in both thighs after a ground-level fall. Radiographs of both femurs verified bilateral complete fracture localized in the diaphyseal region. Prior to hospitalization, she had continuously been taking ibandronate for three years. The patient underwent percutaneous osteosynthesis with intramedullary nailing with interlocking screws of both femurs. Six weeks after the surgical treatment, radiographic findings indicated the presence of early signs of healing on both femurs. At the four-month follow-up, the complete union of the bone fragments was achieved and she managed to walk without any pain and walking aids.

Conclusion Physicians still face doubts regarding optimal duration of bisphosphonate therapy. Although atypical femoral fracture represents a rare adverse event related to bisphosphonate use, all patients receiving this antiresorptive treatment who are complaining of new-onset unexplained pain in the thighs for more than two weeks should be completely diagnostically evaluated in term of atypical femoral fracture. Patients with confirmed atypical femoral fracture should undergo surgical treatment.

Keywords: osteoporosis; antiresorptive treatment; intramedullary nailing

INTRODUCTION

Considering the steady trend of prolongation of the average life expectancy, a decrease in bone density, osteoporosis, continues to be a health concern for the growing elderly population [1]. Although the available therapeutic modalities have shown to be effective in treating this skeletal disorder, the rare adverse event associated with antiresorptive therapy is an atypical femoral fracture (AFF) [2]. AFF represents a stress fracture following minimal or no trauma with a fracture line being localized distal to the lesser trochanter and proximal to the supracondylar flare of the thigh bone [3]. Despite the fact that bisphosphonates are usually the treatment of choice for patients suffering from osteoporosis, AFF develops more commonly in patients on bisphosphonate therapy. Additionally, prolonged treatment duration with this type of medications increases risk of fracture [4]. It has been hypothesized that their use could potentially lead to the severe suppression of bone turnover, which eventually causes accumulation of microdamage and consequent change in bone structure [5].

In this article, we report a case of a bilateral femoral fracture affiliated with bisphosphonate usage.

CASE REPORT

A 70-year-old female patient was presented to the emergency department with severe, throbbing pain in both thighs after a ground-level fall. The patient gave a history of preexisting dull aching pain over both thighs that lasted four months before admission to the hospital. She was diagnosed with osteoporosis three years prior to hospitalization. The diagnosis was established after a mechanical provocation which led to a vertebral fracture at the level of L2–L3. She was continuously taking ibandronate tablets in the monthly dose of 150 mg for three years. Apart from bisphosphonate therapy she was on a thyroid hormone replacement therapy due to a total thyroidectomy. Her medical history was positive for iatrogenic hypothyroidism. The patient was a smoker and her body mass index (BMI) was 22 kg/m².

Physical examination revealed presence of a bilateral deformity as well as tenderness to palpation over both thigh regions. Active and passive motion of hip and knee joint were limited due to the pain. On admission, lower extremities were neurovascularly intact.

Radiographic examination verified the presence of a bilateral complete fracture localized at the level of the diaphysis. Regarding the

Received • Примљено:

December 3, 2021

Revised • Ревизија:

May 12, 2022

Accepted • Прихваћено:

July 1, 2022

Online first: July 8, 2022**Correspondence to:**

Aleksandra SAVIĆ
Special Hospital for Rheumatic
Diseases
Futoška 68
21112 Novi Sad
Serbia
aleksandra_savic@uns.ac.rs

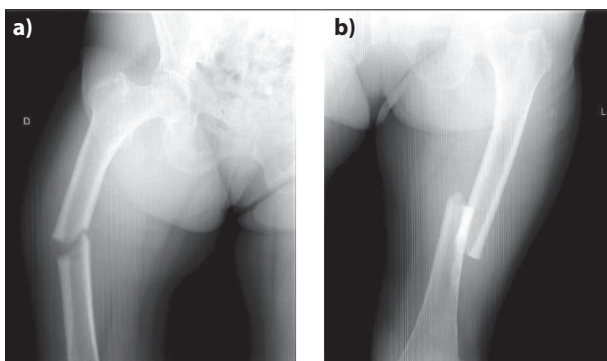


Figure 1. Radiographs showing complete fracture at the diaphysis on the right (a) and left (b) femur

Table 1. Laboratory and DXA assessment

Parameters	Value
Intact parathyroid hormone (pg/mL)	66.5
25(OH)D total (nmol/L)	84
tP1NP (ng/mL)	262.1
CrossLaps (pg/mL)	561
DXA scan	
T score L1-L4	-3.3
BMD (g/cm ²)	0.787

tP1NP – total procollagen 1 amino-terminal propeptide;
DXA – bone density test

fracture configuration, fracture lines were initially transverse with an oblique segment at the medial aspect of both femurs, without comminution (Figure 1.). The results obtained by analysis of the complete blood count as well as the biochemical panel were within the reference range.

When the diagnosis of an AFF was confirmed, antiresorptive treatment was stopped and patient underwent percutaneous osteosynthesis with intramedullary nailing with interlocking screws of both femurs.

Intraoperative and postoperative course was uneventful. After discontinuation of bisphosphonate, laboratory and Bone Density Test (DXA) assessment were carried out and the results are presented in the Table 1. She was commenced on vitamin D and calcium supplement therapy. The patient was discharged home on the seventh postoperative day in a good general health condition.

Six weeks after surgery, radiographic findings indicated the presence of early signs of healing on both femurs (Figure 2 a) and b)) and the patient was allowed to walk with a walker bearing her weight. At four months follow-up, the complete union of the bone segments was achieved and she managed to walk without any pain and walking aids (Figure 2 c) and d)). On further medical checkup, six months postoperatively, she did not report any ailment and the mobility of the hip joints reached a satisfactory level of recovery. Differences in quality of life before and after the surgery were measured by Short Form Health Survey (SF-36) and scores are shown in Table 2.

One year after the operation, due to the high risk of fracture as well as presence of osteoporosis on lumbar vertebrae revealed in DXA scan, alendronate was introduced to therapy.

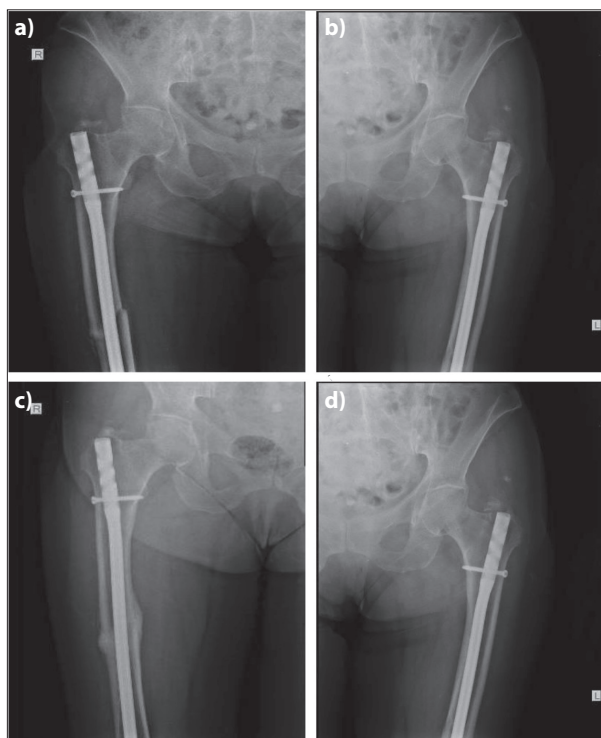


Figure 2. Radiographs showing the presence of early signs of healing six weeks after surgery [(a) and (b)] and complete union on both femurs four months postoperatively [(c) and (d)]

Table 2. Short Form Health Survey (SF-36) scores

Short Form Health Survey (SF-36)	Before	After
Physical functioning (%)	15	65
Role limitations due to physical health (%)	0	50
Role limitations due to emotional problems (%)	33.3	100
Energy/fatigue (%)	40	70
Emotional well-being (%)	56	80
Social functioning (%)	50	75
Pain (%)	22.5	77.5
General health (%)	35	55
Health change (%)	0	75

DISCUSSION

In clinical practice, the most commonly used group of medicines for the treatment of osteoporosis and fracture prevention are bisphosphonates. Although generally well tolerated and effective, paradoxically, bisphosphonate therapy in some patients can cause AFF. They interfere with bone remodeling processes leading to changes in the mechanical and regenerative properties of bone [6]. Management of osteoporosis with bisphosphonates is followed by high relative risk of developing AFF, ranging from 2.1 to 128, while the absolute risk expressed numerically ranges from 3.2 to 50 cases per 100,000 person per year. Prolongation of therapy correlates with a significantly increased risk which was observed to be 100 cases per 100 000 person per year [3]. The mechanisms of AFF's development have still not been completely understood. It is assumed that bisphosphonates are responsible for the irregular and increased collagen cross-linking, which leads

to the formation of focal zones of dense and brittle bone, mostly in the subtrochanteric region, which is sensitive to the high tensile and compressive forces. Low bone turnover in these zones causes microdamage accumulation which subsequently progresses to fracture [7].

There are still no clear guidelines regarding the optimal duration of a bisphosphonate therapy. Prolonged retention at the bone surface can be explained by their high affinity for hydroxyapatite [8]. Although current guidelines suggest that after five years of treatment with bisphosphonates patient should undergo reevaluation and therapy should be stopped, study conducted by Lo et al. [9] demonstrated that patients receiving this therapy are at higher risk for AFF even after three years of continual antiresorptive treatment.

In 2010, the Task Force of the American Society for Bone and Mineral Research (ASBMR) defined the major and minor criteria following diagnosis of AFF, which were afterwards revised and published in 2014. In the case of AFF, localization is essential for diagnosis and the fracture line is placed in the diaphysis region somewhere distal to the lesser trochanter to just proximal to the supracondylar flare. To diagnose AFF presence of four major features out of five is required, that may or may not be accompanied with minor features. Major features are: association with no or minimal trauma, no or minimal comminution, involvement of the lateral cortex in both, complete and incomplete fracture, though complete fracture might be associated with a medial spike, transverse fracture line with the potential oblique orientation medially, localized periosteal or endosteal thickening at the lateral cortex (“beaking” or “flaring”). Minor features include generalized cortical thickening of the femoral shaft, bilaterality, prodromal symptoms (pain in the groin or thigh) and prolongation of healing time [3]. The fractures in this report were consistent with all of the major and with a few of the minor features. Considering previously mentioned minor features, our patient complained of pain in both thighs prior to the fall and she experienced bilateral femoral fracture. Therefore, diagnosis of a bisphosphonate induced AFF was made.

Koh et al. [10] demonstrated that duration of bisphosphonate therapy for more than five years without pause period, prolonged use of glucocorticoids and a higher BMI increase the risk of AFF. Findings of another research article were consistent with previously mentioned predisposing factors, although authors reported that Asian race also has an additional impact on the increase of the fracture incidence [11]. Rheumatoid arthritis, increased anterior and lateral femoral curvatures and thicker lateral femoral cortex of diaphysis were recognized as a possible

contributor for development of an AFF as well [12]. None of the listed risk factors were present in our patient.

Several factors determine the therapeutic approach: type of a fracture (complete or incomplete), presence of symptoms and the general condition of the patient. A conservative treatment may be the option for asymptomatic patients with incomplete AFF. Indication for intramedullary nail fixation is complete fracture or incomplete fracture associated with pain [13]. Other criteria that should be considered in patients with incomplete fracture are the extent and depth of the fracture line, presence of symptoms, and patient's choice [2]. Endochondral ossification is a process responsible for the union of bone fragments in patients with complete fractures. The bone remodeling, as a stage of endochondral ossification, is essential for union of the stress fracture segments. Bisphosphonates inhibit remodeling through suppression of the osteoclast mediated bone resorption. Intramedullary reconstruction full-length nails provide regenerative processes to take place inside fracture crack [13].

According to a study conducted by Kim et al. [14], after the operation, patients achieved radiological union between three to 10 months with an average of 5.5 months. Kang et al. [15] demonstrated that observed healing time differed according to the duration of therapy. Fracture union was achieved in 4.8 ± 2.5 months in patients who taken bisphosphonates for less than three years, but the time required for healing was 9.3 ± 3.7 months in those who taken antiresorptive therapy for more than three years. In our patient the time required for healing was four months.

An observational follow-up study was conducted in order to investigate the incidence of new fragility fractures following an AFF. Results demonstrated that in a group of patients who sustained an AFF incidence of fractures was high. The majority of reported fractures were located on vertebrae, hip, humerus or forearm. In patients with high risk of fragility fractures bisphosphonates or denosumab might be continued after the completion of healing process in surgically managed bilateral AFFs [16].

In conclusion, physicians still face doubts regarding optimal duration of bisphosphonate therapy. Although AFF represents a rare adverse event related to bisphosphonate use, all patients receiving this antiresorptive treatment who are complaining of new-onset unexplained pain in the thighs for more than two weeks should be completely diagnostically evaluated in term of AFF. Patients with confirmed AFF should undergo surgical treatment.

Conflict of interest: None declared.

REFERENCES

- Hagino H, Uemura Y, Mori S, Sone T, Ohta H, Nakamura T. Risk factors for incident vertebral fractures in osteoporosis pharmacotherapy: a 2-year, prospective, observational study. *J Bone Miner Metab.* 2021;39(4):668–77. [DOI: 10.1007/s00774-021-01208-3] [PMID: 33738617]
- Tile L, Cheung AM. Atypical femur fractures: current understanding and approach to management. *Ther Adv Musculoskelet Dis.* 2020;12:1759720X20916983. [DOI: 10.1177/1759720X20916983] [PMID: 32913448]

3. Shane E, Burr D, Abrahamsen B, Adler RA, Brown TD, Cheung AM, et al. Atypical Subtrochanteric and Diaphyseal Femoral Fractures: Second Report of a Task Force of the American Society for Bone and Mineral Research. *J Bone Miner Res.* 2014;29(1):1–23. [DOI: 10.1002/jbmr.1998] [PMID: 23712442]
4. Papapoulos S, Bone H, Cosman F, Dempster DW, McClung MR, Nakamura T, et al. Incidence of Hip and Subtrochanteric/Femoral Shaft Fractures in Postmenopausal Women With Osteoporosis in the Phase 3 Long-Term Odanacatib Fracture Trial. *J Bone Miner Res.* 2021;36(7):1225–34. [DOI: 10.1002/jbmr.4284] [PMID: 33724542]
5. Zenke Y, Ikeda S, Fukuda F, Tanaka M, Tanaka H, Hirano F, et al. Study of Atypical Femoral Fracture Cases Coupled in a Multicenter Study. *J UOEH.* 2016;38(3):207–14. [DOI: 10.7888/juoeh.38.207] [PMID: 27627968]
6. Lim HS, Kim CK, Park YS, Moon YW, Lim SJ, Kim SM. Factors Associated with Increased Healing Time in Complete Femoral Fractures After Long-Term Bisphosphonate Therapy. *J Bone Joint Surg Am.* 2016;98(23):1978–87. [DOI: 10.2106/JBJS.15.01422] [PMID: 27926679]
7. Sahemey R, Nikolaides AP, Bhattacharya S, Simons A, Makrides P. Bisphosphonate-related atypical femoral fractures: A novel strategy to improve patient outcomes. *J Orthop Trauma Rehabilitation.* 2020;27(2):192–7. [DOI: 10.1177/2210491720952444]
8. Curtis JR, Saag KG, Arora T, Wright NC, Yun H, Daigle S, et al. Duration of Bisphosphonate Drug Holidays and Associated Fracture Risk. *Med Care.* 2020;58(5):419–26. [DOI: 10.1097/MLR.0000000000001294] [PMID: 31985584]
9. Lo JC, Neugebauer RS, Ettinger B, Chandra M, Hui RL, Ott SM, et al. Risk of complete atypical femur fracture with Oral bisphosphonate exposure beyond three years. *BMC Musculoskelet Disord.* 2020;21(1):801. [DOI: 10.1186/s12891-020-03672-w] [PMID: 3327222]
10. Koh JH, Myong JP, Yoo J, Lim YW, Lee J, Kwok SK, et al. Predisposing factors associated with atypical femur fracture among postmenopausal Korean women receiving bisphosphonate therapy: 8 years' experience in a single center. *Osteoporos Int.* 2017;28(11):3251–9. [DOI: 10.1007/s00198-017-4169-y] [PMID: 28748389]
11. Black DM, Geiger EJ, Eastell R, Vittinghoff E, Li BH, Ryan DS, et al. Atypical Femur Fracture Risk versus Fragility Fracture Prevention with Bisphosphonates. *N Engl J Med.* 2020;383(8):743–53. [DOI: 10.1056/NEJMoa1916525] [PMID: 32813950]
12. Lim SJ, Yeo I, Yoon PW, Yoo JJ, Rhyu KH, Han SB, et al. Incidence, risk factors, and fracture healing of atypical femoral fractures: a multicenter case-control study. *Osteoporos Int.* 2018;29(11):2427–35. [DOI: 10.1007/s00198-018-4640-4] [PMID: 30039251]
13. Lee KJ, Min BW. Surgical Treatment of the Atypical Femoral Fracture: Overcoming Femoral Bowing. *Hip Pelvis.* 2018;30(4):202–9. [DOI: 10.5371/hp.2018.30.4.202] [PMID: 30534538]
14. Kim KH, Song G. Intramedullary Nailing for Atypical Femoral Fracture With Lateral Bowing: Does Medial Gap Matter? *Geriatr Orthop Surg Rehabil.* 2022;13:21514593211070130. [DOI: 10.1177/21514593211070130] [PMID: 35464907]
15. Kang JS, Won YY, Kim JO, Min BW, Lee KH, Park KK, et al. Atypical femoral fractures after anti-osteoporotic medication: a Korean multicenter study. *Int Orthop.* 2014;38(6):1247–53. [DOI: 10.1007/s00264-013-2259-9] [PMID: 24464018]
16. Bégin MJ, Audet MC, Chevalley T, Portela M, Padlina I, Hannouche D, et al. Fracture Risk Following an Atypical Femoral Fracture. *J Bone Miner Res.* 2022;37(1):87–94. [DOI: 10.1002/jbmr.4461] [PMID: 34668223]

Обострани атипични прелом фемура повезан са бисфосфонатном терапијом

Александра Савић^{1,2}, Радмила Матијевић^{2,3}, Драган Савић^{2,3}, Јелена Миок⁴, Александра Главчић^{1,2}

¹Специјална болница за реуматске болести, Нови Сад, Србија;

²Универзитет у Новом Саду, Медицински факултет, Нови Сад, Србија;

³Клинички центар Војводине, Клиника за ортопедску хирургију и трауматологију, Нови Сад, Србија;

⁴Специјалистичка интернистичка ординација „Др Милићевић“, Нови Сад, Србија

САЖЕТАК

Увод Иако бисфосфонати представљају најчешће прописивану антиресорптивну терапију за лечење остеопорозе и превенцију прелома, парадоксално, њихова континуирана примена код неких болесника може да доведе до атипичног прелома фемура. Ову врсту прелома одликују специфичне карактеристике у погледу клиничке презентације, механизма повређивања и радиолошких манифестација.

Циљ овог рада је био да се прикаже случај обостраног прелома фемура који је удружен са применом бисфосфоната.

Приказ болесника Седамдесетогодишња болесница примљена је на одељење ургентне медицине због снажног, пулсирајућег бола у обе бутине који је настао после пада на истом нивоу. Радиограмом оба фемура верификован је обострани прелом фемура локализован у регији дијафизе. Она је три године пре хоспитализације у континуитету узимала ибандронат. Болесница је подвргнута перкутаној остеосинтези са интрамедуларним клином и закључавајућим

шрафовима. Шест недеља после оперативног захвата радиографски налаз је указао на присуство раних знакова зарастања на оба фемура. На контролном прегледу после четири месеца коштани уломци су комплетно срасли и болесница је могла да хода без појаве бола и помагала.

Закључак Лекари и даље имају недоумице везане за оптимално трајање терапије бисфосфонатима. Иако атипични прелом бутне кости представља редак нежељени догађај који је удружен са применом бисфосфоната, сви болесници на овој антиресорптивној терапији и који се жале на новонастали бол у бутинама неразјашњене етиологије, а који траје дуже од две недеље, треба да буду потпуно дијагностички обрађени у правцу атипичног прелома фемура. Болесници са потврђеним атипичним преломом бутне кости треба да се подвргну оперативном лечењу.

Кључне речи: остеопороза; антиресорптивна терапија; интрамедуларна фиксација