

## CASE REPORT / ПРИКАЗ БОЛЕСНИКА

# Angiosarcoma of the caecum

Dejan Stevanović<sup>1,2</sup>, Nebojša Mitrović<sup>1,2</sup>, Damir Jašarović<sup>1,2</sup>, Aleksandar Lazić<sup>1,2</sup>, Branko Lukić<sup>2</sup><sup>1</sup>University of Belgrade, Faculty of Medicine, Belgrade, Serbia;<sup>2</sup>Zemun Clinical Hospital Center, Department of General Surgery, Belgrade, Serbia**SUMMARY**

**Introduction** Primary angiosarcomas arising from the digestive system are rare, representing less than 1% percent of the malignant sarcomas. Only a few cases have been reported in the literature. Colorectal involvement is exceedingly uncommon and is a harbinger of a poor prognosis with widespread metastasis. Diagnosis is often delayed due to non-specific symptoms and pathology which mimics other tumors.

**Case outline** A 52-year-old woman was presented to the emergency room in July 2021, complaining of protracted malaise, and rapid fatigue and occasional sweating. Multislice computed tomography (MSCT) of the abdomen and small pelvis revealed the existence of lobular, well vascularized, supravascular lesion, located along the anterior contour of the uterine corpus, in the convolutes of the small intestine. The patient was subjected to operative treatment with curative intent. Intraoperatively, a completely tumor-altered caecum was verified. Standard histopathological examination demonstrated a high grade epithelioid angiosarcoma with severe pleomorphism and solid growth pattern. The control MSCT of abdomen and small pelvis which was done 12 months after the operation did not show the existence of any pathological lesions.

**Conclusion** Both clinical and pathological diagnoses of colorectal angiosarcoma are challenging. Patients are presenting non-specific symptoms, which can lead to mismanagement and late diagnosis. A pathological diagnosis relies on immunohistochemical staining for endothelial markers. In limited tissue biopsies, it can be easily misdiagnosed as poorly differentiated adenocarcinoma or gastrointestinal stromal tumor. For now, surgical treatment with R0 resection seems to be the only effective treatment modality.

**Keywords:** angiosarcoma; caecum; gastrointestinal angiosarcoma; colonic angiosarcoma

**INTRODUCTION**

Primary angiosarcomas arising from the digestive system are rare, representing less than 1% percent of the malignant sarcomas [1]. They usually arise in the stomach and small intestine [2], while colorectal involvement is extremely uncommon and is a harbinger of a poor prognosis with diffuse metastasis [1, 3]. Diagnosis is often delayed due to non-specific symptoms, but also due to pathology which mimics other tumors. Management guidelines are very limited due to tumors rarity.

**CASE REPORT**

A 52-year-old woman presented to the emergency room in July 2021, complaining of protracted malaise, rapid fatigue, and occasional sweating. No other difficulties were listed. The patient was a diabetic with a significant medical history and was hospitalized several times at our Institution, last time three years ago due to myocardial infarction and transient ischemic attack. Since then, the patient has been diagnosed with ischemic heart disease and had been using oral anticoagulant therapy regularly due to the presence of echosonographically-verified thrombus in the apical area of the heart. Also, two years ago she was examined on an

outpatient basis by a hematologist in order to perform tests for thrombophilia – genetic analysis on *MTFHR*, *FII* and *FV Leiden* was negative, and homocysteine was in the reference range. She was instructed to conduct tests for antiphospholipid syndrome, which was not done. The family history was positive for malignancies – both parents had liver cancer.

On examination she was slightly hypotensive (90/50 mmHg), tachycardic (110 beats per minute) with normal body temperature of 36.8°C. The abdomen was slightly distended with hyperactive bowel sounds and without any tenderness. Initial blood analysis revealed leukocytosis with “left shift”, eosinophilia, moderate to severe microcytic anemia and thrombocytosis (leukocytes 51.6; neutrophils  $40.80 \times 10^9/L$ ; eosinophil  $8.60 \times 10^9/L$ ; erythrocytes 3.60; hemoglobin 84; hematocrit 0.282; Tr 642). Inflammatory parameters were elevated (erythrocyte sedimentation 100/1 h, C-reactive protein 225 mg/L, phenolsulfonphthalein 1418 pg/mL, procalcitonin 0.81 ng/mL). Prothrombin time was prolonged (INR 10.64 s) but considered as a consequence of an inadequate dose of warfarin. Urine analyses were normal. Abdominal ultrasound and plain abdominal radiography were without any pathological finding.

The patient was hospitalized at the Hematology Department for further diagnosis and

**Received • Примљено:**

December 31, 2021

**Accepted • Прихваћено:**

September 3, 2022

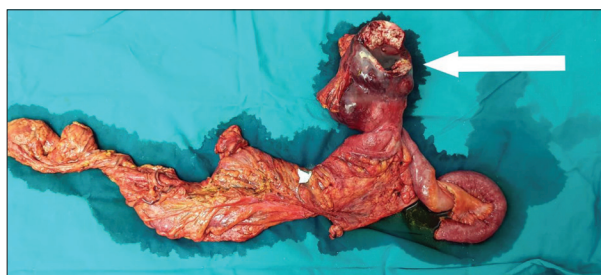**Online first:** September 6, 2022**Correspondence to:**Branko LUKIĆ  
Zemun Clinical Hospital Center  
Vukova 9  
11080 Belgrade  
Serbia  
[branko.lukic@live.com](mailto:branko.lukic@live.com)

treatment. Due to the positive inflammatory syndrome, antibiotic therapy was administered empirically and prolonged prothrombin time was corrected. Bone marrow aspiration and trepanobiopsy were performed and the pathohistological finding was without signs of myeloproliferative and lymphoproliferative disease. The origin of eosinophilia was then investigated. X-ray of the paranasal cavities and ear-nose-throat examination excluded the existence of nasal polyposis. Stool was negative for parasites and to rule out Churg–Strauss syndrome, samples were sent for immunology (antinuclear antibody test, peripheral antineutrophil cytoplasmic antibody test) which came back normal. Esophagogastroduodenoscopy was performed and there were no macroscopic findings to indicate eosinophilic gastritis, as well as the existence of erosions, ulcerations nor neoformations. Computed tomography of the chest did not show the existence of any changes that would indicate granulomatous inflammation. The IgE immunoglobulin titer was in the reference range.

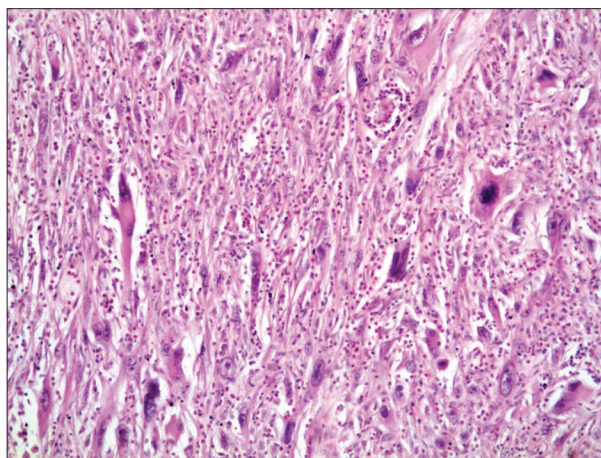
On the sixth day after admission, the patient had a fever for the first time, accompanied by an increase in leukocyte count and inflammatory parameters (leukocytes 77.1, C-reactive protein 236 mg/L). Blood cultures and other bacteriological analyzes, that were taken on several occasions, were sterile. Multislice computed tomography (MSCT) of the abdomen and small pelvis was performed and showed the existence of lobular, well vascularized lesion measuring around  $7 \times 5 \times 8$  cm, located supravescically along the anterior contour of the uterine corpus, in the convolutes of the small intestine, with hypodense zones in the center which differentially diagnostically corresponded to necrosis. She was examined by a gynecologist, and it was determined that the lesion did not belong to the internal genital organs.

Given the above, the patient was transferred to the Department of General Surgery with the intention of performing explorative laparotomy and further surgical procedure according to the intraoperative finding. Intraoperatively, a completely tumor-altered caecum was verified with partially necrotic walls and multiple abscesses within them (Figure 1). Further exploration did not reveal lesions suggestive of secondary deposits. Given the above, a resection was performed in a form right hemicolectomy (Figures 3, 4, and 5) along with local lymphadenectomy and reconstruction with ileo-transverso T-L anastomosis. Standard histopathological examination demonstrated a high grade epithelioid angiosarcoma with severe pleomorphism and solid growth pattern (Figure 2). R0-resection was verified and the presence of tumor tissue was confirmed in none of seven dissected lymph nodes. Patient was staged as  $T_2N_0M_x$ .

The postoperative period was marked by ventricular fibrillation on the fifth postoperative day. The patient was resuscitated and returned to sinus rhythm using direct current cardioversion shock. The rest of the hospitalization was uneventful and after seven days, the patient was discharged. No evidence of complications was noted during first two follow-ups. The control MSCT of the abdomen and small



**Figure 1.** Photograph of the of intraoperative sample; a completely tumor-altered cecum is marked with the arrow



**Figure 2.** High grade epithelioid angiosarcoma with severe pleomorphism and solid growth pattern; round-polygonal epithelioid cells or spindle cells, with vesicular nuclei containing prominent nucleoli; a few cells were observed to have intracytoplasmic lumina containing erythrocytes or bizarre form (H&E; 10 ×)

pelvis which was done 12 months after the operation did not show the existence of any pathological lesions.

We confirm that we have read the journal's position on issues involving ethical publication and affirm that this work is consistent with those guidelines. Written consent to publish all shown material was obtained from the patient.

## DISCUSSION

Angiosarcoma is an aggressive tumor that arises from vascular endothelial cells. It accounts for 1% of all sarcomas and 0.001% of all colorectal malignancies [4]. It can be primary or secondary (metastatic). Roughly 60% primary occur in the skin and superficial soft tissue, but may also occur in the deep soft tissue and parenchymal organs such as the breast, heart, liver, spleen and bone.

Only a few angiosarcomas have been found in the digestive system, with most of them localized in the stomach and small intestine [2]. Colorectal angiosarcoma is a very rare finding. The first case was described in 1949 by Steiner and Palmer [5], and to our knowledge there were less than 40 described cases to this day, most of which were primary [1, 6, 7]. The prognosis is poor as the tumor metastasizes rapidly in more than 70% of cases [1]. The most common sites of metastatic disease are lymph nodes, liver, bone, and lungs, while other localizations are less represented [8].

The etiology of colorectal angiosarcoma is yet unclear. It may be related to long-term exposure to radiation, chemical agents such as polyvinylchloride, thorotrast, and arsenic, as well as a consequence of chronic lymphedema and amyloidosis [9, 10, 11]. Angiosarcoma has also been reported in association with implanted foreign material such as vascular (Dacron) grafts and orthopedic joint prostheses [12, 13, 14], breast implants [15, 16], or in patients with arteriovenous fistulas. [12, 13, 17] According to the findings of recent studies, protracted use of calcium channel blockers may lead to colorectal angiosarcoma [1]. The patient from our report was using calcium channel blockers.

In 2018, Wang et al. [1] summarized the results of 33 previously reported cases. The mean age of patients was 56 years (16–85 years) and the mean tumor size was 5 cm (1.5–12 cm) [1]. The majority of patients (61%) were female [18]. Most reported colorectal angiosarcomas have been localized to the sigmoid colon [1, 6, 7]. Wang et al. [1] reported that sigmoid colon was affected in 36% of cases, rectum in 33%, cecum in 21% of cases, ascending colon in 9%, and the transverse and descending colon in 3% of cases. Before him, Brown et al. [18] had similar results. The most common symptoms are gastrointestinal bleeding and abdominal or perianal pain [6, 7, 11]. Patients may also have symptoms of bowel obstruction and weight loss [6, 7]. Anemia was present in 42% of patients [6, 11]. Our patient had only moderate to severe microcytic anemia.

Patients can be easily misdiagnosed. On endoscopy, the mucosa may look normal or show hypervascularization. It may demonstrate an ulcerated or hemorrhagic, protuberant, near-circumferential mass lesion [8, 19, 20]. Due to the aggressive nature and non-specific symptoms, routine screening colonoscopies may be insufficient for timely assessment of these tumors, and the diagnosis is usually delayed in almost third of the cases [21]. On microscopy, in limited tissue biopsies, angiosarcomas may mimic poorly differentiated carcinomas, gastrointestinal stromal tumor,

leiomyosarcomas, melanomas and sarcomas with epithelioid morphology [20, 22].

Due to its rarity, there are no specific guidelines for the diagnosis or the management, and its high aggressiveness prevents designing an optimal therapeutic approach [1]. Patients with angiosarcoma generally have a poor prognosis, but for now surgical treatment with R0 resection seems to be the only effective treatment modality. Wide margins are recommended because of the often-multifocal nature of angiosarcoma and its invasiveness [6, 21].

The long-term outcomes of adjuvant chemotherapy and radiotherapy remain unclear [1, 21, 23]. Komorowski et al. [24] reported a case involving a 19-year-old patient, who was operated on and later received adjuvant chemotherapy and radiotherapy. After 18 months, the patient had no signs of recurrence [24].

Tumor size and age at presentation have been suggested as prognostic factors that affect the course after treatment and overall survival. Better survival has been associated with tumors which are smaller than 5 cm, as the size has shown to be an independent prognostic factor [18].

Our patient had a tumor measuring nearly 8 cm and was without macroscopically visible secondary deposits. Also, the tumor was not found in any of dissected lymph nodes. The control MSCT of abdomen and small pelvis which was done 12 months after the operation did not show the existence of any pathological lesions.

In conclusion, we can say that both clinical and pathological diagnoses of colorectal angiosarcoma are challenging. Patients are presenting non-specific symptoms, which can lead to mismanagement and late diagnosis. A pathohistological diagnosis relies on immunohistochemical staining for endothelial markers. In limited tissue biopsies, it can be easily misdiagnosed. For now, surgical treatment with R0 resection seems to be the only effective treatment modality.

**Conflict of interest:** None declared.

## REFERENCES

1. Wang Q, Zhao T, Mi BT, Zhang YL, Wei R, Tong HL, et al. Primary Colonic Angiosarcoma Seen in a Patient on Calcium Channel Blocker: A Case Report with Summary Analysis of 32 Other Cases from the Literature. *Am J Case Rep.* 2018;19:254–61. [DOI: 10.12659/ajcr.907287] [PMID: 29511155]
2. Chen YW, Dong J, Chen WY, Dai YN. Multifocal gastrointestinal epithelioid angiosarcomas diagnosed by endoscopic mucosal resection: A case report. *World J Gastroenterol.* 2020;26(29):4372–7. [DOI: 10.3748/wjg.v26.i29.4372] [PMID: 32848340]
3. Jehangir A, Le BH, Shogbesan O. Angiosarcoma of the Colon Presenting with Chronic Diarrhea, Rectal Bleeding, and Pelvic Discomfort. *Cureus.* 2017;9(3):e1117. [DOI: 10.7759/cureus.1117] [PMID: 28451476]
4. Al Beteddini OS, Brenez D, Firket C, Algaba R, Tabech A. Colonic angiosarcoma: A case report and review of literature. *Int J Surg Case Rep.* 2013;4(2):208–11. [DOI: 10.1016/j.ijscr.2012.11.021] [PMID: 23279809]
5. Steiner CA, Palmer LH. Angiosarcoma of the Colon : With Case Report. *Ann Surg.* 1949;129(4):538–42. [DOI: 10.1097/00000658-194904000-00015] [PMID: 17859337]
6. Radić S, Zovak M, Marić AG, Baturina S, Kirigin MS, Krušlin B. Multiple Primary Angiosarcomas of the Colon. *Case Rep Pathol.* 2021;2021:7237379. [DOI: 10.1155/2021/7237379] [PMID: 34545314]
7. Ottaiano A, Santorsola M, Perri F, Pace U, Marra B, Correria M, et al. Clinical and Molecular Characteristics of Rare Malignant Tumors of Colon and Rectum. *Biology (Basel).* 2022;11(2):267. [DOI: 10.3390/biology11020267] [PMID: 35205133]
8. Sherid M, Sifuentes H, Brasky J, Shah DA, Ehrenpreis ED. Clinical and endoscopic features of angiosarcoma of the colon: two case reports and a review of the literature. *J Gastrointest Cancer.* 2013;44(1):12–21. [DOI: 10.1007/s12029-012-9431-0] [PMID: 23397573]
9. Mundt KA, Dell LD, Crawford L, Gallagher AE. Quantitative estimated exposure to vinyl chloride and risk of angiosarcoma of the liver and hepatocellular cancer in the US industry-wide vinyl chloride cohort: mortality update through 2013. *Occup Environ Med.* 2017;74(10):709–16. [DOI: 10.1136/oemed-2016-104051] [PMID: 28490663]
10. Tripke V, Heinrich S, Huber T, Mittler J, Hoppe-Lotichius M, Straub BK, et al. Surgical therapy of primary hepatic angiosarcoma. *BMC Surg.* 2019;19(1):5. [DOI: 10.1186/s12893-018-0465-5] [PMID: 30630447]
11. Said S, Graham RP, Wu TT, Yasir S, Zhang L, Folpe AL. Colonic Angiosarcoma Arising in Association with Amyloid Deposits. *Case Rep Gastrointest Med.* 2020;2020:3780763. [DOI: 10.1155/2020/3780763] [PMID: 32509358]

12. Takamura K, Kobayashi H, Rubin BP, Kondo S, Asami F, Aoyagi R, et al. Aortic Angiosarcoma in Association with Endovascular Aneurysm Repair: Case Report and Review of the Literature. *Am J Case Rep.* 2021;22:e931740. [DOI: 10.12659/AJCR.931740] [PMID: 34118148]
13. Agaimy A, Ben-Izhak O, Lorey T, Scharpf M, Rubin BP. Angiosarcoma arising in association with vascular Dacron grafts and orthopedic joint prostheses: clinicopathologic, immunohistochemical, and molecular study. *Ann Diagn Pathol.* 2016;21:21–8. [DOI: 10.1016/j.anndiagpath.2016.01.002] [PMID: 27040926]
14. Lee JB, Jung JW, Kim WO, Ryoo YW, Lee KJ, Kim SA. Case of Rapidly Progressing Angiosarcoma after Total Hip Arthroplasty. *Ann Dermatol.* 2021;33(4):377–81. [DOI: 10.5021/ad.2021.33.4.377] [PMID: 34341642]
15. Rajan SS, Haider A, Burrell H, Whisker L, Tamimy M, McCulloch T, et al. Primary High-Grade Angiosarcoma of the Breast in a Young Woman With Breast Implants: A Rare Case and a Review of Literature. *Int J Surg Pathol.* 2020;28(8):906–12. [DOI: 10.1177/1066896920924087] [PMID: 32423273]
16. Russo D, Campanino MR, Cepurnaitė R, Gencarelli A, De Rosa F, Corvino A, et al. Primary High-Grade Angiosarcoma of the Breast in a Young Woman With Breast Implants: A Rare Case and a Review of Literature. *Int J Surg Pathol.* 2020;28(8):906–12. [DOI: 10.1177/1066896920924087] [PMID: 32423273]
17. Kakisis JD, Antonopoulos C, Moulakakis K, Taliadoros A, Rontogianni D, Broutzos E, et al. Angiosarcoma of a Thrombosed Arteriovenous Fistula in a Renal Transplant Recipient. *Ann Vasc Surg.* 2019;56:357.e1–357.e4. [DOI: 10.1016/j.avsg.2018.10.014] [PMID: 30500642]
18. Brown CJ, Falck VG, MacLean A. Angiosarcoma of the colon and rectum: report of a case and review of the literature. *Dis Colon Rectum.* 2004;47(12):2202–7. [DOI: 10.1007/s10350-004-0698-5] [PMID: 15657674]
19. Allison KH, Yoder BJ, Bronner MP, Goldblum JR, Rubin BP. Angiosarcoma involving the gastrointestinal tract: a series of primary and metastatic cases. *Am J Surg Pathol.* 2004;28(3):298–307. [DOI: 10.1097/00000478-200403000-00002] [PMID: 15104292]
20. El Chaar M, McQuay N Jr. Sigmoid colon angiosarcoma with intraperitoneal bleeding and early metastasis. *J Surg Educ.* 2007;64(1):54–6. [DOI: 10.1016/j.cursur.2006.09.002] [PMID: 17320808]
21. Keyser D, Masoumy M, Ham PB, Biddinger P, Rahardja A, Legostaev A, et al. Angiosarcoma of the Colon. 2015;111(25):3068–9. [DOI: 10.1177/000313481508100412]
22. Ma J, Yan Y, He X, Yang Z. Case Report Multiple colonic epithelioid angiosarcoma: a case report and review of literature. *Int J Clin Exp Med.* 2018;11(9):10237–43.
23. Fukita Y, Yasuda I, Ishibashi H, Asaki T, Adachi S, Toyomizu M, et al. [Multifocal angiosarcoma of the gastrointestinal tract: a case report]. *Nihon Shokakibyo Gakkai Zasshi.* 2017;114(9):1665–74. Japanese. [DOI: 10.11405/nisshoshi.114.1665] [PMID: 28883296]
24. Komorowski AL, Darasz Z, Kołodziejcki LS, Gruchała A. Primary angiosarcoma of the colon. *Acta Chir Belg.* 2004;104(4):465–7. [PMID: 15469166]

## Ангиосарком цекума

Дејан Стевановић<sup>1,2</sup>, Небојша Митровић<sup>1,2</sup>, Дамир Јашаровић<sup>1,2</sup>, Александар Лазић<sup>1,2</sup>, Бранко Лукић<sup>2</sup>

<sup>1</sup>Универзитет у Београду, Медицински факултет, Београд, Србија;

<sup>2</sup>Клиничко-болнички центар „Земун“, Служба опште хирургије, Београд, Србија

### САЖЕТАК

**Увод** Примарни ангиосаркоми дигестивног система су ретки и чине 1% свих малигних саркома. Само је неколицина случајева описана у литератури. Захваћеност колоректума је изузетно ретка и знак је лоше прогнозе обично због већ постојећих удаљених промена. Дијагноза се често касно поставља због неспецифичних симптома и патолошких налаза који могу имитирати друге туморе.

**Приказ болесника** Жена старости 52 године јавила се на преглед због протраховане малаксалости, брзог умарања и повремених презнојавања. Мултислајсни скенер абдомена је показао постојање лобуларне, добро васкуларизоване лезије локализоване суправезикално уз предњи зид утеруса, унутар конволута танког црева. Болесница је оперисана, при чему је установљен потпуно туморски измењен цекум. Хи-

стопатолошки налаз је потврдио да се ради о ангиосаркому високог градуса. Контролни мултислајсни скенер абдомена и мале карлице, спроведен после 12 месеци, није показао постојање патолошких лезија.

**Закључак** И клиничка и хистопатолошка дијагностика ангиосаркома колоректума су изазовне. Болесници имају неспецифичне симптоме, што може водити ка постављању погрешне дијагнозе. Хистопатолошка дијагностика се ослања на имунохистохемијско бојење на ендотелне маркере, због чега се у појединим условима налаз може погрешно протумачити као слабо диферентован аденокарцином или гастроинтестинални стромални тумор. Засад, хируршко лечење остаје једини ефикасан начин лечења.

**Кључне речи:** ангиосарком; цекум; гастроинтестинални ангиосарком; ангиосарком колона