



CASE REPORT / ПРИКАЗ БОЛЕСНИКА

Antegrade dissection of external iliac artery after failed attempt of common femoral artery chronic total occlusion angioplasty

Slobodan Tanasković^{1,2}, Miodrag Ilić¹, Đorđe Radak^{3,4}, Predrag Gajin^{1,2}, Vladimir Kovačević⁵, Srđan Babić^{1,2}, Nenad Ilijevski^{1,2}

¹Dedinje Cardiovascular Institute, Vascular Surgery Clinic, Belgrade, Serbia;

²University of Belgrade, Faculty of Medicine, Belgrade, Serbia;

³Dedinje Cardiovascular Institute, Scientific Board, Belgrade, Serbia;

⁴Serbian Academy of Sciences and Arts, Belgrade, Serbia;

⁵Dedinje Cardiovascular Institute, Clinic for Radiology, Belgrade, Serbia

SUMMARY

Introduction Endovascular treatment of chronic total occlusion (CTO) represents a true challenge even for experienced interventional radiologists. We are presenting a case of hidden antegrade dissection of the external iliac artery (EIA) after a failed attempt to recanalize CTO of the common femoral artery (CFA).

Case outline A 52-year-old male patient was admitted for multidetector computed tomography (CT) angiography. Left common iliac artery (CIA) stenting was performed, followed by “crossover” attempt of recanalization of right CFA CTO that failed. The next day, left femoral superficial artery angioplasty was performed and after one month, angioplasty of the left popliteal and the below-knee arteries. A month later, the patient was readmitted for surgical reconstruction of the CFA. After desobstruction, excellent inflow was obtained and a Dacron graft was inserted. A few hours postoperatively, Fogarty catheter thrombectomy was performed. The next morning, pulsations were weakened again and CT angiography showed antegrade dissection of the EIA. Stenting of the EIA was performed with two stents and a favorable outcome was achieved. After a detailed analysis of the CT, hidden thrombosed antegrade dissection of the EIA was noted in the lateral view, which was not seen in the posterior/anterior view and was presented as fibrous plaque with mural thrombosis. Dissection occurred after failed attempt of CFA recanalization and was clinically silent until flow was established triggering opening of the false lumen and the release of thrombotic masses.

Conclusion In patients with failed angioplasty of CTO of the CFA and CT characteristics of fibrous plaque proximal to the site of attempted angioplasty, thrombosed antegrade dissection should be considered.

Keywords: iliac artery dissection; common femoral artery; chronic total occlusion; thrombosis

INTRODUCTION

Common femoral artery (CFA) chronic total occlusion (CTO) represents a true challenge even for experienced and skilled interventional radiologist. In case of extensive, complex and long occlusive lesions of the CFA and iliac arteries, surgical treatment is still a preferable treatment option [1–4]. However, the progress of endovascular therapy as a less invasive procedure in the last two decades has resulted in numerous publications showing good results of endovascular treatment of the CFA stenosis and occlusion, with a low rate of post-procedural morbidity and mortality [5–9]. Herein, we present an interesting case of a hidden thrombosed antegrade dissection of the external iliac artery (EIA) after unsuccessful CTO angioplasty of the CFA evident only after surgical revascularization.

CASE REPORT

A 52-year-old male patient was admitted to our institution for multidetector computed

tomography (MDCT) angiography. He complained of rest pain in the left foot with livid ischemia that appeared 10 days prior to admission. He also had claudication in his right leg after 100 m, which was not clinically manifested upon admission due to the inability of walking and the rest pain in the left leg. His past medical history included hypertension and hyperlipidemia. Echocardiography showed regular findings except for dilated left atrium (45 mm). Laboratory findings were within referent values except for creatine kinase, which was elevated – 654 international units (UI)/L. The examination showed absent right femoral pulse, left femoral pulse was palpable with ischemia on the third and fourth finger of the left foot. Ankle brachial indexes on the left leg were 0.37 on both the posterior tibial artery and anterior tibial artery and 0.62 on the posterior and 0.75 on the anterior tibial artery of the right leg. MDCT arteriography (64-slice device, GE HealthCare, Chicago, IL, USA) showed a significant left common iliac artery (CIA) stenosis, occlusion of the right CIA at transition to the CFA, left superficial femoral artery (SFA) subocclusion, and significant stenosis of the left popliteal artery.

Received • Примљено:

February 18, 2021

Revised • Ревизија:

September 5, 2022

Accepted • Прихваћено:

October 26, 2022

Online first: November 2, 2022

Correspondence to:

Slobodan TANASKOVIĆ
Vascular Surgery Clinic
Dedinje Cardiovascular Institute
1 Heroja Milana Tepića Street
Belgrade 11000, Serbia
drslobex@yahoo.com
drslobex@gmail.com

Firstly, left CIA stenting was performed by the antegrade approach from the left groin, followed by a “crossover” simultaneous attempt of recanalization of the right CFA CTO, which failed due to heavily calcified lesions, and CFA surgical treatment was indicated. Right CFA CTO angioplasty was attempted via the crossover approach with 55-cm-long SheatLess guiding system (Asahi-Intecc®, Tokyo, Japan) along with Shinobi 0.014 guidewire (Cordis, Fremont, CA, USA). The following day, by a left retrograde approach, SFA angioplasty was performed with stent placement. A month later, the patient was readmitted for planned right CFA surgical reconstruction. On admission, he still complained on ischemic pain in the left leg and control MDCT angiography showed regular findings after left CIA and SFA stenting (Figure 1), but also significant popliteal artery stenosis beneath the stent. Bearing in mind persisting pain in the left foot, the left popliteal artery, the posterior, and the anterior tibial artery angioplasty was performed with favorable outcome, and right CFA reconstruction was delayed for the next hospitalization.

After one month, the patient was readmitted for right CFA CTO surgical reconstruction based on the previous MDCT findings. Intraoperatively, extensive exposure of the right CFA was performed, and the CFA, the SFA, the deep femoral artery and side branches were clamped. After CFA desobstruction and plaque removal, excellent inflow was obtained and Dacron tubular graft was inserted between the EIA and the femoral arteries. The clamps were removed and distal pulsations were regular. In the evening, femoral pulsations were attenuated and the patient was sent back to the operating room. Inflow was present but weakened, Fogarty catheter was introduced and thrombectomy was performed without any difficulties, followed by improved inflow. The next morning, pulsations in the right groin were weakened again and control MDCT angiography was performed. Surprisingly, antegrade dissection of the EIA was noted, starting just above the level of the proximal graft anastomosis and going to the CIA bifurcation (Figure 2). The graft as well as proximal and distal anastomosis were with regular findings. Stenting of the right EIA was performed with placement of two stents and favorable outcome.

Postoperative course was uneventful, ankle brachial indexes were 0.8 on both arteries of the right leg and 1.0 on both arteries of the left leg. The patient was discharged on the sixth postoperative day. After six-months follow-up, vascularization of both legs was well preserved.

This case report was approved by the institutional ethics committee, and written consent was obtained from the patient for the publication of the case report and any accompanying images.

DISCUSSION

Management of CFA lesions is challenging. Surgical treatment and endarterectomy of CFA lesions has been proved to be a safe and reliable procedure [1–4]. Elsherif et al. [4] reported the outcome of 1134 revascularization procedures

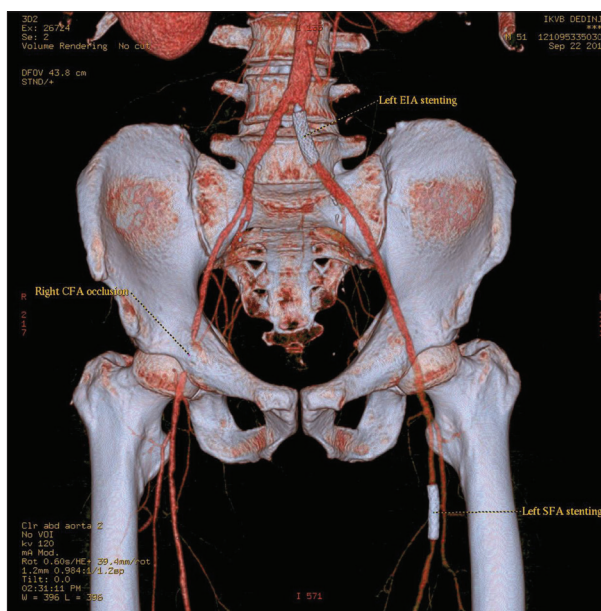


Figure 1. Multidetector computed tomography angiography; regular findings after left common iliac artery and superficial femoral artery (SFA) angioplasty with stent placement and evident right common femoral artery (CFA) occlusion – posterior/anterior view

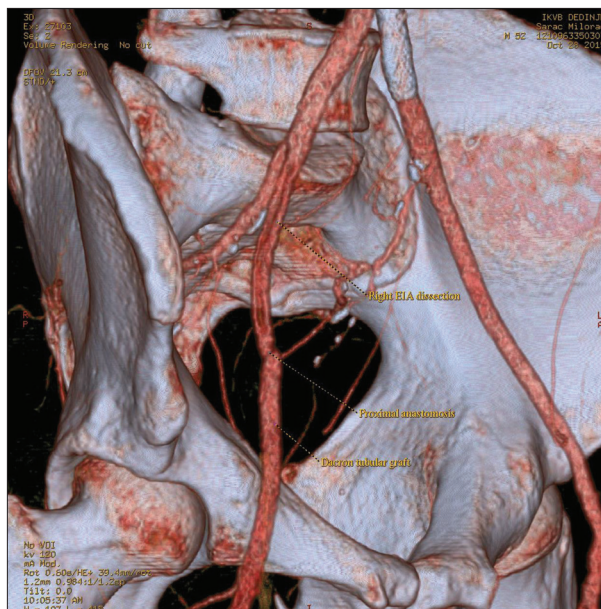

Figure 2. Multidetector computed tomography angiography; antegrade right external iliac artery (EIA) dissection starting just above the proximal anastomosis of the Dacron tubular graft

due to critical limb ischemia, out of which 66 CFA endarterectomies with favorable outcome. However, improvements in endovascular procedures in recent years have resulted in numerous publications showing good results of the endovascular treatment of CFA lesions [5–10]. In a recent review of seven CFA endarterectomy studies and four CFA endovascular studies, endovascular approach was associated with a lower rate of morbidity and mortality, but also with a higher reintervention rate when compared to surgery [7]. Nakama et al. [11] have recently reported one-year outcomes of thromboendarterectomy and endovascular treatment for CFA lesions in 1193 patients and

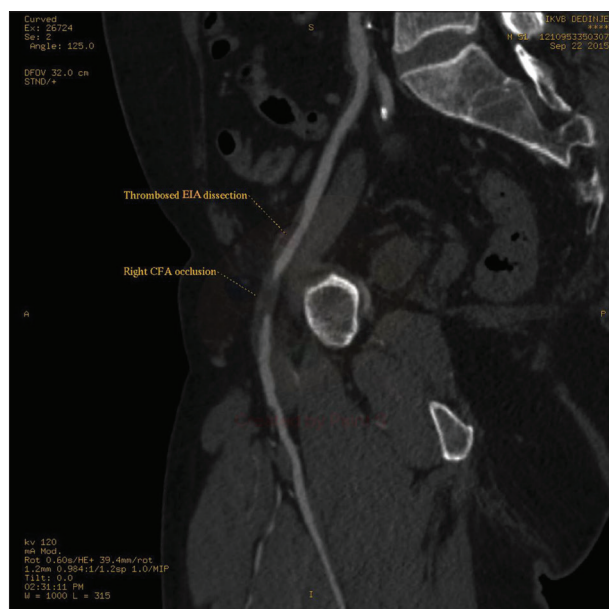


Figure 3. Hidden thrombosed antegrade dissection of the right external iliac artery (EIA) after the angioplasty attempt of the chronic total occlusion of the common femoral artery (CFA) – lateral view

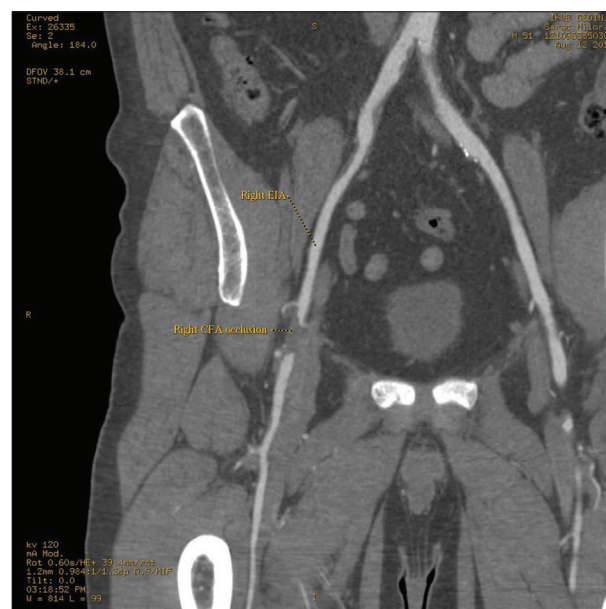


Figure 4. Multidetector computed tomography angiography; chronic total occlusion of the right common femoral artery (CFA) without any signs of thrombosed dissection prior to the angioplasty attempt

found that one-year primary patency rate was significantly higher in the thromboendarterectomy group (96.6% vs. 82.3%, $p < 0.001$) but with higher rate of periprocedural complications in the same group of patients.

Results of endovascular treatment of 946 isolated CFA lesions were reported by Siracuse et al. [8] with low rate of periprocedural morbidity and mortality and with dissection rate of 2.9%. Böhme et al. [10] also reported favorable outcomes of CFA angioplasties performed in 250 patients, out of which 64 patients had a CFA occlusion. The overall complications rate was 9.1%, with the primary patency rate of 90.8%, 81.2%, and 72% at six, 12, and 24 months, respectively.

In case of combined CFA lesions and multiple stenooclusive proximal or distal disease, a hybrid approach, CFA endarterectomy with combined endovascular approach, has been reported with reduced operative risk in patients with high morbidity [12]. A novel approach, stent-assisted angioplasty of CFA lesions showed satisfactory technical success, with low restenosis rate during the follow-up but with high mortality rate [13]. On the other hand, multichannel balloon angioplasty of heavily calcified CFA lesions has been described as well, with good initial results [14].

Although percutaneous angioplasty showed a favorable outcome in the treatment of CFA lesions, post-procedural dissection is still one of the major issues after peripheral angioplasty [15, 16, 17]. In the presented case, the CFA CTO angioplasty was attempted by subintimal approach, followed by hidden, clinically silent, thrombosed antegrade dissection of the iliac artery. When we discussed the reasons for unrecognized dissection, we looked in detail and once more processed all previous CT images. After processing images of the control CT angiography, performed after attempted CFA CTO recanalization and the first CIA

and SFA angioplasty, we saw an alteration within the EIA wall in the lateral view (Figure 3), which was not visible in the posterior/anterior (PA) view (Figure 1). At first, we thought that this alteration was fibrous atheromatous plaque with mural thrombosis, but then we realized that it was actually thrombosed antegrade dissection (Figure 3). These findings were also not visible on the first CT presentation before the angioplasty attempt (Figure 4); hence, we realized that the dissection occurred in the meantime, after the attempted angioplasty of the CFA. The dissection was clinically silent due to thrombosed false lumen and distal CFA occlusion. After successful surgical revascularization, established flow opened the false lumen, which triggered the release of thrombotic masses, causing early graft thrombosis, successfully treated by Fogarty catheter thrombectomy. Once the flow was established in the true and false lumen, the dissection membrane was clearly visible (Figure 2).

By this case we want to point out three things. Firstly, it is important to emphasize that CT angiography could be misleading in describing thrombosed antegrade iliac artery dissection as fibrous atheromatous plaque with mural thrombosis. CT characteristics were almost identical and the diagnosis was reinforced by the fact that the dissection was clinically silent due to already present distal CFA occlusion. The second thing we wanted to highlight is the importance of the lateral view while processing CT images, as it could reveal hidden minor alterations within the arterial wall that are not visible in the PA view. And thirdly and finally, we wanted to draw attention to the conversion of an asymptomatic, clinically silent, thrombosed antegrade dissection into a manifest dissection associated with thromboembolic events. In case of a unrecognized thrombosed antegrade dissection in patients with CTO, successful surgical revascularization and established flow

could trigger the release of thrombotic mass followed by embolic events and limb-threatening ischemia.

In patients with a failed angioplasty of the CFA CTO and CT characteristics of fibrous plaque with mural thrombosis proximal to the site of attempted recanalization, thrombosed antegrade dissection should be considered. Processing CT images in the lateral view could reveal

changes within the arterial wall that are not visible in the PA view. Successful surgical revascularization of CTO lesions of the CFA in patients with previously attempted angioplasty could trigger a conversion of a hidden thrombosed to an evident antegrade iliac artery dissection.

Conflict of interest: None declared.

REFERENCES

- Hirsch AT, Haskal ZJ, Hertzner NR, Bakal CW, Creager MA, Halperin JL, et al. ACC/AHA 2005 Practice Guidelines for the management of patients with peripheral arterial disease (lower extremity, renal, mesenteric, and abdominal aortic): a collaborative report from the American Association for Vascular Surgery/Society for Vascular Surgery, Society for Cardiovascular Angiography and Interventions, Society for Vascular Medicine and Biology, Society of Interventional Radiology, and the ACC/AHA Task Force on Practice Guidelines (Writing Committee to Develop Guidelines for the Management of Patients With Peripheral Arterial Disease): endorsed by the American Association of Cardiovascular and Pulmonary Rehabilitation; National Heart, Lung, and Blood Institute; Society for Vascular Nursing; TransAtlantic Inter-Society Consensus; and Vascular Disease Foundation. *Circulation*. 2006;113(11):e463–654. [DOI: 10.1161/CIRCULATIONAHA.106.174526] [PMID: 16549646]
- Norgren L, Hiatt WR, Dormandy JA, Nehler MR, Harris KA, Fowkes FG. Inter-society Consensus for the management of peripheral arterial disease (TASC II). *J Vasc Surg*. 2007;45(Suppl S):S5–67. [DOI: 10.1016/j.jvs.2006.12.037] [PMID: 17223489]
- Ballotta E, Gruppo M, Mazzalai F, Da Giau G. Common femoral artery endarterectomy for occlusive disease: an 8-year single-center prospective study. *Surgery*. 2010;147(2):268–74. [DOI: 10.1016/j.surg.2009.08.004] [PMID: 19828166]
- Elsherif M, Tawfick W, Elsharkawi M, Campell R, Hynes N, Sultan S. Common femoral artery endarterectomy in the age of endovascular therapy. *Vascular*. 2018;26(6):581–90. [DOI: 10.1177/1708538118772682] [PMID: 29759039]
- Wong G, Lahsaei S, Aoun J, Garcia LA. Management of common femoral artery occlusive disease: A review of endovascular treatment strategies and outcomes. *Catheter Cardiovasc Interv*. 2019;93(3):514–21. [DOI: 10.1002/ccd.27983] [PMID: 30537332]
- Imran HM, Hyder ON, Soukas PA. Efficacy and safety of adjunctive drug-coated balloon therapy in endovascular treatment of common femoral artery disease. *Cardiovasc Revasc Med*. 2019;20(3):210–4. [DOI: 10.1016/j.carrev.2018.06.018] [PMID: 29970328]
- Halpin D, Erben Y, Jayasuriya S, Cua B, Jhamnani S, Mena-Hurtado C. Management of Isolated Atherosclerotic Stenosis of the Common Femoral Artery: A Review of the Literature. *Vasc Endovascular Surg*. 2017;51(4):220–7. [DOI: 10.1177/1538574417702773] [PMID: 28376704]
- Siracuse JJ, Van Orden K, Kalish JA, Eslami MH, Schermerhorn ML, Patel VI, et al; Vascular Quality Initiative. Endovascular treatment of the common femoral artery in the Vascular Quality Initiative. *J Vasc Surg*. 2017;65(4):1039–46. [DOI: 10.1016/j.jvs.2016.10.078] [PMID: 28041804]
- Baumann F, Ruch M, Willenberg T, Dick F, Do DD, Keo HH, et al. Endovascular treatment of common femoral artery obstructions. *J Vasc Surg*. 2011;53(4):1000–6. [DOI: 10.1016/j.jvs.2010.10.076] [PMID: 21215567]
- Böhme T, Zeller T, Abboud M, Beschoner U, Noory E. Evaluation of Stent Angioplasty in the Treatment of Arteriosclerotic Lesions of the Common Femoral Artery. *J Clin Med*. 2022;11(10):2694. [DOI: 10.3390/jcm11102694] [PMID: 35628821]
- Nakama T, Takahara M, Iwata Y, Fujimura N, Yamaoka T, Suzuki K, et al; CAULIFLOWER Study Investigators. 1-Year Outcomes of Thromboendarterectomy vs Endovascular Therapy for Common Femoral Artery Lesions: CAULIFLOWER Study Results. *JACC Cardiovasc Interv*. 2022;15(14):1453–63. [DOI: 10.1016/j.jcin.2022.03.010] [PMID: 35863795]
- Kim JH, So BJ, Byun SJ, Kim KY. The Advantage of Common Femoral Endarterectomy Alone or Combined with Endovascular Treatment. *Vasc Specialist Int*. 2018;34(3):65–71. [DOI: 10.5758/vsi.2018.34.3.65] [PMID: 30310809]
- Stricker H, Spinedi L, Limoni C, Giovannacci L. Stent-Assisted Angioplasty (SAA) at the Level of the Common Femoral Artery Bifurcation: Long-Term Outcomes. *Cardiovasc Intervent Radiol*. 2020;43(4):541–6. [DOI: 10.1007/s00270-020-02413-9] [PMID: 31974742]
- Nagatomi S, Ichihashi S, Yamamoto H, Iwakoshi S, Taguchi H, Inagaki M, et al. Efficacy of Multichannel Balloon Angioplasty in Calcified Common Femoral Artery Lesions. *J Vasc Interv Radiol*. 2021;32(2):181–6. [DOI: 10.1016/j.jvir.2020.10.018] [PMID: 33288417]
- Gray WA, Cardenas JA, Brodmann M, Werner M, Bernardo NI, George JC, et al. Treating Post-Angioplasty Dissection in the Femoropopliteal Arteries Using the Tack Endovascular System: 12-Month Results From the TOBA II Study. *JACC Cardiovasc Interv*. 2019;12(23):2375–84. [DOI: 10.1016/j.jcin.2019.08.005] [PMID: 31806218]
- Tan M, Urasawa K, Koshida R, Haraguchi T, Kitani S, Igarashi Y, et al. Comparison of Angiographic Dissection Patterns Caused by Long vs Short Balloons During Balloon Angioplasty of Chronic Femoropopliteal Occlusions. *J Endovasc Ther*. 2018;25(2):192–200. [DOI: 10.1177/1526602818756610] [PMID: 29429382]
- Kobayashi N, Hirano K, Yamawaki M, Araki M, Sakai T, Sakamoto Y, et al. Simple classification and clinical outcomes of angiographic dissection after balloon angioplasty for femoropopliteal disease. *J Vasc Surg*. 2018;67(4):1151–8. [DOI: 10.1016/j.jvs.2017.08.092] [PMID: 29242063]

Антероградна дисекција спољашње илијачне артерије после неуспелог покушаја ангиопластике хроничне тоталне оклузије заједничке феморалне артерије

Слободан Танасковић^{1,2}, Миодраг Илић¹, Ђорђе Радак^{3,4}, Предраг Гајин^{1,2}, Владимир Ковачевић⁵, Срђан Бабић^{1,2}, Ненад Илијевски^{1,2}

¹Институт за кардиоваскуларне болести „Дедиње“, Клиника за васкуларну хирургију, Београд, Србија;

²Универзитет у Београду, Медицински факултет, Београд, Србија;

³Институт за кардиоваскуларне болести „Дедиње“, Научно веће, Београд, Србија;

⁴Српска академија наука и уметности, Београд, Србија;

⁵Институт за кардиоваскуларне болести „Дедиње“, Клиника за радиологију, Београд, Србија

САЖЕТАК

Увод Ендоваскуларни третман хроничне тоталне оклузије представља прави изазов чак и за искусне интервентне радиологе. Приказујемо случај скривене антероградне дисекције спољашње илијачне артерије (СИА) после неуспелог покушаја реканализације хроничне тоталне оклузије заједничке феморалне артерије (ЗФА).

Приказ болесника Мушкарац старости 52 године примљен је ради мултидетекторске компјутеризоване томографске ангиографије. Урађен је стентинг леве заједничке илијачне артерије, а после тога и *crossover* покушај реканализације хроничне тоталне оклузије десне ЗФА, који није успео. Следећег дана урађена је ангиопластика леве површне бутне артерије, а после месец дана и ангиопластика поплитеалне и потколених артерија леве ноге. Месец дана касније болесник је поново примљен због хируршке реконструкције ЗФА. После дезопструкције добијен је одличан проток и урађена је интерпозиција дакронског графта. Неколико сати постоперативно урађена је и тромбектомија Фогартијевим кате-

тером. Наредног јутра пулсације у десној препони су поново биле ослабљене и КТ ангиографија је показала антероградну дисекцију СИА. Урађен је стентинг СИА са два стента и са задовољавајућим исходом. После детаљне анализе КТ снимака, верификована је тромбозирани дисекција СИА у латералном прегледу, која није била виђена у постериорно/антериорном прегледу и које је била представљена као фиброзни плак са муралном тромбозом. Дисекција је настала после неуспелог покушаја реканализације ЗФА и била је клинички нема док није успостављен проток који је покренуо отварање лажног лумена и ослобађање тромботичних маса.

Закључак Код болесника са неуспешном ангиопластиком хроничне тоталне оклузије ЗФА и КТ карактеристикама фиброзног плака проксимално од места покушаја ангиопластике, треба помислити и на тромбозирани антероградну дисекцију.

Кључне речи: дисекција илијачне артерије; заједничка феморална артерија; хронична тотална оклузија; тромбоза