

ORIGINAL ARTICLE / ОРИГИНАЛНИ РАД

Magnetic resonance imaging vs. arthroscopy in diagnosing anterior cruciate ligament and meniscus injuries – is there a difference

Milan Mirković¹, Aleksandar Crnobaric¹, Sanja Mirković², Andreja Baljzović^{1,3}, Vladan Stevanović^{1,3}, Miodrag Glišić^{1,3}, Aleksandar Jevtić^{1,3}, Nemanja Slavković^{1,3}, Zoran Baščarević^{1,3}

¹Banjica Institute of Orthopedics, Belgrade, Serbia;

²University of Belgrade, Faculty of Sport and Physical Education, Belgrade, Serbia;

³University of Belgrade, Faculty of Medicine, Belgrade, Serbia



SUMMARY

Introduction/Objective The knee joint is prone to injuries caused by direct or indirect trauma. The meniscus and ligament injuries, cannot be completely diagnosed with clinical examination; therefore, we use additional non-invasive and invasive diagnostic methods such as magnetic resonance imaging (MRI) and arthroscopy.

The aim was to compare the accuracy of MRI and objective knee findings based on arthroscopic examination in case of meniscus and anterior cruciate ligament injuries.

Methods The study involved 50 patients treated with elective surgery which mandatory involved arthroscopic visualization of the knee structures. We compared the MRI findings, obtained from different institutions, and arthroscopic knee findings for all the patients involved in the study.

Results There were 50 patients included in the study with mean age of 31 years.

MRI showed that Anterior cruciate ligament was damaged in 41 patients, while arthroscopy confirmed damage in 43 patients. Medial meniscus was damaged in 31 patients on MRI and in 27 on arthroscopic examination. Lateral meniscus was injured in 35 patients on MRI and arthroscopy showed damage in 32 patients. Using χ^2 test we found no significant difference between MRI and arthroscopy as diagnostic methods. Wilcoxon signed-rank test shows similar results between MRI and arthroscopy findings.

Conclusion A comparative analysis of MRI and arthroscopy diagnostic value in case of anterior cruciate ligament, medial meniscus and lateral meniscus injuries have shown that there is no significant difference between these two methods.

Keywords: magnetic resonance imaging; arthroscopy; meniscus; anterior cruciate ligament

INTRODUCTION

The knee joint is the largest and most complex joint in the human body. On the front side, the knee joint is not protected by a thicker muscular covering, and, due to this structural weakness, this joint is prone to injury by direct trauma and rotation. Twisting injuries are usually presented as a tear of the meniscus and ligaments [1]. Meniscal injuries are usually longitudinal and accompanied with anterior cruciate ligament (ACL) injuries in 55–65% of the cases. Meniscus and ligament injuries cannot be completely diagnosed by clinical examination; therefore, we use additional non-invasive and invasive diagnostic methods such as magnetic resonance imaging (MRI) and arthroscopy [2]. MRI has proved to be a quick and non-invasive diagnostic method, complementing clinical examination [3]. MRI has become a popular and practical tool on the basis of which we make the final conclusion about the ACL and meniscus condition and the choice of arthroscopy [4]. Arthroscopy can be used for the diagnosis and treatment, but it is at the same time an invasive method [1]. Arthroscopic examination lets us evaluate, visualize, and confirm if the

diagnosis based on clinical examination and MRI is correct [4]. Pain with blockade after a twisting knee injury is a typical symptomatology. The anamnesis is usually clear. The tear is usually longitudinal pericapsular or, in some cases, bucket handle type. It happens to young people, especially athletes [5].

Injuries to the medial meniscus (MM) are much more common than to the lateral meniscus (LM). It occurs mostly when lower leg is in semi-flexion and fixed with the foot, followed by a sudden abduction and external rotation of the lower leg. In that moment, there is a strong torsional force on the meniscus being pinched between condyles [6].

Injuries to the LM are much less frequent; they are mostly presented as longitudinal tears, and the mechanism of injury is defined as a varus and internal rotation, most commonly referred to a fall on the bent leg [7].

ACL injury occurs by an indirect mechanism in case of twisting, flexion, and in cases of contact and deceleration. There is the pain feeling that something is broken (“cracked”) in the knee, functional disability of the knee and acute painful knee effusion in the next few hours, up to 24 hours [8].

Received • Примљено:

May 24, 2022

Revised • Ревизија:

August 13, 2022

Accepted • Прихваћено:

August 30, 2022

Online first: September 1, 2022

Correspondence to:

Zoran BAŠČAREVIĆ
Banjica Institute of Orthopedics
Mihaila Avramovića 28
11000 Belgrade, Serbia
zoran.bascarevic@iohbb.edu.rs

The aim of this work is to compare MRI and arthroscopic examination in meniscal and ACL injuries diagnosis.

METHODS

This retrospective study was conducted at the Banjica Institute for Orthopedic Surgery in Belgrade, Serbia from March 1, 2015 to July 1, 2015. The study involved 50 patients treated by elective arthroscopic knee surgery with preoperative MRI findings. Only patients with injured knee were included in the study. Exclusion criteria were previous arthroscopic surgery, absence of MRI and degenerative pathology. All MRI findings were interpreted by the leading author. We compared the MRI findings in terms of ACL, MM, and LM damage, obtained from different institutions, and arthroscopic findings for all the patients involved in the study. All surgeries were conducted in regional anesthesia by the same surgical team. Statistical data analysis was performed by χ^2 test and Wilcoxon signed-rank test. This study was done in accordance with standards of the institutional committee on ethics.

RESULTS

There were 49 males and one female included in the study with the mean age of 31 years (24–43 years).

MRI showed that ACL was damaged in 41 patients, while it was preserved in nine. The arthroscopy confirmed that ACL was damaged in 43 patients, while it was preserved in seven. Regarding MM, MRI showed damage in 31 patients, while in 19 it was preserved. The arthroscopic examination confirmed damage in 27 patients, while in 23 patients the finding on the MM was normal. LM was injured in 35 patients, while in 15 it was preserved, according to MRI findings. The arthroscopy confirmed LM damage in 32 patients, while no changes were observed in 18. Results of two compared diagnostic procedures are presented in Table 1.

Table 1. Results of magnetic resonance imaging (MRI) and arthroscopy (ASC) diagnostics in knee injuries

Part of the knee	Damaged/preserved	MRI	ASC	p*	p**
ACL	Damage	41	43	0.317	0.585
	Preserved	9	7		
MM	Damage	31	27	0.248	0.417
	Preserved	19	23		
LM	Damage	35	32	0.366	0.523
	Preserved	15	18		

ACL – anterior cruciate ligament; MM – medial meniscus; LM – lateral meniscus;
*Wilcoxon signed-rank test;
** χ^2 test

The χ^2 test and Wilcoxon signed-rank test showed that there were not statistically significant differences between the two diagnostic methods for all three types of injury ($p > 0.05$), as presented in Table 1.

DISCUSSION

After clinical examination of a knee injury, additional diagnostics is usually required. In this study, we compared the results obtained by MRI and arthroscopy in meniscal and ACL knee injuries. Both methods have their limitations.

MRI offers precise insight in both intraarticular and extraarticular structures of the knee, while arthroscopy is mainly focused on intraarticular structures. Knee arthroscopy does not routinely recognize injuries of some soft tissue structures, e.g., superficial medial collateral ligament complex, structures of the posterolateral corner, or the extensor mechanism. Arthroscopy is inferior in the assessment of traumatic and infiltrative bone marrow abnormalities, which commonly follow meniscal injuries. MRI is also the preferred method for the diagnosis of synovial lesions [9].

MRI does not provide a dynamic assessment of soft-tissue knee structures like in arthroscopy. Meniscal tears and chondral defects can be assessed both by MRI and arthroscopic probing. The probing is especially useful in the postoperative meniscus to distinguish tear from postoperative signal or healing changes in a repaired tear [10].

Our results showed that ACL injury on arthroscopy was slightly more often positive than on MRI, while for MM and LM it was reversed as shown in Figure 1. One of the explanations is that decreased sensitivity of MRI in diagnosing ACL injury may be attributed to difficulties of displaying the ligament fully on the sagittal plane due to its anatomical obliquity passage across the joint, as depicted by some studies [11]. Diagnostic accuracy of ligamentous injuries has been improved by dynamic arthroscopic evaluation. Although MRI is very sensitive and specific in the diagnosis of complete ACL tears, the functional status and presence of partial tears may be better assessed by arthroscopy. The degree of the medial and lateral joint gap with valgus or varus stress during arthroscopy serves as an indicator of the severity of collateral ligaments injury. Also, dynamic posterior drawer test during the procedure with the knee flexed to 90° can assess posterior cruciate ligament incompetence [12].

It is necessary to be aware of some anatomical structures in the knee that may not be well visualized by MRI

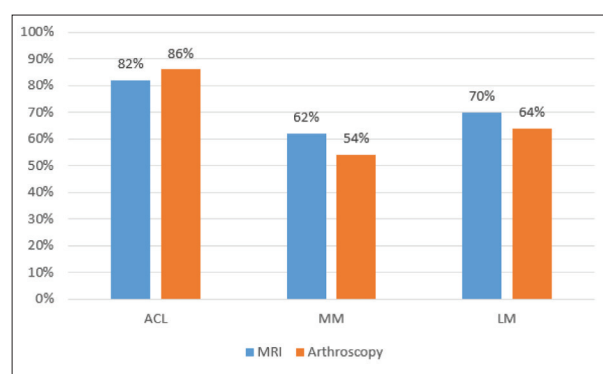


Figure 1. The comparison of anterior cruciate ligament (ACL), medial meniscus (MM), and lateral meniscus (LM) injuries found by magnetic resonance imaging (MRI) and arthroscopy

nor by arthroscopy. For example, the posterior horn of the MM that plays an important role in limiting anterior tibial translation may sometimes be difficult to evaluate with the standard anterior viewing portals [13].

In our study, we found that MRI and arthroscopy are equally valuable diagnostic tools, because the number of diagnosed injuries was approximately the same by both methods, for each type of knee injury. The obtained results are in accordance with the other studies in all parameters of testing [14, 15].

Diagnostic correlation between MRI and arthroscopy based on Wilcoxon signed-rank test showed that the p value was higher for LM than for ACL and MM. These results are comparable to a recent study by Duong et al. [16], who found 88% vs. 86% accuracy for lateral and medial meniscal lesions, respectively. In our study, a higher number of injuries to the LM compared to the medial one were observed using both diagnostic methods. One

explanation could be the relatively small sample size, which is also comparable to the results from Duong et al. [16]. We believe that with an increase in the sample, the ratio of these injuries would be closer to literature data, which is also one of the limitations of the study.

The disadvantage of our research could be that not all MRI examinations were performed by the same technique.

CONCLUSION

Differences in accuracy between MRI and arthroscopy as diagnostic methods for ACL, MM and LM injuries should not be expected. The correlation between the two methods is higher for the LM than for the MM and the ACL.

Conflict of interest: None declared.

REFERENCES

- Schnaiter JW, Roemer F, McKenna-Kuettner A, Patzak HJ, May MS, Janka R, et al. Diagnostic Accuracy of an MRI Protocol of the Knee Accelerated Through Parallel Imaging in Correlation to Arthroscopy. *Rofo*. 2018;190(3):265–72. [DOI: 10.1055/s-0043-119038] [PMID: 28950384]
- Zheng T, Song G, Li Y, Zhang Z, Ni Q, Cao Y, et al. Clinical, Radiographic, and Arthroscopic Outcomes of Surgical Repair for Radial and Avulsed Lesions on the Lateral Meniscus Posterior Root During ACL Reconstruction: A Systematic Review. *Orthop J Sports Med*. 2021;9(3):2325967121989678. [DOI: 10.1177/2325967121989678] [PMID: 33796590]
- Greif DN, Baraga MG, Rizzo MG, Mohile NV, Silva FD, Fox T, et al. MRI appearance of the different meniscal ramp lesion types, with clinical and arthroscopic correlation. *Skeletal Radiol*. 2020;49(5):677–89. [DOI: 10.1007/s00256-020-03381-4] [PMID: 31982971]
- Hogea GB, Pătrașcu JM Jr, Săndesc MA, Bredicean AC, Nussbaum LA, Hogea LM, et al. The utility of indirect imagistic signs in the diagnosis of anterior cruciate ligament ruptures. *Rom J Morphol Embryol*. 2018;59(3):741–5. [PMID: 30534812]
- Bronstein RD, Schaffer JC. Physical Examination of the Knee: Meniscus, Cartilage, and Patellofemoral Conditions. *J Am Acad Orthop Surg*. 2017;25(5):365–74. [DOI: 10.5435/JAAOS-D-15-00464] [PMID: 28406879]
- Popović Z. *Oboljenja kolena*. In: Vukašinović Z, et al., editors. *Specijalna ortopedija*. 1st ed. Beograd: IOHB „Banjica”; 2004. p. 336–56.
- Chien A, Weaver JS, Kinne E, Omar I. Magnetic resonance imaging of the knee. *Pol J Radiol*. 2020;85:e509–e531. [DOI: 10.5114/pjr.2020.99415] [PMID: 33101555]
- Lecouvet F, Van Haver T, Acid S, Perlepe V, Kirchgessner T, Vande Berg B, et al. Magnetic resonance imaging (MRI) of the knee: Identification of difficult-to-diagnose meniscal lesions. *Diagn Interv Imaging*. 2018;99(2):55–64. [DOI: 10.1016/j.diii.2017.12.005] [PMID: 29396088]
- Wang W, Li Z, Peng HM, Bian YY, Li Y, Qian WW, et al. Accuracy of MRI Diagnosis of Meniscal Tears of the Knee: A Meta-Analysis and Systematic Review. *J Knee Surg*. 2021;34(2):121–29. [DOI: 10.1055/s-0039-1694056] [PMID: 31390675]
- Rizk B, Brat H, Zille P, Guillin R, Pouchy C, Adam C, et al. Meniscal lesion detection and characterization in adult knee MRI: A deep learning model approach with external validation. *Phys Med*. 2021;83:64–71. [DOI: 10.1016/j.ejmp.2021.02.010] [PMID: 33714850]
- Machagge H, Mrita F, Muhamedhussen M, Haonga B, Mcharo CN. Evaluation of Accuracy of Clinical Examination and MRI on Diagnosing Anterior Cruciate Ligament and Meniscal Tears in Comparison to Diagnostic Arthroscopy among Patients Attending at Muhimbili Orthopedic Institute. *Open J Orthop*. 2021;11(12):353–70. [DOI: 10.4236/ojo.2021.1112034]
- Alaia EF, Alaia MJ, Gyftopoulos S. MRI-Arthroscopy Correlation of Knee Anatomy and Pathologic Findings: A Teaching Guide. *AJR Am J Roentgenol*. 2018;211(6):1291–7. [DOI: 10.2214/AJR.18.19726] [PMID: 30332292]
- DePhillipo NN, Cinque ME, Chahla J, Geeslin AG, Engebretsen L, LaPrade RF. Incidence and Detection of Meniscal Ramp Lesions on Magnetic Resonance Imaging in Patients with Anterior Cruciate Ligament Reconstruction. *Am J Sports Med*. 2017;45(10):2233–7. [DOI: 10.1177/0363546517704426] [PMID: 28463534]
- Kulkarni OP, Pundkar GN, Sonar SB. A comparative study of MRI versus arthroscopic findings in ACL and meniscal injuries of the knee. *Int J Res Orthop*. 2018;4:198–202. [DOI: 10.18203/issn.2455-4510]
- Singh N, Hanekom H, Suleman FE. The accuracy of magnetic resonance imaging diagnosis of non-osseous knee injury at Steve Biko Academic Hospital. *SA J Radiol*. 2019;23(1):1754. [DOI: 10.4102/sajr.v23i1.1754] [PMID: 31754541]
- Duong TD, Tran DT, Do BNT, Tran HT, Le SM, Vu TT. Diagnostic value of clinical tests and MRI for meniscal injury in patients with anterior cruciate ligament injury: Case series study. *Int J Surg Case Rep*. 2021;88:106492. [DOI: 10.1016/j.ijscr.2021.106492] [PMID: 34655974]

Дијагностика повреде менискуса и предњег укрштеног лигамента колена магнетном резонанцом у односу на артроскопију – има ли разлике

Милан Мирковић¹, Александар Црнобарих¹, Сања Мирковић², Андреја Баљозовић^{1,3}, Владан Стевановић^{1,3}, Миодраг Глишић^{1,3}, Александар Јевтић^{1,3}, Немања Славковић^{1,3}, Зоран Башчаревић^{1,3}

¹Институт за ортопедију Бањица, Београд, Србија;

²Универзитет у Београду, Медицински факултет, Београд, Србија;

³Универзитет у Београду, Факултет спорта и физичког васпитања, Београд, Србија

САЖЕТАК

Увод/Циљ Зглоб колена подложен је повредама узрокованим директном или индиректном силом. Повреде менискалних и лигаментарних структура не могу бити потпуно сагледане клиничким прегледом, те су неопходне инвазивне и неинвазивне дијагностичке методе попут магнетне резонанце (МР) и артроскопије.

Циљ овог рада је поређење прецизности налаза МР и објективног стања у колелу утврђеног артроскопијом у случају повреде медијалног и латералног менискуса, као и предњег укрштеног лигамента.

Метод У истраживање смо укључили 50 болесника лечених елективним артроскопским процедурама. Код свих болесника упоређивали смо налазе МР, рађене у различитим установама, са налазима виђеним у колелу уз помоћ артроскопа.

Резултати Студија је обухватила 50 болесника просечне старости 31 годину. МР је показала повреду предњег

укрштеног лигамента код 41 болесника, док је оштећење потврђено артроскопијом код њих 43. Медијални менискус је био оштећен код 31 болесника на МР снимку, док је артроскопски верификовано 27 оштећења. Латерални менискус повређен је код 35 болесника на МР снимку, а артроскопски је оштећење уочено код њих 32. Тестом χ^2 није утврђена статистички значајна разлика између ове две методе у дијагностичком смислу. Примена Вилкоксоновог теста предзнака, као и анализа варијансе указали су на исти резултат.

Закључак Упоредном анализом дијагностичке вредности МР и артроскопије код повреда предњег укрштеног лигамента, медијалног и латералног менискуса утврдили смо да нема значајних разлика у дијагностичком смислу између ове две методе.

Кључне речи: магнетна резонанца; артроскопија; менискус; предњи укрштени лигамент