



CASE REPORT / ПРИКАЗ БОЛЕСНИКА

Exercise-induced Valsalva retinopathy – a case report and literature review

Igor Kovačević^{1,2}, Jelena Mirković¹, Vesna Šobot¹, Mladen Bila¹, Jelena Vasilijević^{1,2}¹University Clinical Centre of Serbia, Eye Clinic, Belgrade, Serbia;²University of Belgrade, Medical Faculty, Belgrade, Serbia**SUMMARY**

Introduction Valsalva retinopathy is an uncommon disorder that usually presents with acute onset of unilateral, or less frequently, bilateral visual impairment varying from subtle scotoma to total vision loss. It occurs as a result of Valsalva's maneuver. In the vast majority of cases, hemorrhage is preretinal although subretinal, intraretinal and vitreous hemorrhage can be found. Valsalva retinopathy often develops due to numerous triggering activities such as vomiting, coughing, heavy weight lifting, intense aerobic exercise, labor, and general anesthesia. Management options are either clinical observation or invasive techniques. We report a case of premacular hemorrhage due to Valsalva retinopathy induced by gym training.

Case outline A 34-year-old woman was referred to the Eye Clinic, University Clinical Center of Serbia, complaining of sudden and painless unilateral decrease in vision occurred during intense physical activity. Best corrected visual acuity was measured as counting fingers at five meters distance. Dilated funduscopy demonstrated a large, well demarcated premacular subhyaloid hemorrhage with visible rupture of the retinal vein branch. The patient was treated conservatively. Three months after the onset of symptoms, hemorrhage absorbed and best corrected visual acuity was 20/20.

Conclusion Valsalva retinopathy, although a rare condition, should not be omitted as a differential diagnosis of retinal and vitreous hemorrhages. Standard, observational treatment is generally sufficient for complete vision recovery; however, literature suggests that an individualized approach to each patient is required.

Keywords: Valsalva retinopathy; Valsalva's maneuver; preretinal hemorrhage; vitreous hemorrhage

INTRODUCTION

Valsalva retinopathy (VR) is an uncommon disorder that usually presents with acute onset of unilateral or, less frequently, bilateral visual impairment varying from subtle scotoma over blurry vision to total vision loss [1, 2]. It occurs as a result of Valsalva's maneuver, forced expiratory effort against a closed airway, which causes increase in venous intrathoracic pressure [3]. This rapid rise in venous pressure is transmitted to the retinal capillaries causing their rupture, typically at the macular area [1, 3, 4]. In the vast majority of cases, hemorrhage is preretinal (sub-internal limiting membrane (sub-ILM) or subhyaloid), although subretinal, intraretinal and vitreous hemorrhage can be found [5].

VR often develops in young adults with no medical history, due to numerous triggering activities such as vomiting, coughing, heavy weight lifting, intense aerobic exercise, labor, or general anesthesia [6, 7]. It is most commonly found in adolescent males [8].

Diagnosis can be challenging considering that premacular hemorrhage may also be seen in systemic and many other ocular conditions including proliferative diabetic retinopathy, vein occlusion, macroaneurysm, Terson's syndrome, shaken adult syndrome, and blunt trauma [9, 10].

Management options are either clinical observation or invasive techniques [9], such as neodymium-doped yttrium aluminum garnet (Nd: YAG) laser hyaloidotomy, green argon laser, pneumatic relocation of the hemorrhage with intravitreal gas and pars plana vitrectomy (PPV) [6]. Generally, the blood resorbs spontaneously with full recovery of visual acuity, however, prolonged presence of preretinal hemorrhage can lead to pigmentary macular damage or development of epiretinal membrane. Moreover, continuous exposure to hemoglobin and iron may cause toxic retinal damage which can be irreversible [6, 11]. When choosing therapeutic option, thickness and amount of blood should be considered as well as anatomical location of the hemorrhage [12].

In this paper, we report a case of premacular hemorrhage due to VR induced by a gym training.

CASE REPORT

A 34-year-old woman was referred to the Eye Clinic, University Clinical Center of Serbia, complaining of a sudden and painless unilateral decrease in vision which occurred during intense physical activity in gym. Initially, she spotted "sparkles" in front of both eyes, then an hour later, while heavy weight lifting, she

Received • Примљено:

April 7, 2022

Revised • Ревизија:

June 6, 2022

Accepted • Прихваћено:

June 24, 2022

Online first: July 4, 2022**Correspondence to:**

Jelena MIRKOVIĆ
University Clinical Centre of Serbia
Eye Clinic
Belgrade
Serbia
mirkovicjelena@outlook.com

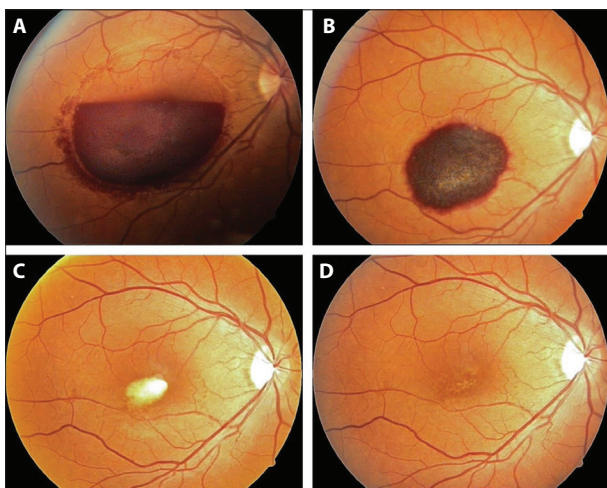


Figure 1. Color photo of the affected eye; A) on admission – large, well demarcated premacular subhyaloid hemorrhage more than 4-disc diameter in size; B) three weeks after discharge – the blood had started to resolve; C) two months after the accident – significantly smaller, dehemoglobinized hemorrhage in the macular area; D) at the third follow-up, three months after the onset of symptoms – complete resolution of the hemorrhage

noticed blurry vision and a black spot in her right eye. There was no medical history, however positive family history of abdominal aneurysm and cerebrovascular insult was present. Ocular anamnesis was negative and she denied history of eye trauma. A complete ophthalmological examination was performed. Best corrected visual acuity (BCVA) was measured as counting fingers at five meters distance in her right eye and 20/20 in her left eye. The intraocular pressures, pupillary light reflexes and eye motility tests were normal. There was no evidence of abnormalities of the both anterior segments. Dilated funduscopy demonstrated a large, well demarcated premacular subhyaloid hemorrhage with visible rupture of the retinal vein branch in the right eye (Figure 1A). Left eye funduscopy was unremarkable. The patient was admitted to the hospital for further clinical observation and treatment. All laboratory parameters (complete blood work, hemostasis, and biochemical profile) were within normal limits. During hospitalization an optical coherence tomography (OCT) and fundus photography were performed. The OCT showed localized hyperreflective lesion causing shadowing of the underlying retinal layers while central macular thickness was 779 μm (Figure 2A). Considering the patient's anamnesis and appearance of the hemorrhage on clinical examination and OCT, VR diagnosis was established. The patient was treated conservatively with topical glucocorticoid, nonsteroidal anti-inflammatory, anticholinergic drugs and oral antihemorrhagic agents. After several days of follow-up, the patient was discharged home with recommendation for close regular follow-up. At the first follow-up, three weeks after discharge from hospital, clinical examination revealed smaller hemorrhage in the macular area (Figures 1B and 2B), suggesting that blood started to resolve spontaneously, although there was no improvement in visual acuity. Second follow-up, two months after the accident, showed significantly smaller, dehemoglobinized blood

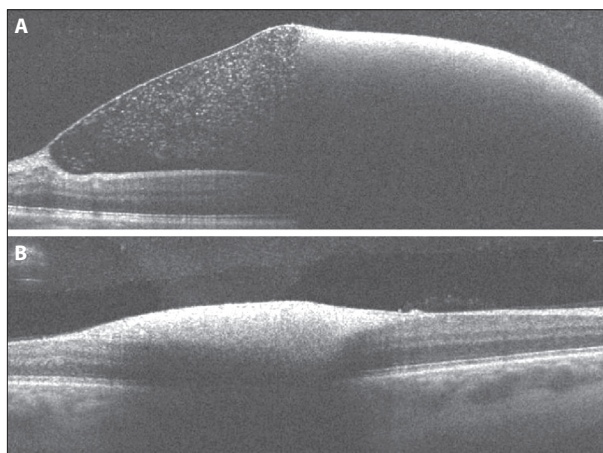


Figure 2. Optical coherence tomography of the affected eye; A) on admission – localized, hyperreflective lesion and shadowing of the underlying retinal layers; B) three weeks after discharge from the hospital

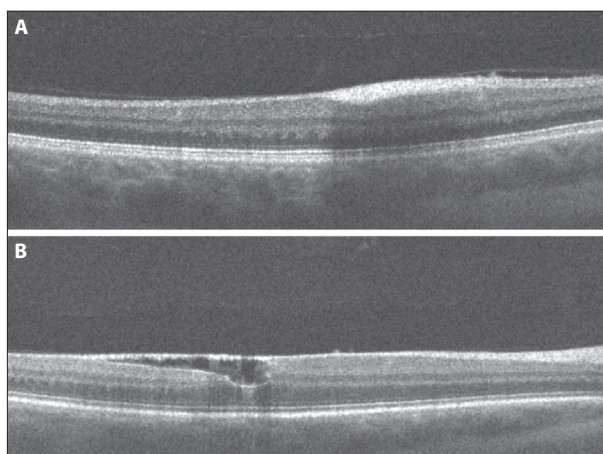


Figure 3. Optical coherence tomography of the affected eye; A) two months after the accident; B) at the third follow-up, three months after the onset of symptoms – epiretinal membrane formation

(Figures 1C and 3A). BCVA on the affected eye improved to 20/100. The hemorrhage was still in the macular area which is the reason why visual acuity was not fully recovered. At the third follow-up, three months after the onset of symptoms, hemorrhage absorbed and BCVA was 20/20, yet the patient reported that visual quality was slightly worse compared to the unaffected eye, which was presumably due to epiretinal membrane formation discovered by OCT (Figures 1D and 3B).

This care report was done in accordance with the institutional standards on Ethics and principles of the Declaration of Helsinki.

DISCUSSION

VR was first described by Duane [13]. It arises secondary to physical activities corresponding to Valsalva's maneuver. The absence of functional valves in the venous system of head and neck allows transmission of the elevated systemic venous pressure to the eye resulting in rupture of the superficial retinal vessels. Localization of preretinal hemorrhage is most commonly on the posterior pole probably

due to lose bonds between internal limiting membrane and retina right peripheral to the fovea [2].

Patients with VR are often young or middle-aged people who present complaining of sudden unilateral floaters, scotoma, or even complete loss of vision [1]. Good medical history and thorough examination of both eyes are essential in diagnosis since the differential diagnosis for the unilateral retinal hemorrhages includes multiple conditions. Systemic diseases, such as diabetes mellitus, hypertension, hematologic disorders, should be excluded. The patient should be asked about recent head or eye injury to rule out blunt trauma [2, 10]. Valsalva-induced and spontaneous sub-ILM and vitreous hemorrhages due to temporarily dysfunctional coagulation status in patients with SARS-CoV-2 infection were also described in recent years [14, 15, 16]. Another possible cause is Terson's syndrome, which arises secondary to subarachnoid hemorrhage. Pathogenesis of this syndrome is similar as in VR – rapid rise in intracranial pressure is transferred to retinal vein system leading to retinal or vitreous bleeding [17]. Therefore, neurological signs and symptoms should be observed to exclude Terson's syndrome [2, 10]. Considering the fact that our patient had positive family history of abdominal aneurysm, we involved the rupture of retinal aneurysm as differential diagnosis, although this condition is usually seen in older population as an outcome of hypertension and arteriosclerosis [18]. OCT is useful in determining the exact location of the hemorrhage and fundus imaging is very significant in monitoring the progression/regression of the disease [12]. In our patient, through careful anamnesis, laboratory analyses and detailed examination of both affected and unaffected eye, diagnosis of VR was made with certainty.

There is no clear protocol for treating VR. However, literature data suggests that standard treatment is observation and in the majority of patients vision is fully recovered over a period of few months [19, 20]. The main issue regarding conservative approach is the extended exposure of the retina to phototoxic blood products (hemoglobin and iron) which can lead to permanent vision damage or formation of an epiretinal membrane [20]. According to one retrospective study conducted on 24 eyes with VR, preretinal hemorrhage size 4-disc diameter or less could be conservatively treated. In the same study, all of their 13 patients who were observed for spontaneous resorption of the hemorrhage recovered visual acuity of 20/20 over the next six months [12]. Many other studies reported resolution of the blood and good visual outcome after observation period without any additional treatment [1, 2, 5]. If conservative treatment is

chosen, patient should be advised to rest and not to involve in any physical activity. Sleeping in half-sitting position is also recommended to accelerate blood settling [12]. Nd: YAG laser was successfully used in management of VR. This procedure involves laser perforation of the posterior hyaloid membrane or ILM resulting in drainage and inferior settlement of the blood into the vitreous cavity [20]. Nd: YAG laser is considered to be relatively safe, affordable and effective option in treatment of this condition, yet several complications including macular hole, epiretinal membrane and retinal detachment were reported [19, 21]. There are remaining questions about patient selection, timing of laser treatment and energy levels needed. Most of the studies indicate that Nd: YAG laser can be used in patients with non-clotted preretinal hemorrhage greater than 3-disc diameter in size and no longer than three weeks of duration. Energy levels should be as low as needed to perforate hyaloid/internal limiting membrane, not crossing 9 mj [9, 12, 19, 22, 23]. In a case series presented by Kuruvilla et al. [9] visual acuity was improved in three out of four patients who underwent laser treatment. Dulger et al. [12] performed Nd: YAG laser hyaloidotomy in 10 eyes, all of which restored good vision in the first week after treatment. One recent case report, showed that laser treatment can be effective even when done more than three weeks after the onset of symptoms, yet treatment had to be repeated on two separate occasions in order to achieve a favorable result [22]. In contrary to previously mentioned studies, García Fernández et al. [6] reported two unsuccessful Nd: YAG laser treatments due to coagulated blood, therefore they decide to perform PPV resulting in full visual recovery one day postoperatively in both cases.

When there is insufficient spontaneous resorption of the preretinal hemorrhage and Nd: YAG laser is not indicated or failed due to coagulated blood, PPV can be performed. It is an invasive surgical technique with well-known complications, for instance cataract and macular hole formation [20]. García Fernández et al. [6] managed five of their patient's performing vitrectomy, all with excellent postoperative visual acuity, yet one of the patients developed cataract and retinal break.

In conclusion, VR although a rare condition, should not be omitted as a differential diagnosis of retinal and vitreous hemorrhages. Standard, observational treatment is generally sufficient for complete recovery of vision; however, literature suggests that an individualized approach to each patient is required.

Conflict of interest: None declared.

REFERENCES

- Rajshri H, Krishnappa NC, Sharma U, Ganne P. Long-standing Valsalva retinopathy. *BMJ Case Rep.* 2021;14(3):e240812. [DOI: 10.1136/bcr-2020-240812] [PMID: 33674301]
- Liu Y, Haq Z, Stewart JM. Atypical Valsalva retinopathy from habitual ear popping. *Am J Ophthalmol Case Rep.* 2020;19:100785. [DOI: 10.1016/j.ajoc.2020.100785] [PMID: 32613140]
- Karasavvidou EM, Athanasopoulos GP, Konstas AG, Tsirampidou EA, Tranos PG. Valsalva retinopathy associated with intranasal cocaine abuse: A case report. *Eur J Ophthalmol.* 2019;29(3):NP5–8. [DOI: 10.1177/1120672118799627] [PMID: 30207173]
- Castillo AJ. Case Report: Bilateral Valsalva Retinopathy in an Acutely Anemic Patient. *Optom Vis Sci.* 2022;99(3):303–7. [DOI: 10.1097/OPX.0000000000001856] [PMID: 34923539]

5. Miyaki T, Kida T, Oosuka S, Fukumoto M, Sato T, Nakajima M, et al. Valsalva retinopathy induced by handstand: a case report. *BMC Ophthalmol.* 2020;20(1):368. [DOI: 10.1186/s12886-020-01638-z] [PMID: 32928156]
6. García Fernández M, Navarro JC, Castaño CG. Long-term evolution of Valsalva retinopathy: a case series. *J Med Case Rep.* 2012;6:346. [DOI: 10.1186/1752-1947-6-346] [PMID: 23050866]
7. Bouladi M, Mghaieth F, Bouraoui R, Zerei N, Chaker N, El Matri L. Valsalva retinopathy occurring after general anesthesia. *Tunis Med.* 2019;97(4):595–8. [PMID: 31729711]
8. Waikar S, Srivastava VK. Valsalva retinopathy in a young healthy individual. *Med J Armed Forces India.* 2013;69(2):193–5. [DOI: 10.1016/j.mjafi.2012.04.015] [PMID: 24600100]
9. Kuruvilla O, Munie M, Shah M, Desai U, Miller JA, Ober MD. Nd: YAG membranotomy for preretinal hemorrhage secondary to valsalva retinopathy. *Saudi J Ophthalmol.* 2014;28(2):145–51. [DOI: 10.1016/j.sjopt.2014.02.006] [PMID: 24843309]
10. Graversen VA, Jampol LM, Meredith T, Landers III M, Slakter J, Brucker AJ, et al. Hemorrhagic unilateral retinopathy. *Retina.* 2014;34(3):483–9. [DOI: 10.1097/IAE.0b013e3182a48759] [PMID: 24096883]
11. Ali MM, Abdelafatah LE. Correlation between pregnancy and eye blindness (Valsalva retinopathy). *International Journal of Reproduction, Contraception, Obstetrics and Gynecology.* 2021;10(5):2060. [DOI: 10.18203/2320-1770.ijrcog20211538]
12. Celik Dulger S, Ozdal PC, Teke MY. Valsalva retinopathy: Long-term results and management strategies. *Eur J Ophthalmol.* 2021;31(4):1953–60. [DOI: 10.1177/1120672120936175] [PMID: 32586109]
13. Duane TD. Valsalva hemorrhagic retinopathy. *Trans Am Ophthalmol Soc.* 1972;70:298–313. [PMID: 4663671]
14. Suhan D, Padhy SK, Panda KG, Kelgaonkar A. Sub-internal limiting membrane haemorrhage as a manifestation of transiently deranged coagulation profile following SARS-CoV-2 infection. *BMJ Case Rep.* 2022;15(1):e247745. [DOI: 10.1136/bcr-2021-247745] [PMID: 35027390]
15. Shroff D, Kumar S, Naidu A, Gupta C, Shroff CM. Retinal vasoocclusive spectrum following COVID-19. *Indian J Ophthalmol.* 2022;70(4):1412–5. [DOI: 10.4103/ijo.IJO_2837_21] [PMID: 35326069]
16. Bauml CR, Ponugoti A, Enriquez AB, Vajzovic L. Valsalva-induced retinal hemorrhage as a secondary effect of COVID-19 disease. *Asia Pac J Ophthalmol.* 2021;10(1):125–6. [DOI: 10.1097/APO.0000000000000358] [PMID: 33512833]
17. Karadžić J, Kovačević I, Stefanović I, Risimić D. Terson's syndrome: A report of two cases. *Srp Arh Celok Lek.* 2015;143(9–10):595–8. [DOI: 10.2298/SARH1510595K] [PMID: 26727869]
18. Speilburg AM, Klemencic SA. Ruptured retinal arterial macroaneurysm: diagnosis and management. *J Optom.* 2014;7(3):131–7. [DOI: 10.1016/j.optom.2013.08.002] [PMID: 25000868]
19. Kirwan RP, Cahill MT. Nd: YAG laser hyaloidotomy for valsalva pre-macular haemorrhage. *Ir J Med Sci.* 2011;180(3):749–52. [DOI: 10.1007/s11845-009-0355-z] [PMID: 19495839]
20. Liu Z, Pan X, Bi H. Treatment of Valsalva retinopathy. *Optom Vis Sci.* 2014;91(11):e278–81. [DOI: 10.1097/OPX.0000000000000400] [PMID: 25279780]
21. Gurung RL. Multiple retinal holes secondary to valsalva retinopathy. *Case Rep Ophthalmol Med.* 2018;2018:8950682. [DOI: 10.1155/2018/8950682] [PMID: 29854517]
22. Tripathi A, Agarwal R, Chaurasia S. Role of Neodymium Double Frequency Laser Posterior Hyaloidotomy in Delayed Presentation of Sub-hyaloid Haemorrhage. *Cureus.* 2022;14(1):e21534. [DOI: 10.7759/cureus.21534] [PMID: 35223309]
23. Jaime L, Javier L, Nicolás RV, Diego B, Carlos AC. Nd: YAG membranotomy for sub-inner limiting membrane hemorrhage: a case report. *Rom J Ophthalmol.* 2021;65(1):76–9. [DOI: 10.22336/rjo.2021.15] [PMID: 33817439]

Валсалвина ретинопатија изазвана вежбањем – приказ болесника и преглед литературе

Игор Ковачевић^{1,2}, Јелена Мирковић¹, Весна Шобот¹, Младен Била¹, Јелена Василијевић^{1,2}

¹Универзитетски клинички центар Србије, Клиника за очне болести, Београд, Србија;

²Универзитет у Београду, Медицински факултет, Београд, Србија

САЖЕТАК

Увод Валсалвина ретинопатија је ретко обољење које се најчешће испољава једностраним, ређе обостраним, оштећењем вида које варира од дискретног скотома до потпуног губитка вида. Јавља се као резултат Валсалвиног маневра. У највећем броју случајева крварење је преретинално, иако се могу пронаћи и субретинална, интравитреална и витреална хеморагије. Валсалвина ретинопатија се често развија услед бројних окидачких активности као што су повраћање, кашљање, дизање тешког терета, порођај, интензивни аеробни тренинг и општа анестезија. Терапијске опције укључују праћење или инвазивне методе. Приказујемо случај премакуларног крварења услед Валсалвине ретинопатије изазване тренингом у теретани.

Приказ болесника Жена стара 34 године јавила се у Клинику за очне болести Универзитетског клиничког центра Србије жалећи се на изненадно, једнострано и безболно

ослабљење вида које се догодило током интензивне физичке активности. Најбоље коригована видна оштрина била је бројање прстију на пет метара удаљености. Преглед очног дна у мидријази показао је велико, јасно ограничено, премакуларно, субхијалоидно крварење са видљивом руптуром гране ретиналне вене. Пацијенткиња је конзервативно лечена. Три месеца после појаве симптома крварење се апсорбовало, а најбоље коригована видна оштрина била је 20/20. **Закључак** Валсалвина ретинопатија, иако ретко обољење, не треба да буде диференцијално дијагностички занемарена код случајева ретиналних и витреалних крварења. Стандардни третман је праћење и он је углавном довољан за потпуни опоравак вида; међутим, подаци из литературе указују да је потребан индивидуални приступ сваком пацијенту.

Кључне речи: Валсалвина ретинопатија; Валсалвин маневар; преретинално крварење; витреално крварење