



CASE REPORT / ПРИКАЗ БОЛЕСНИКА

Penetrating and blunt injuries of the heart – an abdominal surgeon's personal experience in Serbia

Aleksandar R. Karamarković^{1,2}, Jovan T. Juloski^{1,2}, Vladica V. Ćuk^{1,2}, Jovana M. Bojičić¹, Nemanja A. Karamarković³, Vladimir R. Cijan¹

¹Zvezdara University Clinical Center, Nikola Spasić Surgical Clinic, Belgrade, Serbia;

²University of Belgrade, Faculty of Medicine, Belgrade, Serbia;

³University Clinical Center of Serbia, Cardiosurgery Clinic, Belgrade, Serbia

SUMMARY

Introduction In the world with constantly increasing incidence of violence and trauma on one side, and more and more specialized surgeons on the other, the question about the role of abdominal surgeons in cardiac trauma emerges. The objective of this article is to show personal experience of an abdominal surgeon in managing heart trauma.

Outlines of cases We present two penetrating injuries and one blunt trauma of the heart successfully managed by an abdominal surgeon.

Conclusion Abdominal surgeons should feel comfortable with the decision to operate on greatly physiologically deranged patients with penetrating chest trauma, and not to delay the operation with conservative measures or with time-consuming transport to remote specialized facilities, since that could lead to greater death percentage of these patients.

Keywords: heart trauma; penetrating wound; abdominal surgeon

INTRODUCTION

Traumatic injuries are the leading cause of death among people younger than 45 years [1, 2]. Right after injuries of the brain and spinal cord, cardiac injuries are the second most common cause of lethal outcome of trauma victims [2].

Heart can be injured in two possible manners, by non-penetrating/blunt trauma (blunt cardiac injury) and penetrating trauma [3, 4].

Trauma caused from blunt forces can have a wide clinical presentation, from practically silent presentation or transient arrhythmias to fatal cardiac rupture [5, 6], with the latter as the most common cause of death in 64% of blunt cardiac injury cases, followed by tears at the venous-atrial confluence (33%) and dissection of coronary arteries (2%) [7]. The most common site of myocardial rupture is the wall of the right ventricle, usually immediately fatal. Those who survive long enough to reach the hospital can present with cardiac tamponade or pseudoaneurysm [8, 9].

One of the most lethal medical emergencies is certainly penetrating injury of the heart [10]. Estimations are that almost 94% of the injured die before reaching the hospital [10]; reports about in-hospital death rate vary 8.5–50% or even more [10, 11, 12]. The range of mortality in these reports can be explained by patient inclusion criteria, variety of conjoined injuries, and the mechanism of the occurrence. As in blunt cardiac injuries, the right ventricle is the most common site of injury in penetrating

injuries, but with similar percentage of injury for both ventricles [2, 10]. Cardiac tamponade is the common manifestation in initial survivors, who are usually young males, with stab/gunshot wound to the chest [3].

Objective of this article is to show personal experience of an abdominal surgeon in managing heart trauma.

Surgery of the wounded heart – the beginnings

The first steps in cardiac surgery were made in trauma, as lifesaving procedures [13, 14]. The first attempt to suture a human heart was performed by a Norwegian doctor named Axel Hermansen Cappelen in 1895. The patient was a young male with a stab wound to the left ventricle. After initial improvement, the patient died on the third postoperative day [15]. The first successful suture of the heart is considered to be the one performed by Ludwig Rehn on September 9, 1896 in Frankfurt am Mein. He operated on a 22-year-old male with a stab wound to the right ventricle. As a peculiarity, the unfortunate patient got stabbed two days earlier, and Rehn operated after returning from a journey. After the procedure, the patient completely recovered [16]. The first successful suture of the left ventricle described in the literature was done in Rome, Italy, by Antonio Parrozzani on April 18, 1897. The patient was also a young male with a stab wound to the left side of the chest. The man recovered completely

Received • Примљено:
December 31, 2020

Accepted • Прихваћено:
June 7, 2021

Online first: June 21, 2021

Correspondence to:

Jovan JULOSKI
Nikola Spasić Surgical Clinic
Zvezdara University Clinical
Center
Dimitrija Tucovica 161
11000 Belgrade, Serbia
jovan.juloski@gmail.com

after a 75-minute-long operation [17]. The first large series of successfully managed heart wounds was published by Dwight Harken, an American war surgeon [14, 15].

First steps in Serbia

The first successful operation of a wounded heart in Serbia was performed in 1928 by Jovan Mijušković, in the city of Valjevo [14, 18]. The patient was a 15-year-old male with a gunshot wound to the right ventricle. The operation was performed in local anesthesia, and lasted only 35 minutes as the author described it. The postoperative period was long and with numerous complications, but eventually the boy was discharged in good condition [18]. This operation was the very first step in surgery of the heart, decades before cardiac surgery even emerged as a separate field, in former Kingdom of Yugoslavia, now Serbia. Jovan Mijušković (1886–1944) studied medicine in Vienna, and conducted his surgery residency in Vienna and Belgrade. He was chief of surgery in the cities of Čuprija and Valjevo. In 1936 he was appointed as a professor for the subject History of Medicine, at the Faculty of Medicine, University of Belgrade. During his career, he published numerous papers in domestic and foreign scientific Journals [14]. He was briefly the minister of health during World War II. In 1942 he founded Department of Surgery at the Belgrade City Hospital, currently Nikola Spasić Surgical Clinic, Zvezdara University Clinical Center in Belgrade [14]. One of the cases was managed at this institution, at which some of the authors of this paper practice surgery.

The role of general surgeons in heart trauma, in the era of modern cardiac surgery

Several authors published results of specialized centers in managing heart wounds, combining interventional, radiologic, and also surgical approach [19–22]. It is obvious that diagnosis made swiftly and very early, with an organized and available heart team (interventional cardiologists, radiologists, and cardiac surgeons), which are available in specialized centers, provide favorable results [4, 22]. In some parts of the world, where trauma and cardiothoracic surgeons are not easily available, penetrating thoracic trauma is becoming more frequent, as well as the need for thoracotomy [10, 23]. It is also worth mentioning that general surgeons and general surgery residents are becoming more specialized by the day, and less “adventurous” when it comes to operating beyond their area of specialization [24]. Fear of being sued in case of failure, is the most frequent reason for referring chest trauma to more specialized centers and staff [24]. In recent years, some authors published results with an intent to encourage general surgeons to engage in cardiac trauma and emergency thoracotomy in general [24, 25]. Doll et al. [24] stated that in all cardiac wounds they applied a simple direct suture of the heart wall, highlighting that there was no need for an expertise of a cardiac surgeon nor extracorporeal circulation. They speculated that patients with complicated injuries which would require bypass of the heart would most likely

die before reaching the hospital. It is their strong opinion that, apart from mediastinal vessels and esophageal injuries, a great majority of penetrating thoracic trauma can be managed with simple operative techniques. They concluded that general surgeons should feel comfortable with the decision to operate on greatly physiologically deranged patients with penetrating chest trauma, and not to delay the operation with conservative measures or with time-consuming transport to remote specialized facilities, since that could lead to greater death percentage of these patients.

REPORTS OF CASES

Case 1

A 23-year-old patient was immediately admitted to the Clinic of Emergency surgery, University Clinical Center of Serbia in Belgrade for suicide attempt, stabbed in the epigastrium. He was hemodynamically unstable with clinical signs of hemorrhagic shock. An emergency operation was performed. Abdominal cavity was opened by medial laparotomy, penetrating injuries of the left liver lobe, the diaphragm, and the diaphragmatic side of the left heart ventricle were verified intraoperatively. Furthermore, left ventricle penetrating hole was sewn by transdiaphragmatic approach with several interrupted stiches preserving left coronary artery (Figures 1 and 2). Then, the diaphragm was reconstructed and the left lobe of the liver was sutured.

The postoperative period was uneventful and the psychiatrist has been consulted. The hospital discharge took place on the 10th postoperative day. The patient was in good condition.

Case 2

A 75-year-old man with blunt thorax injuries was hospitalized at the Clinic of Emergency Surgery, University Clinical Center of Serbia in Belgrade, due to a fall from a height of approximately 2.5 m. In this case, there were fractures of ribs V–VIII and consequential hemopneumothorax. Firstly, the thoracic tube was placed through the second intercostal space rightward on the midclavicular line. Initially, air and blood appeared in the tube, after which the lung re-expansion and blood control was achieved.

The next day, the massive hemothorax was treated and the patient underwent emergency surgery.

Right posterolateral thoracotomy was performed through the fifth intercostal space. Intraoperatively, hemothorax and laceration of the right atrium auricle as a consequence of previous adhesions following acceleration-deceleration injuries was verified. A vascular clamp was placed under laceration and auricle sutured continuously (Figures 3 and 4).

The postoperative period was uneventful. The patient was discharged on the 12th postoperative day in relatively good condition.

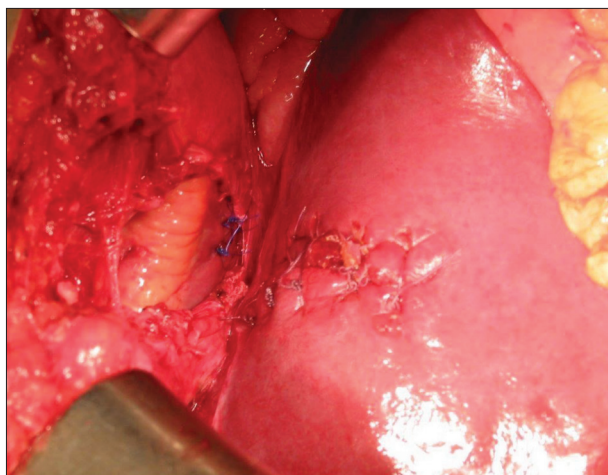


Figure 1. Case 1, transabdominal view of the sutured heart, sutured liver, and the rupture point of the diaphragm

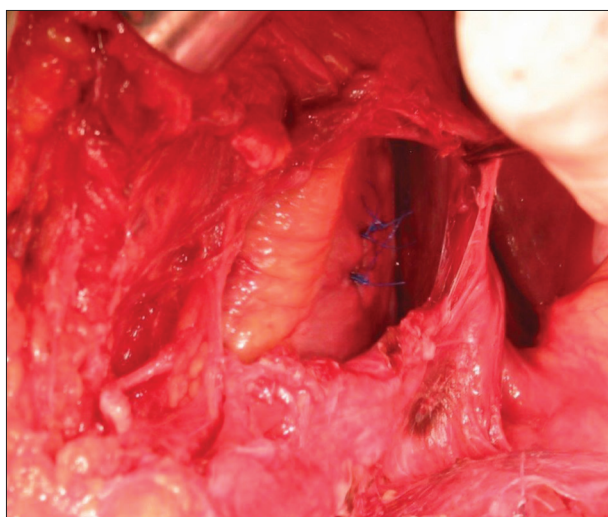


Figure 2. Case 1, view of the sutured heart as seen transabdominally through the ruptured diaphragm

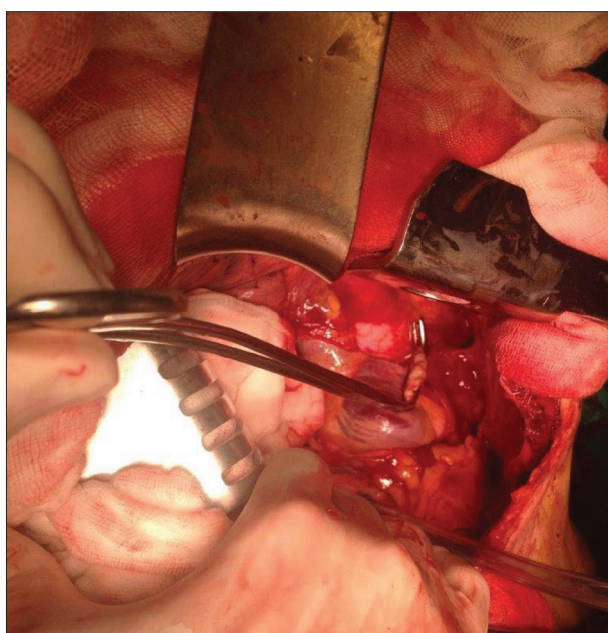


Figure 3. Case 2, clamped auricle of the right atrium of the heart

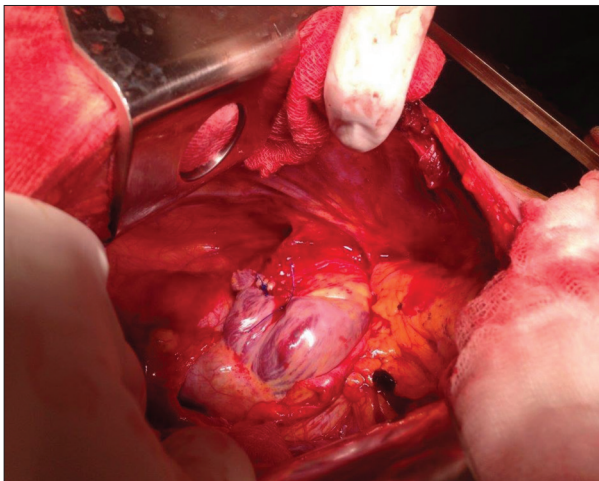


Figure 4. Case 2, sutured auricle of the right atrium of the heart

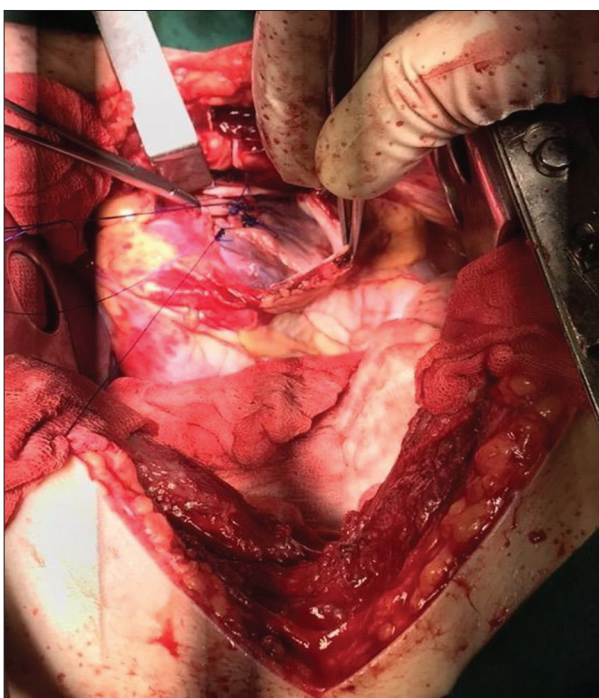


Figure 5. Case 3, interrupted sutures on the myocardium of the left ventricle

Case 3

A young 17-year-old patient was found lying down on the street, in close proximity to the Nikola Spasić Surgical Clinic, with a penetrating wound through the left side of the chest, close to the sternum. According to an eyewitness, no more than 10 minutes had passed since the stabbing, by an unknown perpetrator. He was immediately admitted to an intensive care unit, hemodynamically unstable and somnolent, with hemoglobin values of 10.7 g/dl and hematocrit 31.5%. Inotropes were administered along with massive fluid resuscitation, two units of fresh frozen plasma and two units of erythrocytes. A stab wound through the chest wall at the intersection of the fifth intercostal space and left midclavicular line was identified with moderate

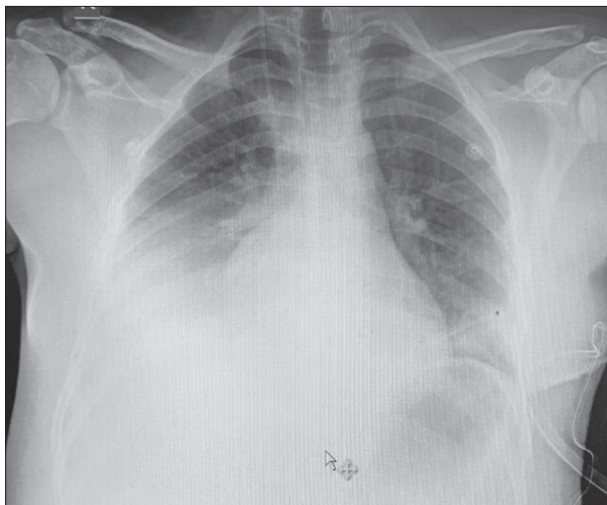


Figure 6. Case 3, chest X-ray before pleural puncture on the right side due to pleural effusion, third postoperative day

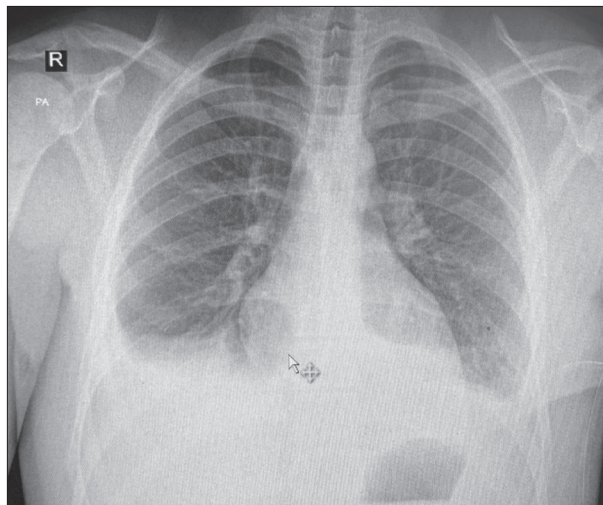


Figure 7. Case 3, chest X-ray after pleural puncture on the right side due to pleural effusion, third postoperative day

active bleeding. Immediately after the admission to the Intensive Care Unit, chest X-ray revealed a massive hemothorax, and a chest tube was inserted through the wound. After a short period of observation, the tube evacuated a total amount of 1500 ml of blood, and a sudden drop in hemoglobin values to 4.9 g/dl and in hematocrit to 14.5% occurred. He was promptly transferred to the operating room, with continuous norepinephrine and dopamine i.v. drip; two additional units of fresh frozen plasma and three units of blood were administered, as well as one unit of cryoprecipitate. Left hemithorax was opened via anterolateral thoracotomy through the fifth intercostal space. A stab wound through the full thickness of the left ventricle wall was identified, with the breach of endocardium and synchronous, pulsatile bleeding. The myocardial wound was approximately 4 cm long, with much wider pericardial laceration. Also, left internal thoracic artery was incompletely transected, with a lesion of the sternum at the same level and hemothorax and hemopericardium present. Other intrathoracic and mediastinal organs were intact. The myocardium was closed with prolene 2.0 and 3.0 interrupted sutures; pericardium was sutured in the same fashion, with narrow drain inserted in the pericardial space (Figure 5). The internal thoracic artery was suture ligated, and after thorough rinsing of the hemothorax and chest tube placements, the chest wall was closed. Postoperatively, regular transthoracic echocardiographs were performed on five occasions, with no rhythm or hemodynamic irregularities. On the second postoperative day he was extubated. Due to renal impairment caused by massive blood loss, a nephrologist was called into consult twice, but significant therapeutic changes and dialysis were not necessary. On the third postoperative day, due to right pleural effusion, a pleural puncture and fluid evacuation was performed (Figures 6 and 7). All drains and tubes were gradually pulled out. The patient received 11 units of blood, 10 units of fresh frozen plasma, one unit of thrombocytes, and six units of cryoprecipitate. The patient spent seven days in the Intensive Care Unit and four more days in the

Semi-Intensive Care Ward, and was finally discharged on the 12th postoperative day in good condition.

Written consent for publication of this article has been obtained by the patients or the patients' family members.

DISCUSSION

The incidence of cardiac injuries has risen in the past few decades severalfold. In civilian settings, most penetrating injuries are stab wounds, with an increasing percentage of fire arm lesions [24, 26]. Already recognized as one of the most lethal medical emergencies, penetrating heart injuries have an in-hospital death rate, as said earlier in this paper, from 8.5% to 50% or even more [10–12]. We had the fortune to see all three of our patients successfully discharged alive.

“The quadrangle of death” is the most frequent localization of cardiac injuries on the chest wall. It goes above the diaphragm, under the clavicles and medial to the nipples. Some previous authors reported that one chamber injury accounts for 70%, and multiple chamber injury accounts for 30% of all injuries [27]. This complies with our small series, in which all three patients had one chamber injury, two left ventricle injuries, and one right atrium auricle injury. According to previous findings, in penetrating injuries, both ventricles are affected with similar frequency, but with the right ventricle as more common site of entry, since it forms most of the anterior surface of the heart. In only three cases (66.66%), injuries were of the left ventricle [2].

At least one of the three symptoms of Beck's trinity (hypotension, elevated central venous pressure, dull heart murmurs) is present in penetrating heart injuries [4]. One must have in mind that tension pneumothorax, also a chest injury, can mimic all of these symptoms, but with auscultatory silence on the affected side. Full preoperative diagnostics can only be conducted in hemodynamically stable patients [4]. On the other hand, when we face massive bleeding, cardiac tamponade, parasternal

wounds, unstable patients in general, immediate thoracotomy, without detailed diagnostics, is mandatory [4, 24]. Echocardiography, if allowed by hemodynamic stability, is very useful in detecting trauma of the heart [28]. One of very informative but time-consuming diagnostic procedures, heart catheterization, is by some authors not necessary in the initial phase of diagnostics, but is very important in solving complex injuries, and practically mandatory in the post-surgical phase, in order to exclude secondary complications, which can be expected in up to 10% of cases [4, 22].

Swift and precise diagnosis, reanimation, expeditious transport and timely surgical intervention are of utmost importance in managing cardiac injuries. Equipped centers and specialized cardiac teams are certainly ideal for injured patients. However, even in the era of more and more specialized branches in medicine and surgery, the role of abdominal surgeons in cardiac trauma is still important. Apart from mediastinal vessels and esophageal injuries,

a great majority of penetrating thoracic trauma can be managed with simple operative techniques. Abdominal surgeons should feel comfortable with the decision to operate on greatly physiologically deranged patients with penetrating chest trauma, and not to delay the operation with conservative measures or with time-consuming transport to remote specialized facilities, since that could lead to greater death percentage of these patients.

ACKNOWLEDGMENT

We would like to express our appreciation to prof. Dušan Velimirović, whose tremendous knowledge has helped greatly in writing this paper, and whose knowledge and skills will always represent one of the cornerstones of Serbian cardiac surgery.

Conflict of interest: None declared.

REFERENCES

1. Yousef R, Carr JA. Blunt cardiac trauma: a review of the current knowledge and management. *Ann Thorac Surg.* 2014;98(3):1134–40.
2. Restrepo CS, Gutierrez FR, Marmol-Velez JA, Ocazionez D, Martinez-Jimenez S. Imaging patients with cardiac trauma. *Radiographics.* 2012;32(3):633–49.
3. Leite L, Gonçalves L, Nuno Vieira D. Cardiac injuries caused by trauma: Review and case reports. *J Forensic Leg Med.* 2017;52:30–4.
4. Velinovic M, Velimirovic D, Vranes M, Djukic P, Mikic A, Putnik S, et al. Heart Injuries – Still a Challenge for Cardiac Surgery. *The Open Cardiovascular and Thoracic Surgery Journal.* 2009;2(1):38–42.
5. Bellister SA, Dennis BM, Guillamondegui OD. Blunt and Penetrating Cardiac Trauma. *Surg Clin North Am.* 2017;97(5):1065–76.
6. Singh S, Heard M, Pester JM, Angus LD. Blunt Cardiac Injury. 2021 Jul 25. In: *StatPearls [Internet].* Treasure Island (FL): StatPearls Publishing; 2021 Jan–.
7. Turan AA, Karayel FA, Akyildiz E, Pakis I, Uzun I, Gurpinar K, et al. Cardiac injuries caused by blunt trauma: an autopsy based assessment of the injury pattern. *J Forensic Sci.* 2010;55(1):82–4.
8. El-Chami MF, Nicholson W, Helmy T. Blunt cardiac trauma. *J Emerg Med.* 2008;35(2):127–33.
9. Helmy TA, Nicholson WJ, Lick S, Uretsky BF. Contained myocardial rupture: a variant linking complete and incomplete rupture. *Heart.* 2005;91(2):e13.
10. Campbell NC, Thomson SR, Muckart DJ, Meumann CM, Van Middelkoop I, Botha JB. Review of 1198 cases of penetrating cardiac trauma. *Br J Surg.* 1997;84(12):1737–40.
11. Isaza-Restrepo A, Bolívar-Sáenz DJ, Tarazona-Lara M, Tovar JR. Penetrating cardiac trauma: analysis of 240 cases from a hospital in Bogota, Colombia. *World J Emerg Surg.* 2017;12:26.
12. Rahim Khan HA, Gilani JA, Pervez MB, Hashmi S, Hasan S. Penetrating cardiac trauma: A retrospective case series from Karachi. *J Pak Med Assoc.* 2018;68(8):1285–7.
13. Alexi-Meskishvili V, Böttcher W. Suturing of penetrating wounds to the heart in the nineteenth century: the beginnings of heart surgery. *Ann Thorac Surg.* 2011;92(5):1926–31.
14. Velimirović D. Dr Jovan Mijušković, precursor of cardiac surgery in Serbia. *Srp Arh Celok Lek.* 2020;148(1–2):124–8.
15. Alivizatos PA. Dwight Emary Harken, MD, an all-American surgical giant: Pioneer cardiac surgeon, teacher, mentor. *Proc (Bayl Univ Med Cent).* 2018;31(4):554–7.
16. Rehn L. Ueber penetrirrende Herzwunden und Herznaht. *Archiv für klinische Chirurgie.* 1897;55:315–29.
17. Parrozzani A. I primi due casi di sutura del ventricolo sinistro. *Bulletino della Reale Accademia Medica Di Roma.* 1897;22:243–60.
18. Mijušković J. Jedan uspeo šav na srcu. *Srp Arh Celok Lek.* 1928;30(12):963–73.
19. Shioya N, Inoue N, Muto H, Tomita A, Tsukamoto Y, Kawashima N, et al. Delayed diagnosis of traumatic ventricular septal perforation in penetrating chest injury: hematoma formation in the ventricular septum in CT suggests perforation. *Acute Med Surg.* 2019;6(3):321–4.
20. Pracon R, Grygoruk R, Konka M, Kepka C, Demkow M. Percutaneous Closure of Ventricular Septal Defect Resulting From Chest Stab Wound in an 18-Year-Old Boy. *Circ Cardiovasc Imaging.* 2018;11(11):e008326.
21. Han FY, Reyes KG, Bleiweis MS. Managing extensive mitral valve and ventricular septal injuries secondary to penetrating trauma. *Eur J Cardiothorac Surg.* 2018;53(1):284–5.
22. Cottini M, Pergolini A, Ranocchi F, Musumeci F. The Role of Heart Team Approach in Penetrating Cardiac Trauma: Case Report and Review of the Literature. *Braz J Cardiovasc Surg.* 2018;33(1):99–103.
23. Van Vledder MG, Van Waes OJF, Kooij FO, Peters JH, Van Lieshout EMM, Verhofstad MHJ. Out of hospital thoracotomy for cardiac arrest after penetrating thoracic trauma. *Injury.* 2017;48(9):1865–9.
24. Doll D, Eichler M, Vassiliu P, Boffard K, Pohlemann T, Degiannis E. Penetrating Thoracic Trauma Patients with Gross Physiological Derangement: A Responsibility for the General Surgeon in the Absence of Trauma or Cardiothoracic Surgeon? *World J Surg.* 2017;41(1):170–5.
25. Yoong IRW, Heng G, Mathur S, Lim WW, Goo TT. Outcomes of emergency thoracotomy for trauma in a general hospital in Singapore. *Asian Cardiovasc Thorac Ann.* 2018;26(4):285–9.
26. Rashid MA, Wikström T, Ortenwall P. Cardiac injuries: a ten-year experience. *Eur J Surg.* 2000;166(1):18–21.
27. Takagi H, Mori Y, Murase K, Hirose H. Nail gun penetrating cardiac injury. *Eur J Cardiothorac Surg.* 2003;23(5):841.
28. Saranteas T, Mavrogenis AF, Mandila C, Poularas J, Panou F. Ultrasound in cardiac trauma. *J Crit Care.* 2017;38:144–51.

Пенетрантне и тупе повреде срца – лична искуства абдоминалног хирурга у Србији

Александар Р. Карамарковић^{1,2}, Јован Т. Јулоски^{1,2}, Владица В. Ћук^{1,2}, Јована М. Бојичић¹, Немања А. Карамарковић³, Владимир Р. Цијан¹

¹Клиничко-болнички центар „Звездара“, Клиника за хирургију „Никола Спасић“, Београд, Србија;

²Универзитет у Београду, Медицински факултет, Београд, Србија;

³Клинички центар Србије, Клиника за кардиохирургију, Београд, Србија

САЖЕТАК

Увод У свету у ком се стално повећава инциденца насиља и повреда, а хирурзи се едукују за све уже хириршке гране, поставља се питање о улози абдоминалних хирурга у кардијалној трауми.

Циљ овог рада је да прикаже лична искуства абдоминалног хирурга у решавању повреда срца.

Прикази болесника Приказана су два случаја пенетрантне повреде срца и једна тупа повреда срца, које је успешно излечио абдоминални хирург.

Закључак Требало би да се абдоминални хирурзи слободно упусте у операцију хемодинамски нестабилних болесника са пенетрантним повредама грудног коша. Не треба да одлажу операцију спровођењем конзервативних мера или транспортовањем у удаљене специјализоване центре, јер то може довести до веће смртности ових болесника.

Кључне речи: повреде срца; пенетрантне повреде; абдоминални хирург