

CURRENT TOPIC / AKTUELNA TEMA

Proton beam therapy

Marija Popović-Vuković¹, Jelena Bokun^{1,2}, Dragana Stanić^{1,2}, Borko Nidžović¹, Marina Nikitović^{1,2}¹Institute of Oncology and Radiology of Serbia, Belgrade, Serbia;²University of Belgrade, Faculty of Medicine, Belgrade, Serbia**SUMMARY**

Proton beam therapy (PBT) is an advanced type of radiotherapy that shows a dosimetric advantage over photon beam therapy and provides superior dose distribution. PBT may improve patient survival by improving the local disease control while reducing toxicity to normal organs, which may result in fewer treatment-related complications. During the last decade, technological progress has opened up new possibilities in the planning and conducting of PBT, so indications have gradually expanded to different cancers. However, many biological aspects of PBT are still unclear, and its role in clinical settings is controversial. Proton therapy is considered to be safe and effective for different types of pediatric cancers, and suitable in treatment of ocular melanomas, chordomas, and chondrosarcomas. Future research and more prospective clinical studies with long-term follow-up are required in order to clearly determine the benefits and proper indications for PBT.

Keywords: proton therapy; radiotherapy; cancer

INTRODUCTION

Proton beam therapy (PBT) is a modern radiotherapy (RT) technique that uses protons. In 1946, Wilson first proposed PBT for medical use considering the advantages of proton RT compared with conventional photon RT. This suggestion was based on the known physical property of protons, which is that they slow down during penetration of tissue [1, 2].

The first PBT patient series was published in 1958 by researchers at the Lawrence-Berkeley National Laboratory, where patients with radio-resistant tumors such as chordoma and melanoma were initially treated. Technological progress opened up new possibilities in PBT planning and conducting, so indications were gradually expanded to other cancers. The expenses of PBT are much higher compared to conventional photon RT due to the high cost of proton beam technology and maintenance. First proton center was established in 1990 in California, and today there are about 70 proton therapy centers worldwide with more than 190,000 patients treated with PBT [3, 4].

Increasingly more evidence has been showed for the advantages of PBT in clinical use, but it is not suitable for every tumor type and site. Also, some biological aspects of PBT are still unclear. It is necessary to understand the advantages and limitations of protons [5].

Physical and biological aspects of PBT

Protons are heavy charged particles which continuously slow down during penetration of matter as they slow down in a function of depth. Energy loss continues until the entire

energy of the proton is depleted, after which they come to an abrupt stop, which results in a steep and localized peak of dose. This process of dose deposition produces a characteristic depth-dose curve – the Bragg curve. The point of the highest energy loss of proton is called the Bragg peak (Figure 1). The depth of the peak depends on the initial proton energy, and the deposited dose beyond the range is minimal. PBT dose distribution is superior to the dose distribution of conventional photon RT, but it is still debatable whether the dosimetric advantages of PBT translates to clinically relevant decreases in toxicity. Different randomized clinical trials which compare protons and photons are currently ongoing [2, 6].

The proton dose is defined as gray (Gy), which is calculated by multiplying the physical dose by the relative biological effectiveness (RBE). For photon and electron external beam RT, the RBE is considered to be 1. Proton RT is planned assuming that the proton RBE relative to photons is 1.1. However, experimental

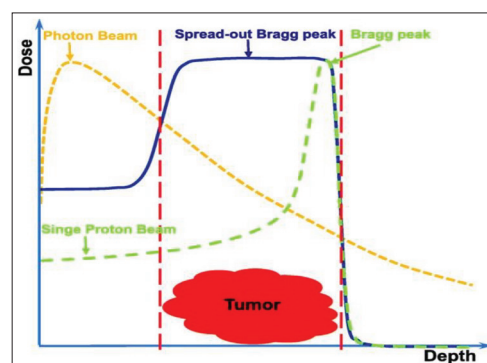


Figure 1. The diagram of dose distributions for photon, single proton beam, and spread-out proton beam [5]

Received • Примљено:

January 12, 2021

Revised • Ревизија:

September 22, 2021

Accepted • Прихваћено:

October 1, 2021

Online first: October 11, 2021

Correspondence to:

Marija POPOVIĆ-VUKOVIĆ
Institute of Oncology and
Radiology of Serbia
Pasterova 14
11000 Belgrade
Serbia
marija.popovic@ncrc.ac.rs

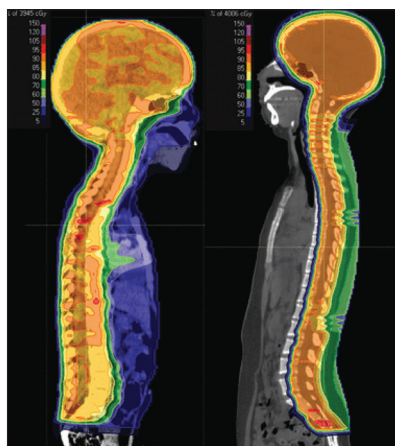


Figure 2. Dose distributions for photon (left) and proton (right) craniospinal radiotherapy plan [12]

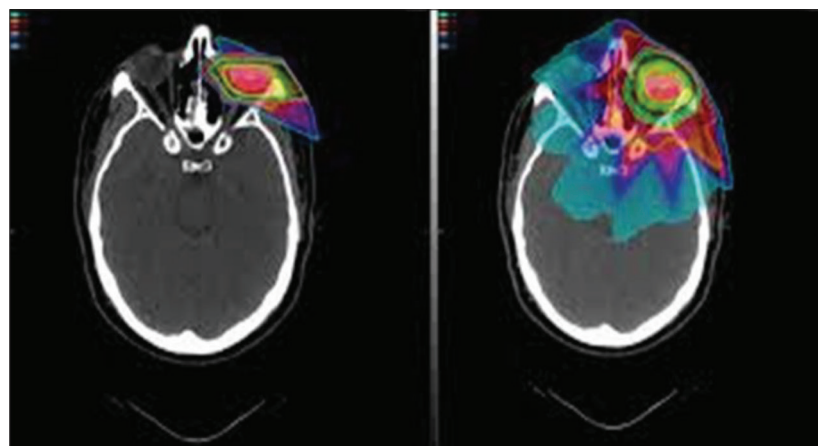


Figure 3. Isodose distributions for proton (left) and photon (right) treatment plans for ocular melanoma [18]

evidence showed that proton RBE is not constant and that it changes along the treatment field. According to *in vitro* studies, the highest RBE is found at the distal edge and in the distal fall-off region within the Bragg curve. Still, there remain several uncertainties in understanding variations in biological response after proton irradiation compared to photon irradiation. Current experiments on the response of normal and tumor tissue to proton therapy should be continued [7].

Proton therapy for different cancers

The heavier subatomic particles deliver their energy more precisely to the tumor area compared to photons. The justification for the clinical use of proton therapy is the possibility for dose escalation to the tumor, which leads to better local disease control probability. This is possible due to better sparing of surrounding healthy tissue compared to other RT techniques. Due to the reduced treatment volume and a lower integral dose, patient tolerance is increased with lower morbidity rate. PBT may improve the survival rate with significant reduction of treatment-related complications, which results in preserving the quality of life of treated patients.

As other highly conformal photon therapy techniques, PBT is indicated for tumors located close to serial organs, where a small radiation overdose can lead to severe complications. Irregular shaped lesions close to critical structures are suitable for proton RT treatment [3, 8].

Pediatric cancers

Radiation therapy plays an important role as part of multimodal treatment for many pediatric malignancies, especially for brain tumors, sarcomas, lymphomas and neuroblastoma. Treating children with RT is a great challenge because they have higher radiation sensitivity and lower radiation tolerance than adults, and late toxicity of RT is an issue for long-term survivors. Reduction in the quality of life due to growth and development retardation, as well as secondary malignancies, remains a significant problem for treated children. It is necessary to provide effective

radiation therapy with the least possible morbidity. The physical characteristics of protons are promising in terms of achieving significant clinical benefits [9, 10].

Dosimetric comparison studies between photons and protons in treatment of medulloblastoma, ependymoma, Ewing sarcoma, rhabdomyosarcoma showed the superiority of PTB over photons in reducing dose to surrounding healthy organs and tissues (Figure 2). Clinical results are limited, but the first evidence confirmed similar survival rates with fewer treatment-related side effects for PBT, which could have positive impact on the quality of life of treated children [11].

Gross et al. [13] reported favorable neurocognitive outcomes in pediatric patients with brain tumors with the use of PBT compared with photon RT, according to findings from a study that included 125 patients.

Kahalley et al. [14] published the first longitudinal study comparing intellectual outcomes between pediatric patients treated for medulloblastoma with PBT and photon RT, and showed that PBT was associated with superior intellectual outcomes.

On the other hand, Kralik et al. [15] pointed out that pediatric patients with brain tumors treated with PBT have a high incidence of radiation necrosis, frequently distant from the tumor area. Multiple chemotherapy agents were significant risk factors associated with radiation necrosis.

Bhattacharya et al. [16] did a retrospective imaging review of 46 patients with brain tumors treated with PBT. Large vessel progressive cerebral arteriopathy was described in 25% of patients, which is more than in previously reported studies. This study also pointed out the appearance of white matter changes remote from the region of irradiation in two patients.

There is a need for continued close follow-up of children treated with PBT, which will enable us to better understand long-term effects, safety, and benefits of this therapy.

Ocular tumors

Ocular melanomas represent a perfect model for a malignant tumor requiring high-dose RT with complex dose

distribution within the target volume, and PBT is recognized to be one of the main RT treatment options for these and other ocular tumors [17] (Figure 3).

PBT for ocular melanoma results in excellent local control of disease with preserved quality of life of treated patients. Van Beek et al. [19] published a retrospective study of 306 patients with uveal melanoma. Half of patients were treated with PBT and the other half with fractionated stereotactic photon beam radiotherapy (fSRT). The five-year local tumor control rates were 96.1% for both groups. However, vitreous hemorrhage was significantly less common after PBT than after fSRT.

PBT is also a new option for conservative treatment of conjunctival squamous cell carcinoma. Milazzotto et al. [20] reported a retrospective analysis of 15 patients with conjunctival squamous cell carcinoma treated with PBT who had gross residual disease after surgery or were not candidates for surgery. Overall survival and disease-free survival rates were 86.6% each, after a median follow-up of 48 months. Treatment was well tolerated, without significant acute or late toxicity.

Chordoma of the skull base and spine

Chordoma of the skull base is challenging to treat due to tumor location, proximity to critical neural and vascular structures, and tumor radioresistance. Gross total resection of these tumors is often not possible, so adjuvant radiation therapy is an important treatment modality which can improve local disease control and overall survival. High-dose photon-based RT can be used, but usually cannot achieve therapeutic dosage because of the proximity to dose-limiting structures: the optic nerve, chiasm, the brain stem, the spinal cord, and the brain [21].

Application of proton therapy with simultaneous integrated boost for these malignancies made possible the delivery of radical doses to target volumes while minimizing toxicity for organs at risk. This treatment approach affords excellent local disease control while sparing normal surrounding structures [22].

Treatment of spinal and sacral chordoma represents great challenge because of the proximity of the spinal cord and nerve roots. Radiation tolerance of the spinal cord is considered at 48–54 Gy, much below necessary doses adequate for local control for these tumors. Chordoma require high radiation doses of 60–70 Gy. PBT offers a dose escalation for treatment of tumors in this location, but the current clinical evidence is still limited and further research is needed [23].

Reirradiation

Tumor recurrence is in most cases unresectable because of many different factors. The possibility of reirradiation

is limited by the previously applied RT treatment, dose constrains for surrounding critical organs, and the time period passed since the previous radiation treatment. The high conformality and rapid fall-off of radiation dose at the distal end of the target offer significant possibility for reirradiation with protons. By sparing adjacent normal tissues, proton therapy can more safely apply definitive instead of palliative doses of reirradiation [3, 24].

Saeed et al. [25] published a series of 45 patients with recurrent glioblastoma multiforme treated with proton reirradiation 2012–2018. The median interval between initial diagnosis and disease recurrence was 20 months. In this series, 40 patients completed full reirradiation course with a median dose of 46.2 Gy. The median progression-free survival was 13.9 months with median overall survival of 14.2 months. One grade 3 acute toxicity was observed, three patients developed grade 3 late toxicity, and no grade 4 or 5 toxicities were reported.

Although a small number of published studies on reirradiation with PBT have shown promising results, adequate patient selection is required for the careful use of proton reirradiation.

Other tumors

PBT has been used for treating different malignancies, including central nervous system, head and neck tumors, prostate, breast, liver, esophageal, and lung cancer. However, the role of PBT in clinical settings is still controversial, and there are certain technical challenges in planning and delivery for different treatment sites [5].

CONCLUSION

PBT is an advanced type of RT that achieves a dose distribution generally superior to photon beam therapy. This may allow dose escalation to the tumor target volume, better sparing of surrounding tissues, thus potentially improving local disease control and survival while at the same time reducing toxicity and improving the quality of life of treated patients. Still, a question remains as to whether dosimetric advantages of PBT leads to clinically relevant decreases in toxicity. Clinical evidence supporting wide use of protons is mixed despite its high potential. Promising results have been reported for many types of cancers; however, they are based on small studies. There are still uncertainties about the radiobiology of protons that can have an impact on the molecular and cellular effects of PBT. Further research and prospective clinical studies with extensive follow-up of treated patients are needed in order to determine effectiveness and safety of PBT.

Conflict of interest: None declared.

REFERENCES

- Tian X, Liu K, Hou Y, Cheng J, Zhang J. The evolution of proton beam therapy: Current and future status (Review). *Mol Clin Oncol*. 2018;8(1):15–21.
- Paganetti H, Beltran C, Both A, Dong L, Flanz J, Furutani K, et al. Roadmap: proton therapy physics and biology. *Phys Med Biol*. 2020.
- Yuan TZ, Zhan ZJ, Qian CN. New frontiers in proton therapy: applications in cancers. *Cancer Commun (Lond)*. 2019;39(1):61.
- Lawrence JH, Tobias CA, Born JL, McCombs RK, Roberts JE, Anger HO, et al. Pituitary irradiation with high-energy proton beams: A preliminary report. *Cancer Res*. 1958;18(2):121–34.
- Hu M, Jiang L, Cui X, Zhang J, Yu J. Proton beam therapy for cancer in the era of precision medicine. *J Hematol Oncol*. 2018;11(1):136.
- Mohan R, Grosshans D. Proton Therapy – Present and Future. *Adv Drug Deliv Rev*. 2017;109:26–44.
- Ilicic K, Combs S, Schmid T. New insights in the relative radiobiological effectiveness of proton irradiation. *Radiat Oncol*. 2018;13(1):6.
- Byun H, Han M, Yang K, Kim J, Yoo G, Koom W, et al. Physical and Biological Characteristics of Particle Therapy for Oncologists. *Cancer Res Treat*. 2021;53(3):611–20.
- Merchant T, Kortmann R, editors. *Pediatric Radiation Oncology*. Cham: Springer International Publishing; 2018. p. 462.
- Steinmeier T, Schleithoff S, Timmermann B. Evolving radiotherapy techniques in paediatric oncology. *Clinical Oncology*. 2019;31(3):142–50.
- Thomas H, Timmermann B. Paediatric proton therapy. *Br J Radiol*. 2020;93(1107):20190601.
- Tsang D, Patel S. Proton beam therapy for cancer. *CMAJ*. 2019;191(24):E664–6.
- Gross J, Powell S, Zelko F, Hartsell W, Goldman A, Fangusaro J, et al. Neuropsychological outcomes of pediatric brain tumor patients treated with proton or X-ray radiation therapy. *Int J Radiat Oncol Biol Phys*. 2018;102(3):S52.
- Kahalley LS, Peterson R, Ris MD, Janzen L, Okcu MF, Grosshans DR, et al. Superior Intellectual Outcomes After Proton Radiotherapy Compared with Photon Radiotherapy for Pediatric Medulloblastoma. *J Clin Oncol*. 2020;38(5):454–61.
- Kralik SF, Ho CY, Finke W, Buchsbaum JC, Haskins CP, Shih CS. Radiation Necrosis in Pediatric Patients with Brain Tumors Treated with Proton Radiotherapy. *AJNR Am J Neuroradiol*. 2015;36(8):1572–8.
- Bhattacharya D, Chhabda S, Lakshmanan R, Tan R, Warne R, Benenati M, et al. Spectrum of neuroimaging findings post-proton beam therapy in a large pediatric cohort. *Childs Nerv Syst*. 2021;37(2):435–46.
- Reichstein DA, Brock AL. Radiation therapy for uveal melanoma: a review of treatment methods available in 2021. *Curr Opin Ophthalmol*. 2021;32(3):183–90.
- SCCA Proton Therapy, Ocular melanoma treatment. Available from: <https://www.sccaprotontherapy.com/cancers-treated/ocular-melanoma-treatment>.
- Van Beek, Ramdas W, Angi M, Van Rij C, Naus N, Kacperek A, et al. Local tumour control and radiation side effects for fractionated stereotactic photon beam radiotherapy compared to proton beam radiotherapy in uveal melanoma. *Radiother Oncol*. 2021;157:219–24.
- Milazzotto R, Liardo R, Privitera G, Raffaele L, Salamone V, Arena F, et al. Proton beam radiotherapy of locally advanced or recurrent conjunctival squamous cell carcinoma: experience of the CATANA Centre. *JRP*. 2020;1–8.
- Guan X, Gao J, Hu J, Hu W, Yang J, Qiu X, et al. The preliminary results of proton and carbon ion therapy for chordoma and chondrosarcoma of the skull base and cervical spine. *Radiat Oncol*. 2019;14(1):206.
- Parzen JS, Li X, Zheng W, Ding X, Kabolizadeh P. Proton Therapy for Skull-Base Chordomas and Chondrosarcomas: Initial Results from the Beaumont Proton Therapy Center. *Cureus*. 2021;13(5):e15278.
- Pennington Z, Ehresman J, Elsamadicy AA, Shin JH, Goodwin CR, Schwab JH, et al. Systematic review of charged-particle therapy for chordomas and sarcomas of the mobile spine and sacrum. *Neurosurg Focus*. 2021;50(5):E17.
- Simone C, Plastaras J, Jabbour S, Lee A, Lee N, Choi I, et al. Proton Reirradiation: Expert Recommendations for Reducing Toxicities and Offering New Chances of Cure in Patients with Challenging Recurrence Malignancies. *Seminars in Rad Oncol*. 2020;30(3):253–61.
- Saeed AM, Khairnar R, Sharma AM, Larson GL, Tsai HK, Wang CJ, et al. Clinical Outcomes in Patients with Recurrent Glioblastoma Treated with Proton Beam Therapy Reirradiation: Analysis of the Multi-Institutional Proton Collaborative Group Registry. *Adv Radiat Oncol*. 2020;5(5):978–83.

Протонска терапија

Марија Поповић-Вуковић¹, Јелена Бокун^{1,2}, Драгана Станић^{1,2}, Борко Ницовић¹, Марина Никитовић^{1,2}

¹Институт за онкологију и радиологију Србије, Београд, Србија

²Универзитет у Београду, Медицински факултет, Београд, Србија

САЖЕТАК

Протонска терапија је напредна радиотерапијска техника која показује супериорнију дозу дистрибуцију и дозиметријску предност у односу на радиотерапију фотонима. Протонска терапија може побољшати преживљавање болесника омогућавањем боље локалне контроле болести уз смањено зрачење околних здравих органа, што резултира нижом стопом терапијских компликација. Током претходне деценије технолошки напредак довео је до нових могућности за планирање и спровођење протонске терапије, те је порасла њена примена у третману различитих тумора.

Међутим, биолошки аспекти протонске терапије још увек нису разјашњени, а клиничка примена је и даље контроверзна. Сматра се да је протонска терапија безбедна и ефикасна у третману различитих педијатријских тумора и да је адекватна у случајевима окуларног меланома, хордома и хондросаркома. Неопходна су даља истраживања и проспективне клиничке студије са дугорочним праћењем болесника како би се јасно утврдиле предности и одговарајуће индикације за примену протонске терапије.

Кључне речи: протонска терапија; радиотерапија; канцер