

## ORIGINAL ARTICLE / ОРИГИНАЛНИ РАД

# Videolaryngostroboscopy in early vocal fold carcinoma diagnosis

Jasmina Stojanović<sup>1,2</sup>, Dragan Milovanović<sup>3</sup>, Slobodanka Mitrović<sup>4</sup>, Andra Jevtović<sup>1,2</sup>, Natalija Božović<sup>1,2</sup>, Marina Jovanović<sup>1,2</sup>, Sunčica Srećković<sup>5</sup>, Branislav Belić<sup>1,2</sup>

<sup>1</sup>University of Kragujevac, Faculty of Medical Sciences, Department of Otorhinolaryngology, Kragujevac, Serbia;

<sup>2</sup>Kragujevac Clinical Center, Clinic of Otorhinolaryngology, Kragujevac, Serbia;

<sup>3</sup>University of Kragujevac, Faculty of Medical Sciences, Department of Pharmacology and Toxicology, Kragujevac, Serbia;

<sup>4</sup>University of Kragujevac, Faculty of Medical Sciences, Department of Pathology, Kragujevac, Serbia;

<sup>5</sup>University of Kragujevac, Faculty of Medical Sciences, Department of Ophthalmology, Kragujevac, Serbia



## SUMMARY

**Introduction/Objective** Vocal folds are the most common primary site of laryngeal carcinoma. Advancement in diagnostic and therapeutic modalities have provided better prognosis for patients with early glottic carcinoma. We aimed to report the role of videolaryngostroboscopy (VLS) in early diagnosis of vocal fold carcinoma.

**Methods** Prospective controlled study included 300 dysphonic patients admitted to the tertiary medical center for microlaryngoscopy with biopsy. All patients underwent stroboscopic examination prior to biopsy. VLS findings were classified according to Hirano into four stages, with an adynamic vocal fold segment and absence of vocal fold vibration, suspected for vocal fold carcinoma at stage IV. Histopathological findings have been graded according to Ljubljana classification into simple hyperplasia, abnormal hyperplasia, atypical hyperplasia, and carcinoma *in situ*.

**Results** Analysis of VLS findings showed that 41.67% of patients ( $n = 125/300$ ) had asymmetrical and irregular vocal fold vibration with a mucosal wave reduction (VLS stage III), while an adynamic vocal fold segment and absence of vocal fold vibration (VLS stage IV), suspected for vocal fold carcinoma, was noticed in 17.33% of patients ( $n = 52/300$ ). Histopathology report showed that vocal fold carcinoma was verified in 5.6% of patients in VLS stage III ( $n = 7/125$ ), while VLS stage IV carcinoma was detected in 26.92% of patients ( $n = 14/52$ ). Adynamic segment or entire nonvibrating vocal fold finding predicts early glottic carcinoma with a sensitivity of 66.77%, specificity of 86.4%, and moderate diagnostic accuracy (AUC = 0.844).

**Conclusion** VLS plays an important role as a timely indicator for microlaryngoscopy with biopsy in diagnosis of vocal fold carcinoma.

**Keywords:** videolaryngoscopy; vocal fold carcinoma; microlaryngoscopy

## INTRODUCTION

Laryngeal cancer accounts for 30–40% of malignant head and neck tumors and for 1–2.5% of all malignancies. Squamous cell carcinoma adds up to 95–98% of laryngeal cancers. The occurrence of laryngeal carcinoma is more common in male patients between the fifth and seventh decade of life. Laryngeal carcinomas are one of several oncological diseases in which the five-year survival rate has decreased from 66% to 63% over the last 40 years, although the total incidence is declining [1, 2, 3]. In Serbia, laryngeal carcinomas are one of the most common malignancies, and, according to 2017 data, they rank sixth in terms of occurrence [4].

The first clinically manifested symptom of vocal fold carcinoma is dysphonia. According to American Academy of Otorhinolaryngology and Head and Neck Surgery guidelines, dysphonia diagnostics includes anamnesis, clinical examination focusing on laryngeal motility and

visible pathological changes of the vocal folds, videolaryngostroboscopy (VLS) and microlaryngoscopy with biopsy as gold diagnostic standard. The occurrence of vocal fold carcinoma is associated with smoking, gastroesophageal reflux disease, HPV virus, with alcohol being less involved in the development of vocal fold cancer than in other localizations of laryngeal tumors. VLS provides insight in anatomical structures and functional changes of the vocal folds (appearance and vibratory patterns), without complications. Though it is invasive procedure, microlaryngoscopy is necessary complementary method to VLS, and without it histological confirmation of the lesion would be impossible [5, 6, 7].

The aim of this study is to distinguish the presence of early glottic carcinoma in patients with or without dysplastic lesions of vocal folds, using certain clinical characteristics observed during VLS.

**Received • Примљено:**  
May 29, 2020

**Revised • Ревизија:**  
June 17, 2021

**Accepted • Прихваћено:**  
September 1, 2021

**Online first:** September 3, 2021

## Correspondence to:

Sunčica SREĆKOVIĆ  
Faculty of Medical Sciences  
University of Kragujevac  
Svetozara Markovića 69  
34000 Kragujevac, Serbia  
[sunce.sun@yahoo.com](mailto:sunce.sun@yahoo.com)

## METHODS

This prospective study with 300 dysphonic patients was conducted over a four-year period in the Clinic of Otorhinolaryngology, Kragujevac Clinical Center, Serbia. Ethics Committee of the Kragujevac Clinical Center approved the study. Patients with functional voice disorders, benign tumors, pseudotumors, as well as patients with verified vocal fold carcinoma were excluded from the study. All the patients underwent detailed anamnesis, otorhinolaryngological and phoniatic examination, VLS, and microlaryngoscopy with biopsy. All the subjects gave their informed consent for participation in the study and ethics guidelines of the Declaration of Helsinki were followed during the study.

VLS was performed using a rigid Karl Storz stroboscope (Karl Storz SE & Co. KG, Tuttlingen, Germany). One doctor performed and evaluated all stroboscopic examinations. Following parameters were analyzed: glottic occlusion, amplitude and regularity of vocal fold vibration and presence of mucosal wave. VLS findings were classified according to Hirano into the following four stages: 1. Insufficient glottic occlusion with symmetrical, regular vocal fold vibration with regular amplitude and presence of mucosal wave; 2. Insufficient glottic occlusion with symmetrical and regular vocal fold vibration with a reduced amplitude, and slightly reduced mucosal wave; 3. Insufficient glottic occlusion with asymmetrical and irregular vocal fold vibration with a mucosal wave reduction; 4. Adynamic vocal fold segment and absence of vocal fold vibration, suspected for vocal fold carcinoma [5, 8].

Microlaryngoscopy with biopsy was performed in general anesthesia with SOM 62 microscope (Karl Kaps GmbH & Co. KG, Asslar, Germany) and Karl Storz laryngoscope (Karl Storz SE & Co. KG). All sections of the obtained samples had been embedded in paraffin wax, cut at 3–5 mm thickness from at least two parts of the paraffin block and stained with hematoxylin and eosin for histopathological (HP) analysis. HP findings have been graded according to Ljubljana classification into simple hyperplasia (benign spinous layer augmentation), abnormal hyperplasia (benign basal and parabasal layer augmentation), atypical hyperplasia (risky for malignancy) and carcinoma *in situ*. [9, 10].

The data were analyzed using statistical package IBM SPSS Statistics, Version 21.0 (IBM Corp., Armonk, NY, USA). The normality of distribution was tested by the Kolmogorov–Smirnov test. The statistical association was evaluated using the  $\chi^2$  test. Receiver operating characteristic (ROC) curve is used for the assessment of VLS diagnostic values. Diagnostic value is tested using clinical variables of interest by the method of logistic regression. Diagnostic value of VLS was evaluated through determination of sensitivity, specificity, and diagnostic accuracy. The results were considered significantly different when  $p < 0.05$ .

## RESULTS

Our study included 220 male (73.33%) and 80 female patients (26.67%), with an average age of 50.59 years. The smokers accounted for 88.67% ( $n = 266/300$ ) of patients, with a  $23.970 \pm 12.651$  mean smoking years history, while 11.33% ( $n = 34/300$ ) of patients were non-smokers.

Analysis of VLS findings according to the Hirano classification showed that all patients had insufficient glottic occlusion. In 27.33% of patients ( $n = 82/300$ ) we noticed symmetrical, regular vocal fold vibration with regular amplitude and presence of mucosal wave (VLS stage I), 13.67% of patients ( $n = 41/300$ ) had symmetrical and regular vocal fold vibrations with a reduced amplitude, and slightly reduced mucosal wave (VLS stage II), while 41.67% of patients ( $n = 125/300$ ) had asymmetrical and irregular vocal fold vibrations with a mucosal wave reduction (VLS stage III). Adynamic vocal fold segment and the absence of vocal fold vibration (VLS stage IV), suspected for vocal fold carcinoma, was noticed in 17.33% of the patients ( $n = 52/300$ ) (Table 1).

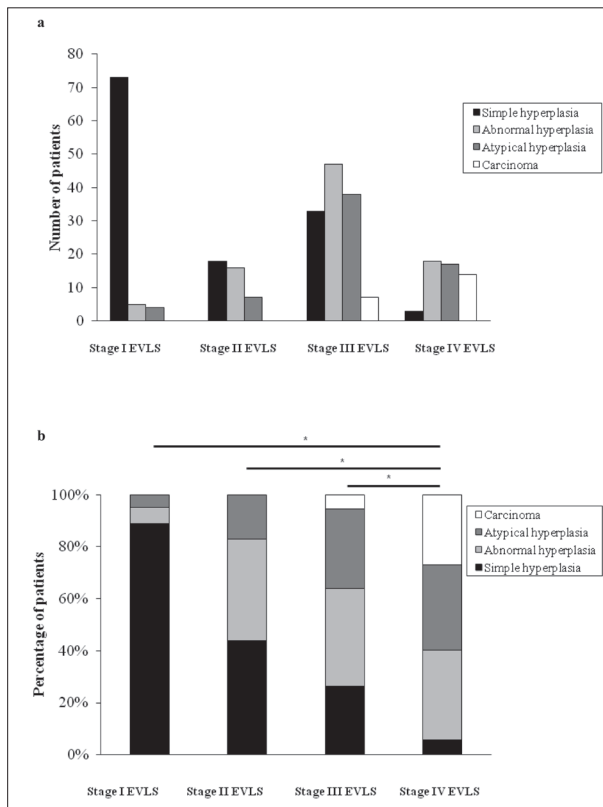
**Table 1.** Number of patients with specific epithelial hyperplastic laryngeal lesions distributed by videolaryngostroboscopy (VLS) stages

Epithelial hyperplastic laryngeal lesions	VLS stages				Total
	Stage I	Stage II	Stage III	Stage IV	
Simple hyperplasia	73	17	33	3	<b>126 (42%)</b>
Abnormal hyperplasia	5	17	46	18	<b>86 (28.67%)</b>
Atypical hyperplasia	4	7	39	17	<b>67 (22.33%)</b>
Carcinoma	0	0	7	14	<b>21 (7%)</b>
Total (%)	82 (27.33)	41 (13.67)	125 (41.67)	52 (17.33)	300

All the patients underwent microlaryngoscopy with vocal fold biopsy. HP report showed that simple hyperplasia was present in 42% of the patients ( $n = 126/300$ ), abnormal hyperplasia in 28.67% of the patients ( $n = 86/300$ ), 22.33% of the patients ( $n = 67/300$ ) had atypical hyperplasia, while 7% of the patients ( $n = 21/300$ ) were diagnosed with laryngeal carcinoma (Table 1).

In VLS stage I, most common HP finding was simple hyperplasia. Carcinoma was not detected in VLS stages I and II. In VLS stage III carcinoma was verified in 5.6% of the patients ( $n = 7/125$ ), while VLS stage IV carcinoma was detected in 26.92% of patients ( $n = 14/52$ ) (Figure 1a, b). HP reports indicating carcinoma showed that 52.38% of the patients ( $n = 11/21$ ) had carcinoma *in situ*, while 47.62% of the patients ( $n = 10/21$ ) had invasive laryngeal carcinoma. Our results showed that there were significantly more patients with carcinoma in VLS stage IV than in other VLS stages (Figure 1b).

To examine diagnostic significance of VLS in carcinoma diagnostics we used ROC curve for determining the procedure sensitivity and specificity, univariate and bivariate logistic regression. Adynamic segment finding had 0.667 sensitivity and 0.864 specificity in detecting vocal fold carcinoma [area under the curve (AUC) = 0.844, 95% confidence interval (CI) 0.772–0.916]. Odds ratio for



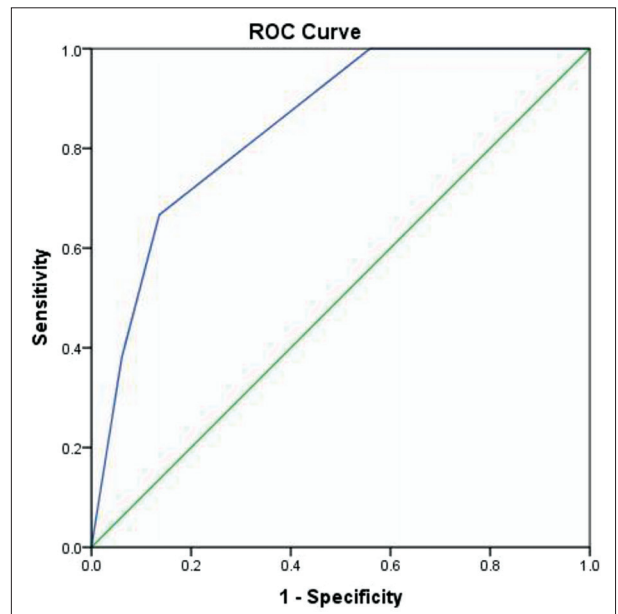
**Figure 1.** Distribution of epithelial laryngeal lesions according to endovideolaryngostroboscopy (EVLS) findings

VLS findings of 3.44 (95% CI 2.14–5.51) indicates that for each gradation of findings, from VLS stage I to stage IV, the chance for carcinoma detection after biopsy is increased. Our results imply a cut-off point for early diagnostics of glottic carcinoma with a sensitivity of 66.77%, specificity of 86.4%, and moderate diagnostic accuracy (AUC = 0.844) for early detection of glottic carcinoma. According to our results, VLS predicts most precisely early glottic carcinoma when adynamic segment or when entire nonvibrating vocal fold is found (Figure 2).

**DISCUSSION**

There is a great interest in the assessment of the VLS role in diagnosis of vocal fold carcinoma and benign pathology [9, 10]. VLS is considered to be an objective method with a subjective interpretation of the experienced endoscopists [5, 11]. In our study, VLS was used as a diagnostic procedure, while biopsy with HP evaluation as a gold diagnostic standard was a comparative method used to confirm stroboscopic prediction.

Analyzing the VLS and HP reports on 112 subjects, Jotic et al. [5] found that the adynamic segment was present in 15.1% of patients with mild, 38.5% of patients with moderate, and in 54.5% of patients with severe dysplasia (carcinoma *in situ*). In a prospective clinical trial of 66 patients, VLS findings were compared with histopathological verification of glottic carcinoma. Asymmetrical and irregular vocal fold vibrations with absent mucosal



**Figure 2.** The area under receiver operating characteristic (ROC) curve for the sensitivity and specificity of videolaryngostroboscopy in vocal fold carcinoma diagnosis

wave or absent vibrations of one part or the entire vocal fold were histopathologically confirmed as cancer in 85% of the patients. There were seven HP reports positive for carcinoma (87.5%) and one negative (12.5%) in the group of patients with absent mucosal wave. In the group of patients with absent vocal fold vibrations, there were 49 positive (84.48%) and nine negative (15.52%) HP reports. The authors concluded that in the cases of hoarseness present more than 14 days, VLS is the method of choice in assessing the need for microlaryngoscopy and HP verification [12]. El-Demerdash et al. [13] found that the sensitivity and specificity of VLS in predicting the invasive nature of vocal fold lesions based on the absence or reduction of the mucosal wave was 96.8% and 92.8%, respectively. Caffier et al. [14] found absence of vocal fold vibrations and adynamic segment (VLS stage IV) in 17/34 patients, while in 16 patients, malignancy was histopathologically confirmed. In addition, Gugatschka et al. [15] showed that the combination of exfoliative cytology and VLS allows for the detection of glottic cancer with a sensitivity of 97%. In compliance with the available data, our results showed that 26.92% of the patients (14/52) with adynamic segment and absent vocal fold vibration had histopathologically confirmed vocal fold carcinoma. In addition, in 66.67% of the patients (14/21) with vocal fold carcinoma adynamic segment and absent vocal fold vibration were detected (Figure 1). Adynamic segment or absent vocal fold vibrations predict early glottic carcinoma with a sensitivity of 66.77%, specificity of 86.4%, and moderate diagnostic accuracy, AUC = 0.844 (Figure 2).

Gamboa et al. [16] used the WHO histopathology classification, which is compatible with the Ljubljana classification that we used in our study. Absent mucosal wave as a suspected VLS finding was observed in 15 patients. Severe dysplasia was histopathologically confirmed in 13.4% of

the patients ( $n = 2/15$ ), and planocellular carcinoma in 46.7% ( $n = 7/15$ ). Histopathology did not show cell atypia in 26.7% of the patients ( $n = 4/15$ ), while remaining 13.4% ( $n = 2/15$ ) showed mild dysplasia.

VLS findings that are characteristic of chronic laryngitis (asymmetrical vocal fold vibrations with reduced amplitudes and mucosal wave reduction) demand particular attention because continuous VLS monitoring of these patients allows early diagnosis of vocal fold carcinoma [7, 11, 13, 15, 17].

The recognition of clinical manifestations and exposure to risk factors for the vocal fold carcinoma is important to primary care in order to promptly refer the patient to otorhinolaryngological examination and to establish a timely indication for microlaryngoscopy with biopsy [18–21]. VLS is a very important prompt indicator for microlaryngoscopy with biopsy as a gold standard procedure for the diagnosis of vocal fold carcinoma. During microlaryngoscopy, the

patient must be under general anesthesia, which makes examination of the larynx mobility impossible [22, 23]. Also, vocal fold scarring after the biopsy is possible as the tissue does not have the ability to regenerate. According to the American Academy of Otorhinolaryngology and Head and Neck Surgery guidelines for dysphonia diagnostics, VLS enables good visualization of the larynx, which is important before performing microlaryngoscopy [24, 25, 26].

## CONCLUSION

Results of this study implicate fundamental significance of VLS in the diagnosis of early glottic carcinoma as VLS precisely predicts early glottic carcinoma when an adynamic segment or the entire nonvibrating vocal fold is found.

**Conflict of interest:** None declared.

## REFERENCES

- Steuer CE, El-Deiry M, Parks JR, Higgins KA, Saba NF. An update on larynx cancer. *CA Cancer J Clin.* 2017;67(1):31–50.
- Obid R, Redlich M, Tomeh C. The Treatment of Laryngeal Cancer. *Oral Maxillofac Surg Clin North Am.* 2019;31(1):1–11.
- Li H, Li EY, Kejner AE. Treatment modality and outcomes in larynx cancer patients: A sex-based evaluation. *Head & Neck.* 2019;41(11):3764–74.
- Institut za javno zdravlje Srbije "Dr Milan Jovanovic Batut". *Zdravstveno-statistički godišnjak Republike Srbije 2017*, Belgrade, Serbia.
- Jotic A, Stankovic P, Jesic S, Milovanovic J, Stojanovic M, Djukic V. Voice quality after treatment of early glottic carcinoma. *J Voice.* 2012;26(3):381–9.
- Young WG, Shama L, Petty B, Hoffman MR, Dailey SH. Comparing Videostroboscopy and Direct Microlaryngoscopy: An Argument for Flexible Consent and Operative Plan. *J Voice.* 2019;33(2):143–9.
- Hamdan AL, Ghanem A, Natout TE, Khalifee E. Diagnostic Yield of Office-Based Laryngeal Biopsy in Patients with Leukoplakia; A Case Study with Review of the Literature. *J Voice.* 2021;50892-1997(20)30446-X.
- Milutinovic Z. *Klinički atlas poremećaja glasa*. Belgrade, Serbia: Zavod za udžbenike i nastavna sredstva; 1997. p. 195.
- Gale N, Kambic V, Michaels L, Cardesa A, Hellquist H, Zidar N, et al. The Ljubljana classification: a practical strategy for the diagnosis of laryngeal precancerous lesions. *Adv Anat Pathol.* 2000;7(4):240–51.
- Odell E, Eckel HE, Simo R, Quer M, Paleri V, Klusmann JP, et al. European Laryngological Society position paper on laryngeal dysplasia Part I: aetiology and pathological classification. *Eur Arch Otorhinolaryngol.* 2021;278(6):1717–22.
- van Balkum M, Buijs B, Donselaar EJ, Erkelens DC, Goulin Lippi Fernandes E, Wegner I, et al. Systematic review of the diagnostic value of laryngeal stroboscopy in excluding early glottic carcinoma. *Clin Otolaryngol.* 2017;42(1):123–30.
- Chao S, Song SA. *Videostroboscopy*. 2021 Jan 7. In: *StatPearls [Internet]*. Treasure Island (FL): StatPearls Publishing; 2021 Jan–.
- El-Demerdash A, Fawaz SA, Sabri SM, Sweed A, Rabie H. Sensitivity and specificity of stroboscopy in preoperative differentiation of dysplasia from early invasive glottic carcinoma. *Eur Arch Otorhinolaryngol.* 2015;272(5):1189–93.
- Caffier P, Schmidt B, Gross M, Karnetzky K, Nawka T, Rotter A, et al. A comparison of white light laryngostroboscopy versus autofluorescence endoscopy in the evaluation of vocal fold pathology. *Laryngoscope.* 2013;123(7):1729–34.
- Gugatschka M, Kiesler K, Beham A, Rechenmacher J, Friedrich G. Hyperplastic epithelial lesions of the vocal folds: combined use of exfoliative cytology and laryngostroboscopy in differential diagnosis. *Eur Arch Otorhinolaryngol.* 2008;265(7):797–801.
- Gamboa J, Echeverría L, Molina B, Cobeta I. [Stroboscopic assessment of chronic laryngitis]. *Acta Otorinolaringol Esp.* 2006;57(6):266–9. [Article in Spanish]
- Rzepakowska A, Sielska-Badurek E, Osuch-Wójcikiewicz E, Sobol M, Niemczyk K. The predictive value of videostroboscopy in the assessment of premalignant lesions and early glottic cancers. *Otolaryngol Pol.* 2017;71(4):14–8.
- Powell ME, Deliyski DD, Zeitels SM, Burns JA, Hillman RE, Gerlach TT, et al. Efficacy of Videostroboscopy and High-Speed Videoendoscopy to Obtain Functional Outcomes from Perioperative Ratings in Patients with Vocal Fold Mass Lesions. *J Voice.* 2020;34(5):769–82.
- Kiessling P, Bayan S, Lohse C, Orbelo D. Predicting Gag, Discomfort, and Laryngeal Visualization in Patients Undergoing Flexible Laryngoscopy with Stroboscopy. *Ann Otol Rhinol Laryngol.* 2021;34894211011453. [Online ahead of print] doi: 10.1177/00034894211011453
- Chatelet F, Wagner I, Bizard A, Hans S, Chabolle F, Bach CA. Does advanced age affect treatment of early glottic carcinoma? *Eur Ann Otorhinolaryngol Head Neck Dis.* 2021;138(2):68–72.
- Vukasinovic M, Djukic V, Stankovic P, Krejovic-Trivic S, Milovanovic J, Mikic A, et al. Nonvibrating segment predicting glottis carcinoma. *Acta Chir Iugosl.* 2009;56(3):61–4.
- De Seta D, Campo F, D'Aguzzo V, Ralli M, Greco A, Russo FY, et al. Transoral laser microsurgery for Tis, T1, and T2 glottic carcinoma: 5-year follow-up. *Lasers Med Sci.* 2021;36(3):507–12.
- Mumović GM. *Konzervativni tretman disfonija*. Novi Sad, Serbia: Medicinski fakultet; 2004. p. 284.
- Cohen SM, Lee HJ, Roy N, Misono S. Chronicity of Voice-Related Health Care Utilization in the General Medicine Community. *Otolaryngol Head Neck Surg.* 2017;156(4):693–701.
- Stachler RJ, Francis DO, Schwartz SR, Damask CC, Digoy GP, Krouse HJ, et al. *Clinical Practice Guideline: Hoarseness (Dysphonia) (Update)*. *Otolaryngol Head Neck Surg.* 2018;158(1\_suppl):S1–S42.
- Mehel DM, Özgür A, Şahin N, Vural AA, Yemiş T, Çelebi M, et al. Voice Quality After Radiotherapy and Cordectomy in Early-Stage Glottic Carcinomas. *Ear Nose Throat J.* 2021;100(4):NP173–NP176.

## Ендовидеостробоскопија у раној дијагностици карцинома гласница

Јасмина Стојановић<sup>1,2</sup>, Драган Миловановић<sup>3</sup>, Слободанка Митровић<sup>4</sup>, Андра Јевтовић<sup>1,2</sup>, Наталија Божовић<sup>1,2</sup>, Марина Јовановић<sup>1,2</sup>, Сунчица Срећковић<sup>5</sup>, Бранислав Белић<sup>1,2</sup>

<sup>1</sup>Универзитет у Крагујевцу, Факултет медицинских наука, Катедра за оториноларингологију, Крагујевац, Србија;

<sup>2</sup>Клинички центар Крагујевац, Клиника за оториноларингологију, Крагујевац, Србија;

<sup>3</sup>Универзитет у Крагујевцу, Факултет медицинских наука, Катедра за фармакологију и токсикологију, Крагујевац, Србија;

<sup>4</sup>Универзитет у Крагујевцу, Факултет медицинских наука, Катедра за патолошку анатомију, Крагујевац, Србија;

<sup>5</sup>Универзитет у Крагујевцу, Факултет медицинских наука, Катедра за офталмологију, Крагујевац, Србија

### САЖЕТАК

**Увод/Циљ** Гласнице представљају најчешћу примарну локализацију ларингеалног карцинома. Напредак у дијагностици и терапији омогућио је бољу прогнозу за болеснике са раним карциномом глотиса.

Основни циљ нашег истраживања је да укажемо на значај ендовидеостробоскопије у раној дијагностици карцинома гласница.

**Методе** У проспективну контролисану студију укључено је 300 болесника са дисфонијом, хоспитализованих у терцијарној медицинској установи ради микроларингоскопије са биопсијом. Код свих болесника учињен је ендовидеостробоскопски преглед пре биопсије. Анализа ендовидеостробоскопског налаза је класификована према Хирану у четири стадијума, тако да адинамични сегмент и одсутне вибрације гласнице представљају стробоскопски налаз IV, суспектан за карцином гласнице. Према Љубљанској класификацији, хистопатолошки налаз подељен је на једноставну, абнормалну и атипичну хиперплазију и карцином *in situ*.

**Резултати** Анализа ендовидеостробоскопског налаза показала је да код 41,67% болесника ( $n = 125/300$ ) постоје обострано присутне асиметричне и ирегуларне вибрације гласница, јако редукованог мукозног таласа (стробоскопски налаз III), док су код 17,33% ( $n = 52/300$ ) болесника уочени адинамични сегмент и одсутне вибрације гласнице (стробоскопски налаз IV), суспектни на карцином гласнице. Хистопатолошким анализом, карцином гласница је верификован код 5,6% болесника са стробоскопским налазом III ( $n = 7/125$ ) и код 26,92% болесника са стробоскопским налазом IV ( $n = 14/52$ ). Налаз адинамичног сегмента и одсутних вибрација гласница има сензитивност 66,77% и специфичност 86,4% у детекцији карцинома гласница, са умереном дијагностичком прецизношћу ( $AUC = 0,844$ ).

**Закључак** Ендовидеостробоскопија игра важну улогу у правојременој индикацији за микроларингостробоскопију са биопсијом у дијагностици карцинома гласница.

**Кључне речи:** ендовидеостробоскопија; карцином гласница; микроларингостробоскопија