



CASE REPORT / ПРИКАЗ БОЛЕСНИКА

Deciding on thrombolytic therapy in pulmonary embolism – is there room for lactate

Duřanka Obradović^{1,2}, Biljana Joveř^{1,2}, Svetislava Milić¹, Jovan Matijašević^{1,2}, Stanislava Sovilj-Gmizić¹

¹Institute for Pulmonary Diseases of Vojvodina, Sremska Kamenica, Serbia;

²University of Novi Sad, Faculty of Medicine, Novi Sad, Serbia

SUMMARY

Introduction Diagnostic and therapeutic algorithms for pulmonary embolism (PE) have been frequently modified; however, determining clinical probability, which dictates further procedures, has remained the first step.

The objective was to illustrate therapeutic dilemma in a patient with intermediate high risk for 30-day mortality.

Case outline The patient was a 56-years-old woman who was referred to our institution for suspected PE. According to the Wells score, the patient was deemed as low-probability for venous thromboembolism, and after further stratification she was placed in a group with intermediate high risk for 30-day mortality. PE was confirmed by computerised tomography pulmonary angiography and she initially received heparin. During the further clinical course, she developed hemodynamic instability, and she received thrombolytic therapy, with a positive outcome. The patient also had increased lactate at admission – marker of tissue hypoperfusion which is not a part of the routine laboratory work-up in PE patients.

Conclusion Current guidelines state that patients with intermediate high risk for 30-day mortality should be treated with heparin, and then continuously monitored in order to timely recognize potential hemodynamic instability and consequently apply thrombolytics. In the outlined case, thrombolytic therapy was applied only after the patient developed hemodynamic instability, although previously she had early signs of tissue hypoperfusion.

Keywords: pulmonary embolism; thrombolytic therapy; lactate

INTRODUCTION

Pulmonary embolism (PE) is a condition with many non-specific symptoms, which is the reason why even today PE is largely underdiagnosed and the correct diagnosis is unfortunately often made post mortem [1]. Incidence of PE is high – among cardiovascular diseases, it is in the third place, right after myocardial infarction and cerebrovascular insult [2]. Even with all the current guidelines for prevention, diagnostics, and therapy, PE is a very common cause of death not only in outpatients, but also in hospitalized patients [3, 4]. The current guidelines state that determining clinical

probability of PE is a *conditio sine qua non* in a diagnostic algorithm [3, 4]. Further diagnostic steps depend on the determined level of clinical probability for PE. Further stratification of patients is used to define early mortality risk within 30 days of diagnosing PE. Criteria used for this stratification include hemodynamic stability, Pulmonary Embolism Severity Index (PESI) (Table 1), signs of right ventricular dysfunction and elevated cardiac biomarkers (troponin T or I, NT proBNP – brain natriuretic peptide) (Table 2) [4, 5]. The main criterion when it comes to the choice between anticoagulant therapy versus thrombolytic therapy is the presence of shock, that is hemodynamic

Received • Примљено:
January 26, 2017

Revised • Ревизија:
July 27, 2017

Accepted • Прихваћено:
July 28, 2017

Online first: August 8, 2017

Correspondence to:

Duřanka OBRADOVIĆ
Put doktora Goldmana 4
21204 Sremska Kamenica
Serbia

dusanka.obradovic@mt.uns.ac.rs

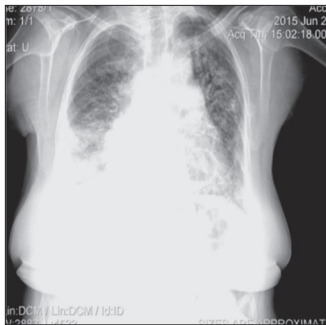
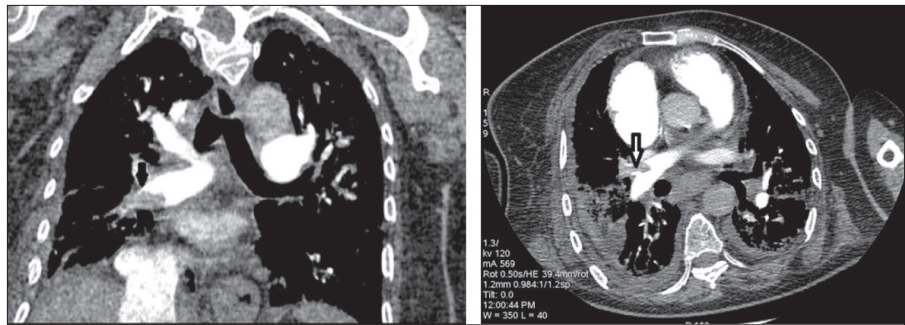
Table 1. Prognostic index for patients with pulmonary embolism based on clinical presentation severity (Pulmonary Embolism Severity Index – PESI) [5]

PESI index		Simplified PESI	Our patient
Age		1 (if older than 80)	
Sex	10		
Carcinoma	30	1	
Chronic heart failure	10		
Chronic lung disease	10	1	1
Heart frequency	20	1	
Systolic blood pressure < 100 mmHg	30	1	
Respiratory rate	20		
Temperature < 36°C	20		
Change of mental status	60		
SaO ₂ < 90%	20	1	
Risk stratification	Class I–IV	≥ 1 points = 10.9% risk for early mortality	+

Table 2. Stratification of patients with pulmonary embolism according to the risk for early mortality [4]

Risk for early mortality		Risk factors and scoring systems			
		Shock or hypotension	PESI class III–IV or sPESI ≥ 1	RV dysfunction confirmed by imaging methods	Cardiac biomarkers (proBNP and troponin)
High		+	+	+	+
Intermediate	High	-	+	Both positive	
	Low	-	+	Either one (or none) positive	
Low		-	-	Both negative or n/a	
Our patient – intermediate high		-	+	Both positive	

PESI – Pulmonary Embolism Severity Index; sPESI – simplified PESI; proBNP – brain natriuretic peptide; RV – right ventricular

**Figure 1.** Chest X-ray upon admission**Figures 2a and 2b.** Computerised tomographic pulmonary angiography findings: filling defects in the distal part of the right pulmonary artery, as well as in the middle lobe branch

instability [4] This decision is often a big challenge in everyday clinical practice, and that is why we chose this particular case to illustrate clinical dilemmas in a difficult decision whether to apply thrombolytic therapy.

CASE REPORT

The patient was a 56-year-old female who was referred to the Institute of Pulmonary Diseases of Vojvodina for suspected PE. Her symptoms included pain in her right shoulder and pain she localised in the right hypochondrium, along with the loss of appetite, followed by weight loss of more than 10 kg during the previous month. The patient's previous medical history showed that she had been diagnosed with bronchiectasis five years earlier, which was the cause of several previous hospitalizations at the Institute. At admission, the patient was afebrile, eupneic, normocardic, normotensive, and late inspiratory crackles were audible over both lung bases. Electrocardiogram showed incomplete right bundle branch block, sinus rhythm at 80 beats per minute. Blood gas analysis showed severe type I respiratory insufficiency with the signs of hyperventilation (PaO_2 5.76 kPa, PaCO_2 4.12 kPa, pH 7.4, SaO_2 78.5%). Chest X-ray (Figure 1) showed bilateral patchy infiltrates in lower lung fields, blunted right FC sinus, and enlarged cardiac silhouette. According to the Wells scoring system (Table 3), the patient was classified as low clinical probability for PE (Wells 0) [6]. American Chest Physicians Association recommends that patients with low clinical probability for PE should be tested for the Pulmonary Embolism Rule-out Criteria (PERC) (Table 4) [3, 7]. Since our patient did not meet the PERC criteria (older than 50 and SpO_2 lower than 95%), the cited guidelines recommend

testing for D dimer, which was in this case extremely elevated (7,000 ng/ml). The next and final diagnostic step was computerized tomographic pulmonary angiography (CTPA), which confirmed PE in our patient: there were filling defects in the distal part of the right pulmonary artery as well as in the middle lobe branch and eight segment branch, along with suspected thrombi in peripheral branches for the left lower lobe, and bilateral bronchiectasis (Figures 2a and 2b). Quanadli index of pulmonary obstruction was 19.5% [8]. Laboratory findings included increased white blood cell count ($15 \times 10^9/l$), C-reactive protein was moderately increased with normal procalcitonin level and elevated serum lactate (2.46 mmol/l). NT pro BNP was also significantly elevated – 15,000 ng/ml. Echocardiography verified signs of chronic pulmonary hypertension with suspected acutization: enlarged right atrium and ventricle, with the ratio of end-diastolic diameter of the right ventricle to the left ventricle of > 0.9 , free right ventricular wall was hypokinetic, with decreased tricuspid annular plane systolic excursion of 8 mm, which is an indicator of global right ventricular dysfunction. There was a moderate degree of pulmonary hypertension (RVSP-RV systolic pressure of 65 mmHg), mainly explained by presence of chronic pulmonary comorbidities (bronchiectasis and chronic respiratory insufficiency). Pulmonary artery acceleration time was 70 milliseconds. The inferior vena cava was dilated and barely collapsible during the inspiration. Ejection fraction of the left ventricle was preserved (60%).

Prognosis wise, and calculated according to the simplified PESI index (Simplified Pulmonary Embolism Severity Index – sPESI) (Table 3), the patient had a 10.9% risk for early mortality [9]. Furthermore, since her sPESI index was ≥ 1 and due to the fact that she also had echocardiographic

Table 3. Wells scoring system for determining clinical probability of pulmonary embolism [6]

Criteria	Points	Our patient
<i>Predisposing factors</i>		
Previous venous thromboembolism	+1.5	0
Recent surgery or immobilization	+1.5	0
Malignancy	+1.0	0
<i>Symptoms</i>		
Hemoptysis	+1	0
<i>Clinical signs</i>		
Tachycardia (over 100 bpm)	+1.5	0
Clinical signs of deep venous thrombosis	+3	0
<i>Clinical evaluation</i>		
Alternative diagnosis less likely	+3	0
<i>Clinical probability</i>		
Low	0–1	0
Intermediate	2–6	
High	> 6	
<i>Modified Wells scoring system</i>		
Low clinical probability of pulmonary embolism	≤ 4	≤ 4
High clinical probability of pulmonary embolism	> 4	

Table 4. Pulmonary embolism rule-out criteria for patients with low pre-test probability

Clinical characteristics	Meets the criterion	Does not meet the criterion
Age < 50 years	0	1
Initial heart rate < 100 bpm	0	1
Initial SaO ₂ < 94% at room air	0	1
No unilateral leg swelling	0	1
No hemoptysis	0	1
No surgery or trauma within 4 weeks	0	1
No history of venous thromboembolism	0	1
No estrogen use	0	1

signs of right ventricular dysfunction along with positive cardiac biomarkers, this patient was classified as high intermediate risk for early mortality, in line with the European Society of Cardiology guidelines [4]. Therapy recommendations for these patients imply anticoagulant therapy, with continuous monitoring of their vital parameters. Thrombolytic therapy within this group is recommended only if hemodynamic instability ensues.

Our patient was diagnosed and treated in accordance with all the cited guidelines – she was admitted to the High Dependency Unit, where she was continuously non-invasively monitored and received parenteral heparin therapy. However, six hours upon admission, she developed hemodynamic instability and was immediately transferred to the Intensive Care Unit (ICU). Her initial APACHE II score was 20 (PDR 35.5, adjusted 32.6). She then received thrombolytic therapy (streptokinase) according to the rapid protocol. After 72 hours, there was a recurrent PE, and the intensivists repeated thrombolytic therapy. During the further clinical course, she had to be intubated, and due to the necessity for prolonged ventilatory support, percutaneous tracheostomy was performed. After five days in the ICU, she was stabilized and afterwards transferred to the general ward. Oral anticoagulant therapy was titrated and she was discharged from hospital on day 30.

DISCUSSION

Some conclusions can be drawn from this report; yet, several everyday clinical dilemmas illustrated by this clinical scenario remain.

Firstly, the patient was categorized as having low clinical probability for PE (Wells 0). However, since she met two PERC criteria, PE could not be ruled out without D-dimer. The patient's D-dimer was extremely elevated, which preconditioned the final diagnostic step – CTPA. Also, echocardiographic findings were interpreted as chronic pulmonary hypertension with suspected signs of acutization. Since the patient had a pre-existing lung disease (bronchiectasis, respiratory insufficiency), which probably led to chronic pulmonary hypertension, this was an additional diagnostic dilemma.

Another moot point is appropriate therapy in patients with confirmed PE, who are categorized as having intermediate high risk of early mortality, such as our patient. Many patients in this group do well on anticoagulant therapy only; however, there are a few cases where hemodynamic instability develops during parenteral anticoagulant therapy, which then necessitates thrombolytics. This is the reason the patients in this subgroup must be carefully monitored in order to timely recognize clinical deterioration. Research in this field has not been conclusive thus far – further studies are needed to confirm true predictors of early mortality, which would be included in a satisfactory prognostic model [10, 11, 12]. Current research results show that patients with PE who initially had increased lactate levels had significantly higher mortality (17.3% vs. 1.6%) [11]. Bova et al. [12] conducted research on patients with intermediate high mortality risk and showed that the combination of cardiac biomarkers, echocardiographic signs of right ventricular dysfunction, tachycardia, and hypotension increased the risk of complications during the initial 30 days as much as seven-fold. The Thromboembolism Lactate Outcome Study (TELOS) in normotensive patients with PE revealed that this group of patients, if they had right ventricular dysfunction, elevated troponin and elevated plasma lactate are considered intermediate–high risk, and this patient had significantly more PE-related complications. Recent studies which compared the European Society of Cardiology, Bova and TELOS models for more accurately identifying patients with PE and intermediate high risk concluded that adding plasma lactate to the Bova score was a significantly powerful model [13, 14].

In conclusion, although our patient was initially stable on anticoagulant therapy, there were two episodes of hemodynamic instability during the first 72 hours, which significantly increased her mortality risk. Our dilemma remains: since she had increased lactate levels at the very beginning, indicating poor perfusion despite normal blood pressure, should we have administered thrombolytic therapy earlier? American College of Chest Physicians suggests that broader criteria for true hemodynamic instability should be considered in these patients, including hypotension, tachycardia, distended jugular veins, clinical signs of poor tissue perfusion, and hypoxemia, but further studies are warranted [15].

REFERENCES

- Karwinski B, Svendsen E. Comparison of clinical and postmortem diagnosis of pulmonary embolism. *J Clin Pathol.* 1989; 42(2):135–9.
- Goldhaber SZ, Bounameaux H. Pulmonary embolism and deep vein thrombosis. *The Lancet* 2012; 379(9828):1835–46.
- Raja AS, Greenberg JO, Qaseem A, Denberg TD, Fitterman N, Schuur JD. Evaluation of patients with suspected acute pulmonary embolism: best practice advice from the Clinical Guidelines Committee of the American College of Physicians. *Ann Intern Med.* 2015; 163(9):701–11.
- Konstantinides SV, Torbicki A, Agnelli G, Danchin N, Fitzmaurice D, Galiè N, et al. 2014 ESC guidelines on the diagnosis and management of acute pulmonary embolism. *Eur Heart J.* 2014; 35(43):3033–69.
- Aujesky D, Obrosky DS, Stone RA, Auble TE, Perrier A, Cornuz J, et al. Derivation and validation of a prognostic model for pulmonary embolism. *Am J Respir Crit Care Med.* 2005; 172(8):1041–6.
- Wells PS, Ginsberg JS, Anderson DR. Use of a clinical model for safe management of patients with suspected pulmonary embolism. *Ann Intern Med.* 1998; 129(12):997–1005.
- Kline JA, Webb WB, Jones AE, Hernandez-Nino J. Impact of a rapid rule-out protocol for pulmonary embolism on the rate of screening, missed cases, and pulmonary vascular imaging in an urban US emergency department. *Ann Emerg Med.* 2004; 44(5):490–502.
- Qanadli SD, El Hajjam M, Vieillard-Baron A. New CT index to quantify arterial obstruction in pulmonary embolism: a comparison with angiographic index and echocardiography. *AJR Am J Roentgenol.* 2001; 176(6):1415–20.
- Jimenez D, Aujesky D, Moores L, Gomez V, Lobo JL, Uresandi F, et al. Simplification of the pulmonary embolism severity index for prognostication in patients with acute symptomatic pulmonary embolism. *Arch Intern Med.* 2010; 170(15):1383–9.
- Jiménez D, Aujesky D, Moores L. Combinations of prognostic tools for identification of high-risk normotensive patients with acute symptomatic pulmonary embolism. *Thorax.* 2011; 66(1):75–81.
- Vanni S, Viviani G, Baioni M, Pepe G, Nazerian P, Soccì F, et al. Prognostic value of plasma lactate levels among patients with acute pulmonary embolism: the thromboembolism lactate outcome study. *Ann Emerg Med.* 2013; 61(3):330–8.
- Bova C, Sanchez O, Prandoni P. Identification of intermediate-risk patients with acute symptomatic pulmonary embolism. *Eur Respir J.* 2014; 44(3):694–703.
- Vanni S, Jimenez D, Nazerian P, Morello F, Parisi M, Daghini E, et al. Short-term clinical outcome of normotensive patients with acute PE and high plasma lactate. *Thorax.* 2015; 70(4):333–8.
- Vanni S, Nazerian P, Bova C, Bondi E, Morello F, Pepe G, et al. Comparison of clinical scores for identification of patients with pulmonary embolism at intermediate-high risk of adverse clinical outcome: the prognostic role of plasma lactate. *Intern Emerg Med.* 2017; 12(5):657–65.
- Kearon C, Akl EA, Comerota AJ. Antithrombotic therapy for VTE disease: antithrombotic therapy and prevention of thrombosis, 9th ed: American College of Chest Physicians evidence-based clinical practice guidelines. *Chest.* 2012; 141(Suppl):e419S–e94S.

Одлука о тромболитичкој терапији код плућне емболије – да ли има простора за лактат

Душанка Обрадовић^{1,2}, Биљана Јовеш^{1,2}, Светислава Милић¹, Јован Матијашевић^{1,2}, Станислава Совиљ-Гмизић¹

¹Институт за плућне болести Војводине, Сремска Каменица, Србија;

²Универзитет у Новом Саду, Медицински факултет, Нови Сад, Србија

САЖЕТАК

Увод Дијагностички и терапијски алгоритам за плућну емболију (ПЕ) више пута се мењао, али је увек први корак у постављању дијагнозе одређивање степена клиничке вероватноће постојања ПЕ, што условљава даље процедуре. Циљ је био да се илуструје терапијска дилема код болеснице са интермедијарно високим ризиком за 30-дневни морталитет.

Приказ болесника Болесница стара 56 година упућена је у нашу институцију са сумњом на ПЕ. Према Велсовом бодовном систему припадала је групи са малом клиничком вероватноћом постојања ПЕ, а применом препоручених критеријума групи болесника са интермедијарно високим ризиком за смртни исход у наредних 30 дана. ПЕ је потврђена КТ-ангиографијом. Примењена је, према препорукама, иницијално хепаринска терапија, а због настанка

хемодинамске нестабилности у даљем току и тромболитичка терапија, са позитивним исходом. Код болеснице је иницијално у биохуморалном статусу био повишен маркер ткивне хипоperfузије – лактат, који се не ради рутински код болесника са ПЕ.

Закључак Код болесника са средње високим ризиком од смртог исхода у року од 30 дана од настанка болести актуелна је препорука да се лечење започне хепарином, а да се сталним мониторингом на време препознају знаци хемодинамске нестабилности и пропише тромболитична терапија. У приказаном случају тромболитичка терапија је прописана тек по развоју хемодинамске нестабилности, упркос претходно присутним раним знацима ткивне хипоperfузије.

Кључне речи: плућна емболија; тромболитичка терапија; лактат