

PRELIMINARY REPORT / ПРЕТХОДНО САОПШТЕЊЕ

Clinical analysis and surgical treatment of frontal sinus mucoceles – 10 years' experience of seven cases

Dragan Krasić^{1,2}, Zoran Pešić^{1,2}, Dragan Mihailović^{1,3}, Miloš Trajković², Nikola Živković^{1,3}, Staša Krasić⁴¹University of Niš, Faculty of Medicine, Department of Pathology, Niš, Serbia;²Clinic of Dentistry, Niš, Serbia;³Clinical Center of Niš, Pathology and Pathological Anatomy Center, Niš, Serbia;⁴University of Belgrade, School of Medicine, Belgrade, Serbia**SUMMARY**

Introduction/Objective A mucocele is a benign cystic but extremely expansive change in paranasal cavities, first described in literature by Langenbeck in 1820. The etiology of mucoceles is still a subject of debate. It is assumed that the obstruction of the frontal sinus duct and drainage impairment into the middle nasal meatus, as a consequence of a chronic infection, trauma, or tumor, represent one of the main causes of their occurrence.

The aim of this study was to describe ophthalmological and clinical properties of frontal sinus mucoceles.

Methods Our retrospective study covered a period of 10 years during which seven patients with mucocele in the frontal sinus were operated on.

Results Predisposing factors for the appearance of frontal sinus mucoceles were observed in six out of seven patients – the existence of a previous surgical intervention in two patients, the existence of a previous injury in four, and one patient did not exhibit the existence of predisposing factors. Four out of seven mucoceles were located in the rear segments of the frontal sinus. The destruction of the anterior sinus wall was observed in one patient, while the process propagation toward the endocranium and the orbit was present in three out of the seven patients. Postoperative epistaxis was noted in two out of three patients treated with transfacial approaches.

Conclusion Transcranial and transfacial approaches are treatment methods for advanced mucoceles with a present intraorbital, intracranial, and endonasal process propagation.

Keywords: mucoceles; frontal sinus; diagnostics; surgery treatment

INTRODUCTION

A mucocele is a benign cystic but extremely expansive change in paranasal cavities, first described in literature by Langenbeck in 1820 [1].

The etiology of mucoceles is still a subject of debate in scientific circles and it has not been defined in great detail. It is assumed that the obstruction of the frontal sinus duct and drainage impairment into the middle nasal meatus, as a consequence of a chronic infection, trauma or tumor, represent one of the main causes of their occurrence [2].

Growth and development of mucoceles are very slow and can last for several years. The appearance of symptoms is associated with complications of the process spreading outside the sinuses, as a consequence of bone destruction, or with a secondary infection in terms of mucopyocele [3].

Given the direct contact of the frontal sinus with the brain parenchyma, orbit and nasal cavity, a possible extension of mucoceles towards them represents one of the complications of advanced and, in most cases, late diagnosed mucoceles.

Ophthalmological disorders in terms of diplopia, upper lid ptosis, proptosis, bulbus dislocation, and periorbital swelling represent

the symptoms of the process spreading toward the orbit [4]. Intracranial extension developed as a consequence of the posterior sinus wall destruction may cause meningitis, meningoencephalitis, pneumocephalus, brain abscess, and cerebrospinal liquid extravasation [5]. Mucocele expansion toward the nasal cavity leads to nose obstruction and the appearance of anosmia [6]. Headaches and swelling in the orbit area represent the key reasons why patients turn to doctors.

The aim of this study was to describe ophthalmological and clinical properties of these lesions, analyze used surgical approaches, and present the incidence of recurrence and complications of surgical treatments.

METHODS

The conducted study is retrospective. It covered a period of 10 years during which, after surgical examinations, complete diagnostics, and preparation, seven patients with pathohistologically confirmed mucocele in the frontal sinus were operated on. All the patients were operated on using endotracheal anesthesia at the Department of Maxillofacial Surgery, Clinic of Dentistry, Faculty of Medicine in Niš,

Примљено • Received:

October 7, 2016

Прихваћено • Accepted:

May 24, 2017

Online first: May 30, 2017

Correspondence to:

Nikola ŽIVKOVIĆ
Department of Pathology
Faculty of Medicine
University of Niš
81 Dr. Zorana Đinđića Blvd
18000 Niš, Serbia
nikolazivkovich@gmail.com

Serbia, between 2002 and 2012. The analysis included the sex and age of patients, the presence of a chronic disease, predisposing factors, clinical characteristics, surgical approach type, recurrence, and postoperative complications in all patients. The minimal period of monitoring each patient was two years.

Prior to surgical treatments, in the observation stage, multi-slice computed tomography was done in all the patients to determine the location of mucoceles, the presence of bone destruction of sinus walls, and the extension rate toward the orbit, brain parenchyma, or nasal cavity.

RESULTS

The mean age of the mentioned group of patients was 56, with the age range being 28–65 years. As for the sex, four out of the seven patients included in the study were male.

The presence of chronic diseases was noted in six out of the seven patients – chronic artery hypertension in five, diabetes mellitus in two, and chronic obstructive pulmonary disease in only one patient (14%).

Predisposing factors for the appearance of frontal sinus mucoceles were observed in six out of the seven patients,

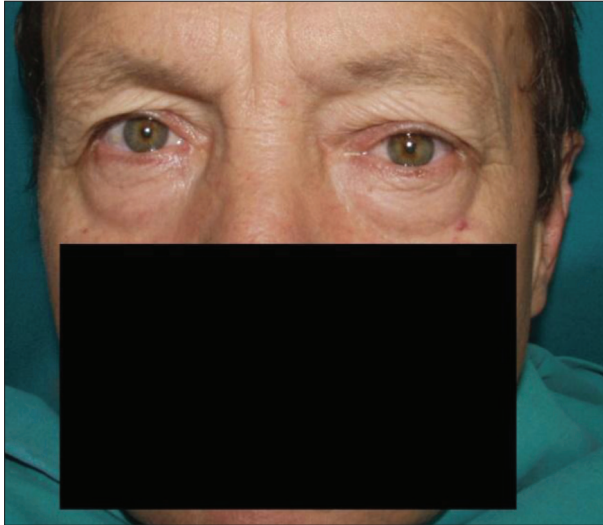


Figure 1. Temporal sinus mucocele with endocranial and intraorbital propagation; the presence of exophthalmos accompanied by inferior dislocation of bulbus with no defects in the visual field

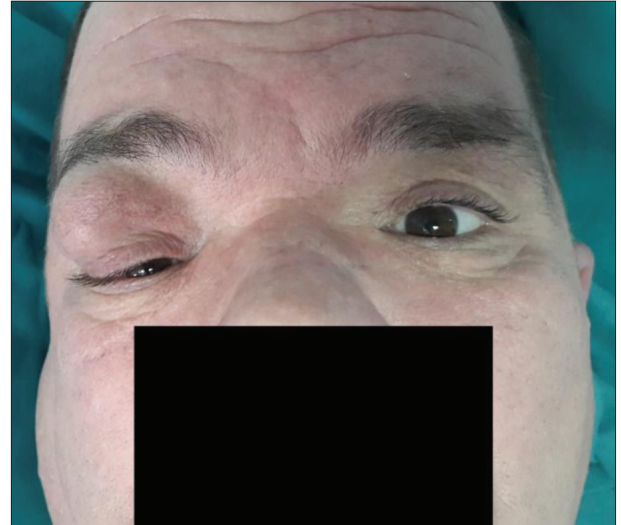

Figure 3. Frontal sinus mucocele with intraorbital extension; the presence of enophthalmos, inferior dislocation of the bulbus without diplopia and defects in the visual field area

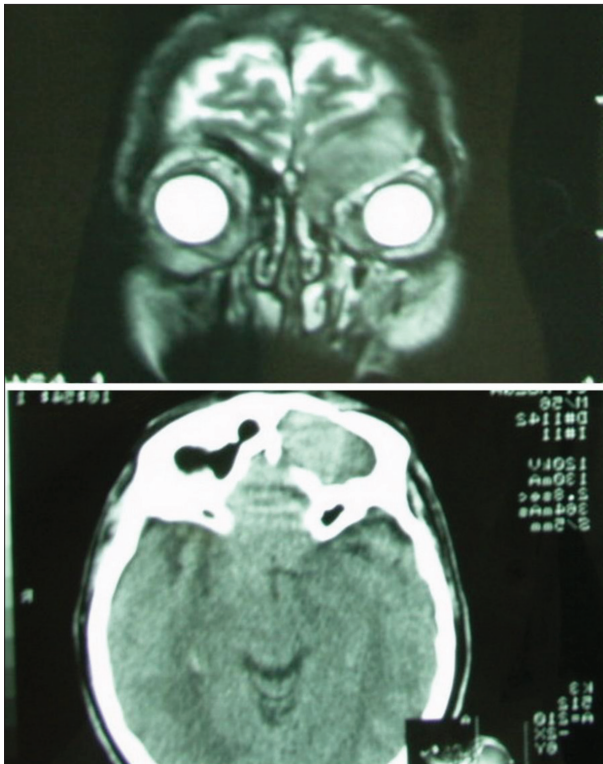


Figure 2. Hypodense formation in the left frontal sinus and left orbit; process extension presents frontobasally and toward the left orbit

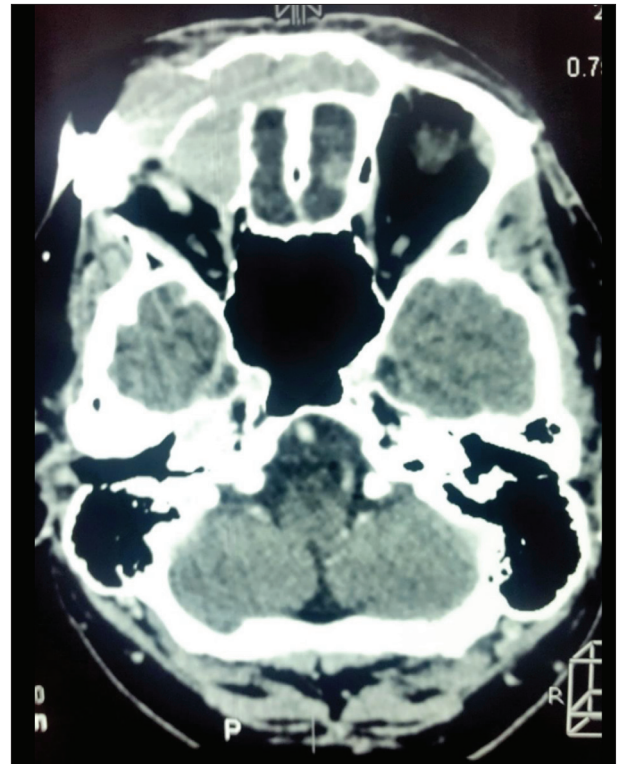


Figure 4. Hypodense formation in the right frontal sinus with signs of the sinus floor destruction and penetration into the right orbit

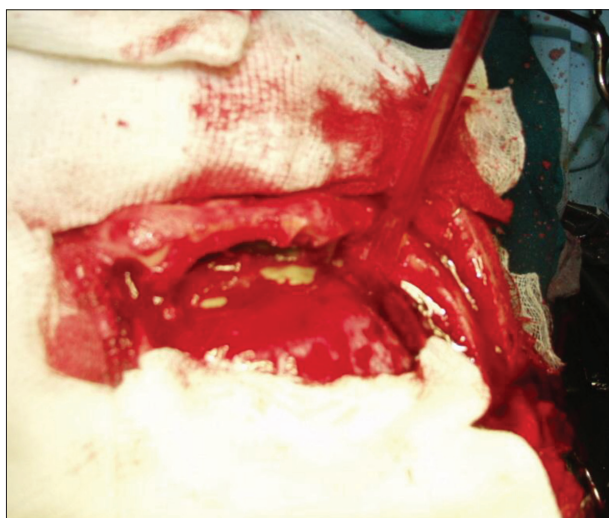


Figure 5. Post bifrontal craniotomy condition; mucopycele in the left frontal sinus

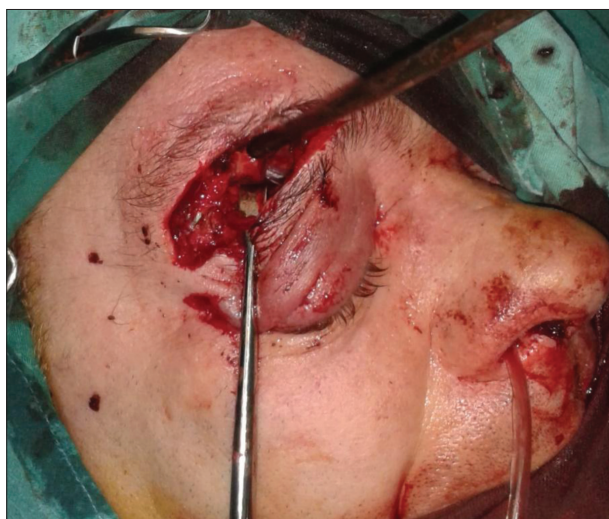


Figure 6. Post frontal sinus mucocele and orbit extirpation condition; drainage performed through the nose

the existence of a previous surgical intervention in two, the existence of a previous injury in four out of the seven patients, whereas one patient did not exhibit the existence of predisposing factors.

Four out of seven mucoceles were located in the rear segments of the frontal sinus. The destruction of the anterior sinus wall, dura infiltration, and intracranial propagation process were observed in one patient, while in three the process propagation toward the endocranium and the orbit was present (Figures 1 and 2).

In three cases, the process extension toward the orbit was present along with the mentioned ophthalmological disorders (Figures 3 and 4). The occurrence of diplopia was observed in two cases.

In four patients, bifrontal craniotomy was performed after the bicorony approach due to possible exploration of the anterior cranial fossa, frontal sinuses, and orbits. The tumor formation was completely separated from the dura, periorbital tissue, and orbit content. Bone defects were found in the area of the frontal sinus posterior

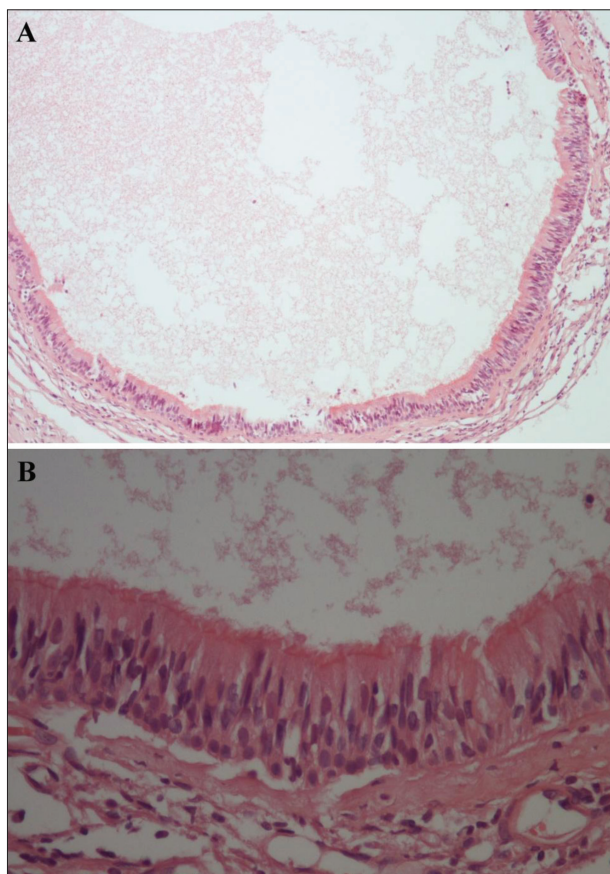


Figure 7. Cyst showing pseudostratified columnar ciliated epithelium containing mucous cells (H&E; A: $\times 4$; B: $\times 20$)

wall, orbit roof, and upper third of the medial orbit wall. The posterior sinus wall was reconstructed with Palacos® (Heraeus Medical, Hanau, Germany) biosynthetic material, placed between the dura of the posterior sinus wall. Bone defects in the orbit roof and medial wall area were reconstructed with free bone transplants from calvaria and titanium meat. Dura defects were reconstructed with fascia lata (Figure 5). A pericranial flap characterized by good vascularization, appropriate voluminosity, and minimal morbidity of the donor site was placed on the sinus floor over the nasofrontal opening in order to separate the sinus from the nasal cavity and thus prevent infection.

In three patients, the transfacial approach according to Lynch–Howarth was used, with the extension toward the lateral border of the supraciliary region. The mucocele tissue was separated from the periorbital tissue, with lacrimal glands and oculogyric muscles preserved. The average size of the orbit roof and frontal sinus floor defects was 2×1 cm. The existing bone defect in all cases was reconstructed with titanium meat. Moreover, in all patients, a Silastic® tube was placed endonasally to keep the sinus duct passable, and then removed after six weeks (Figure 6).

Histologically, the lesions were characterized by dilated epithelium lined ducts filled with mucin, often associated with extravasation of mucin into the stroma. The cysts were lined by flat or low cuboidal epithelium (Figure 7).

The appearance of major postoperative complications was not recorded. In two out of three patients treated with

transfacial approaches, postoperative epistaxis was noted and stopped using frontal nose tamponade.

Recurrence was observed in one out of three cases treated with the transfacial approach. After a performed re-intervention and a three-year-long monitoring of patients, recurrence was not recorded. Recurrence in patients treated with the transcranial approach was not recorded.

There were no cases of endonasal spreading of the frontal sinus mucocele in the study.

DISCUSSION

Mucoceles are most often located in the frontal sinus (60–89%), ethmoid sinus (16%), whereas they are extremely rare in the maxillary (3%) and sphenoidal (1%) sinus [7]. This conclusion is supported by the fact that the frontal sinus excretory duct is 15–20 cm long, and 1–2 mm wide, often with the uneven lumen. It is more frequent in men. The highest incidence is among the population between 55 and 65 years of age [8].

The etiology of frontal sinus mucoceles is multifactorial and still has not been clarified in detail. Pathological entities whose presence may lead to disorders of drainage through the nasofrontal duct represent a dominant factor in their occurrence. Most often, they include chronic sinusitis, allergic reactions on the level of sinus mucosa, injuries, anatomic sinus and excretory duct anomalies, tumors, etc.

In a retrospective study which included 72 patients with mucoceles in paranasal cavities, Obeso et al. [9] determined that 35% of their examinees stated they had underwent previous surgical interventions on the sinuses, thus indicating a possible iatrogenic cause of their occurrence.

The most common mechanism of bone destruction of sinus walls is a continuous pressure which leads to bone ischemia, necrosis, and resorption. The obstruction of the sinus excretory duct and a consequent infection result in the accumulation of lymphocytes and neutrophils which, by creating cytokine molecules, lead to enzymatic osteolysis of sinus walls [10]. It has been determined that the fibroblasts from paranasal cavities with existing signs of infection create greater amounts of prostaglandin E2 and collagenases, compared to the mucosal fibroblasts with physiological characteristics that have the key role in increased osteolysis processes of sinus walls and a consequent mucocele expansion [11].

Bacteriological findings of mucoceles are negative in most cases. In cases of a present infection, the presence of *Staphylococcus aureus*, *Haemophilus* species, and Gram-negative bacilli types was determined. Dominant anaerobic bacilli include *Propionibacterium acnes*, *Peptostreptococcus*, *Prevotella* and *Fusobacterium* species [12].

The diagnostics of mucoceles includes a detailed anamnesis, clinical examination, and the use of additional radiological methods, computed tomography (CT) and magnetic resonance imaging (MRI) above all. CT with contrast is the most reliable and most used method for

the determination of the bone destruction rate, whereas MRI is used for complicated cases with intracranial process spreading or a present infection due to its ability to precisely determine the contact of a mucocele with the brain parenchyma and orbit content [13]. CT findings are characterized by the appearance of the so-called jagged bone, formed as a consequence of alternating bone remodeling processes.

Bulbus proptosis, present in 85% of cases, is a pathognomonic sign of mucocele spreading toward the orbit [14]. The spreading of the process from the direction of the sinuses leads to anterior dislocation of the bulbus, while processes from the ethmoidal sinus lead to lateral dislocation.

Dermoid cysts, histiocytosis, tuberculosis, fungal infections, fronto-orbital cholesterol granulomatosis, secondary deposits, orbit and sinus tumors represent pathological entities which are included in the differential analysis of frontal sinus mucoceles [15].

The treatment of frontal sinus mucoceles is surgical, with the aim to establish the anatomical and functional integrity of sinuses. Depending on the size of the process and the engagement of surrounding anatomic structures, the extensivity of a surgical intervention ranges from a minimal invasive endoscopic surgery to craniotomy with or without sinus obliteration [16].

Inability to completely remove mucoceles and establish patency of the nasolacrimal duct, as well as the extension of the process toward the orbit or brain parenchyma, represent indicators for open approaches [17].

The aim of a surgical treatment is to entirely remove changes along with the repair of intraorbital and intracranial complications, form drainage into the nose through the nasofrontal duct, or to remove the whole mucosa with duct and sinus obturation. In the case of posterior sinus wall erosion and dura involvement, the bicorony approach, radical mucocele removal, cranialization and obturation of the nasofrontal duct are indicated [18]. Transfacial approaches are indicated in case of the process extension toward the orbit and nose with crucial preservation of posterior sinus wall continuity [19].

The advantages of transfacial and transcranial approaches compared to endoscopic approaches are reflected in the possibility to explore the whole sinus, prevent blind curettage and possible dura damage, create adequate space for possible sinus obliteration, and prevent recurrence.

The prognosis of frontal sinus mucoceles is usually good, with an extremely low recurrence rate (10%) [20]. Regardless of the previous statement, long-term monitoring of patients after surgical treatments is recommended.

CONCLUSION

The specificity of the anatomic region represents one of the reasons for the spreading of mucoceles toward the orbit, nasal cavity, and anterior cranial fossa, as well as for the occurrence of symptoms due to which patients initially consult doctors.

The diagnosis of frontal sinus mucocoeles is set based on a detailed anamnesis, clinical examination, and the use of additional radiological methods.

The treatment of frontal sinus mucocoeles is always surgical. Endoscopic surgery and marsupialization of a

change are an indicator for smaller, early-diagnosed mucocoeles. Transcranial and transfacial approaches represent treatment methods for advanced mucocoeles with a present intraorbital, intracranial, and endonasal process propagation.

REFERENCES

- Alberti PW, Marshall HF, Black JI. Fronto-ethmoidal mucocoele as a cause of unilateral proptosis. *Br J Ophthalmol*. 1968; 52(11):833–8.
- Pierce J, Stern A. Benign cysts and tumors of the paranasal sinuses. *Oral Maxillofac Surg Clin North Am*. 2012; 24(2):249–64.
- Meer S, Altini M. Cysts and pseudocysts of the maxillary antrum revisited. *SADJ*. 2006; 61(1):10–3.
- Hayasaka S, Shibasaki H, Sekimoto M, Setogawa T, Wakutani T. Ophthalmic complications in patients with paranasal sinus mucopyocoeles. *Ophthalmologica*. 1991; 203(2):57–63.
- Mourouzis C, Evans B, Shenouda E. Late presentation of a mucocoele of the frontal sinus: 50 Years postinjury. *J Oral Maxillofac Surg*. 2008; 66(7):1510–3.
- Weitzel EK, Hollier LH, Calzada G, Manolidis S. Single stage management of complex fronto-orbital mucocoeles. *J Craniofac Surg*. 2002; 13(6):739–45.
- Pilch ZB. *Head and neck surgical pathology*. 1st edition. London: Lippincott Williams & Wilkins; 2000.
- Arrué P, Kany MT, Serrano E, Lacroix F, Percodani J, Yardeni E, et al. Mucocoeles of the paranasal sinuses: Uncommon location. *J Laryngol Otol*. 1998; 112(9):840–4.
- Obeso S, Llorente JL, Pablo Rodrigo J, Sánchez R, Mancebo G, Suárez C. Paranasal sinuses mucocoeles: Our experience in 72 patients. *Acta Otorrinolaringol Esp*. 2009; 60(5):332–9.
- Lund VJ, Milroy CM. Fronto-ethmoidal mucocoeles: A histopathological analysis. *J Laryngol Otol*. 1991; 105(11):921–3.
- Lund VJ, Harvey W, Meghji S, Harris M. Prostaglandin synthesis in the pathogenesis of fronto-ethmoidal mucocoeles. *Acta Otolaryngol*. 1988; 106(1-2):145–51.
- Brook I, Frazier EH. The microbiology of mucopyocoele. *Laryngoscope*. 2001; 111(10):1771–3.
- Gavioli C, Grasso DL, Carinci F, Amoroso C, Pastore A. Mucocoeles of the frontal sinus. Clinical and therapeutical considerations. *Minerva Stomatol*. 2002; 51(9):385–90.
- Edelman RR, Hesselink JR, Zlatkin MB, Crues JV. *Clinical magnetic resonance imaging*, 3rd edition. Philadelphia: Elsevier; 2006. p. 2035–7.
- Tan CS, Yong VK, Yip LW, Amrith S. An unusual presentation of a giant frontal sinus mucocoele manifesting with a subcutaneous forehead mass. *Ann Acad Med Singapore*. 2005; 34(5):397–8.
- Constantinidis J, Steinhart H, Schwerdtfeger K, Zenk J, Iro H. Therapy of invasive mucocoeles of the frontal sinus. *Rhinology*. 2001; 39(1):33–8.
- Park CM, Stoffella E, Gile J, Roberts J, Herford AS. Osteoplasty flap technique for repair of latent (30-year) post-traumatic frontal sinus mucocoele: Case report and review of the literature. *J Oral Maxillofac Surg*. 2012; 70(9):2092–6.
- Suri A, Mahapatra AK, Gaikwad S, Sarkar C. Giant mucocoeles of the frontal sinus: series and review. *J Clin Neurosci*. 2004; 11(2):214–8.
- Sama A, McClelland L, Constable J. Frontal sinus mucocoeles: New algorithm for surgical management. *Rhinology*. 2014; 52(3):267–75.
- Weitzel EK, Hollier LH, Calzada G, Manolidis S. Single stage management of complex fronto-orbital mucocoeles. *J Craniofac Surg*. 2002; 13(6):739–45.

Клиничка анализа и хируршко лечење мукокела чеоног синуса – 10 година искуства са седам болесника

Драган Красић^{1,2}, Зоран Пешић^{1,2}, Драган Михаиловић^{1,3}, Милош Трајковић², Никола Живковић^{1,3}, Сташа Красић⁴

¹Универзитет у Нишу, Медицински факултет, Катедра за патологију, Ниш, Србија;

²Клиника за стоматологију, Ниш, Србија;

³Клинички центар Ниш, Центар за патологију и патолошку анатомију, Ниш, Србија;

⁴Универзитет у Београду, Медицински факултет, Београд, Србија

САЖЕТАК

Увод/Циљ Мукокела је бенигна цистична али веома пространа промена у параназалним шупљинама. Етиологија је још увек предмет дискусије, а претпоставља се да су неки од главних узрока њеног јављања опструкција дренаже фронталног синуса и оштећења у средњем носном меатусу, као последица хроничне инфекције, трауме или тумора.

Циљ овог истраживања је био да се опишу клиничке карактеристике и хируршко лечење мукокела фронталног синуса.

Метод Ретроспективна студија за период од 10 година и седам болесника са мукокелама фронталног синуса.

Резултати Предиспонирајући фактори за настанак мукокеле фронталног синуса су уочени код шест болесника: претхо-

дне хируршке интервенције код два болесника, претходне повреде код четири болесника, а код једног не постоје предиспонирајући фактори. Четири мукокеле су се налазиле у задњим сегментима фронталног синуса. Уништење предњег синусног зида уочено је код једног болесника, а код три болесника процес се простирао у ендокранијум и орбиту. Код два од три болесника са трансфацијалним приступом јавила се постоперативна епистакса.

Закључак Транскранијални и трансфацијални приступи су методе лечења за напредне мукокеле са интраорбиталном, интракранијалном и ендоназалном пропацијом.

Кључне речи: мукокела; фронтални синус; дијагностика; хируршко лечење