

CASE REPORT / ПРИКАЗ БОЛЕСНИКА

Simultaneous combined laparoscopic-endoscopic removal of a large gastric trichobezoar and gastric polypectomy

Svetlana Bukarica^{1,2}, Radoica Jokić^{1,2}, Jelena Antić^{1,2}, Mirjana Stojšić³, Aleksandar Komarčević^{1,2}, Ivana Fratric^{1,2}

¹Institute for Children and Youth Health Care of Vojvodina, Clinic for Pediatric Surgery, Novi Sad, Serbia;

²University of Novi Sad, Faculty of Medicine, Novi Sad, Serbia;

³Institute for Children and Youth Health Care of Vojvodina, Department of Pediatrics, Novi Sad, Serbia



SUMMARY

Introduction Trichobezoars and gastric polyps are very rare conditions in children and may pose a diagnostic and therapeutic challenge. The purpose of this work is to present our successful experience using combined laparoscopic-endoscopic procedure for simultaneous treatment of a trichobezoar and gastric polyp in the same patient.

Case outline We present an unusual case of a 15-year-old girl whose symptoms included abdominal pain, non-bilious vomiting after feeding, including undigested food and sometimes hair. Positive history of trichophagia indicated that a trichobezoar could be the reason for her problems. Endoscopy and ultrasound examination revealed a trichobezoar occupying almost the entire capacity of the stomach, as well as one oval polyp in the prepyloric area of the antrum. Simultaneous combined laparoscopic-endoscopic rendezvous procedure was performed. The trichobezoar (14 × 6 cm) and the gastric polyp (2.2 × 1.7 cm) were completely removed laparoscopically through anterior gastrotomy, with great support of an adequate endobag and mechanical fragmentation of trichobezoar. The postoperative course was uneventful.

Conclusion This case shows that diagnostic endoscopy is valuable and that the combined laparoscopic-endoscopic technique is feasible, safe and recommended treatment for simultaneous removal of a gastric trichobezoar and gastric polypectomy.

Keywords: trichobezoar; gastric polyp; laparoscopy; endoscopy

INTRODUCTION

The purpose of this work is to present our positive experience using combined laparoscopic-endoscopic procedure and to review current literature in resolving joint appearance of trichobezoars and gastric polyps. A formation of undigested material in the gastrointestinal tract is bezoar [1]. In a situation of a long-term ingestion of hair, i.e. trichophagia, this type of bezoar is called trichobezoar, which is at the same time the most common form of bezoar [2]. Hair cannot be digested and due to its smooth nature also cannot be propelled by peristalsis, which causes formation of a bezoar within the stomach over a certain period. The hair in a trichobezoar always appears black because of the influence of gastric acid on hair proteins [1, 3]. In literature, the association between bezoars and gastric polyps is relatively frequently described; however, it is not so widely appreciated. Even though biopsies of gastric polyps usually show an inflammatory origin, in some cases their malignant alteration was found [4]. A multidisciplinary approach with early diagnosis and surgical removal of gastric bezoars and polyps are essential [1, 3, 5].

CASE REPORT

Our case was a 15-year-old girl with abdominal pain and vomiting after feeding. The vomit included undigested food and sometimes hair. Due to occasional gastrointestinal bleeding she appeared extremely pale. Her abdomen was non-distended without palpable mass. Positive history of trichotillomania and trichophagia led us to believe that trichobezoar could be the reason for her problems. Her mother noticed that she had lost weight. Laboratory values did not show any abnormalities, especially serum proteins and particularly albumins, amylase, and lipase levels, and reactants of acute phase of inflammation such as C-reactive protein and erythrocyte sedimentation rate. At endoscopy and ultrasound examination a trichobezoar occupying almost entire capacity of the stomach was noted. Furthermore, one oval sessile polyp, not bleeding actively, was revealed in the prepyloric area of the antrum.

Combined laparoscopic-endoscopic rendezvous procedure was performed. The role of endoscopy during this “rendezvous” procedure was to enable precise placement of a gas-

Received • Примљено:

June 30, 2016

Revised • Ревизија:

September 6, 2016

Accepted • Прихваћено:

October 4, 2016

Online first: March 7, 2017

Correspondence to:

Svetlana BUKARICA
Hajduk Veljkova 10
21000 Novi Sad
bukaricasvetlana@gmail.com

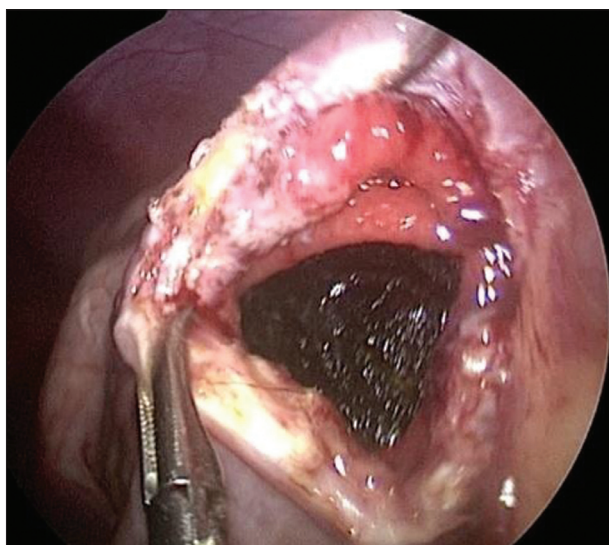


Figure 1. Trichobezoar seen through created anterior gastrotomy

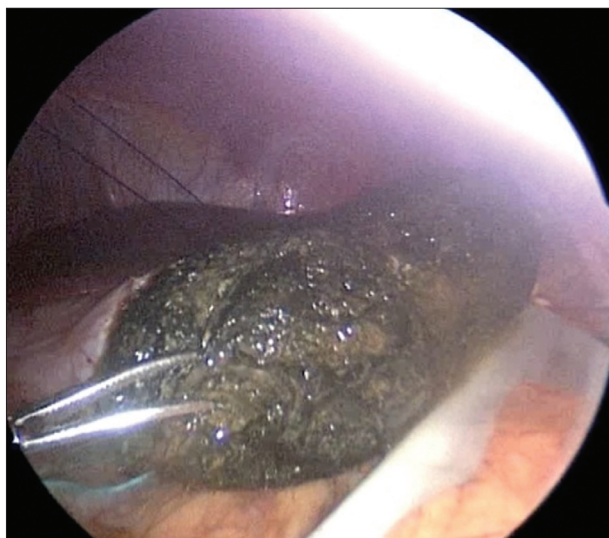


Figure 2. Removal of the trichobezoar (14 × 6 cm) from the stomach using a specially modeled endobag (Endo Catch™ 15 × 10 cm)

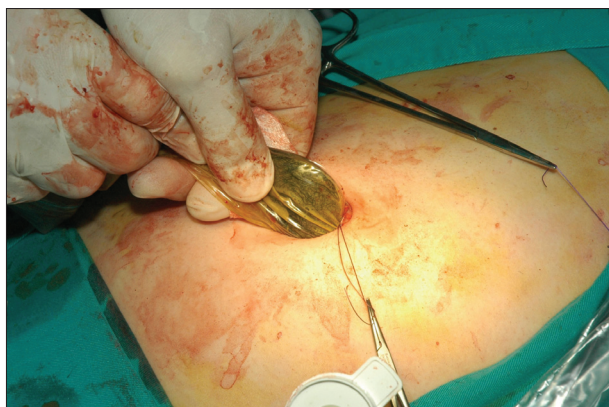

Figure 3. Removal of the trichobezoar from the abdominal cavity through the enlarged umbilical port

trotomy incision, to exclude the possible existence of the Rapunzel syndrome, and to navigate surgeon to find the gastric polyp. The most important part of endoscopy during the above mentioned procedure is to control bleeding. After endoscopic navigation, laparoscopic exploration of

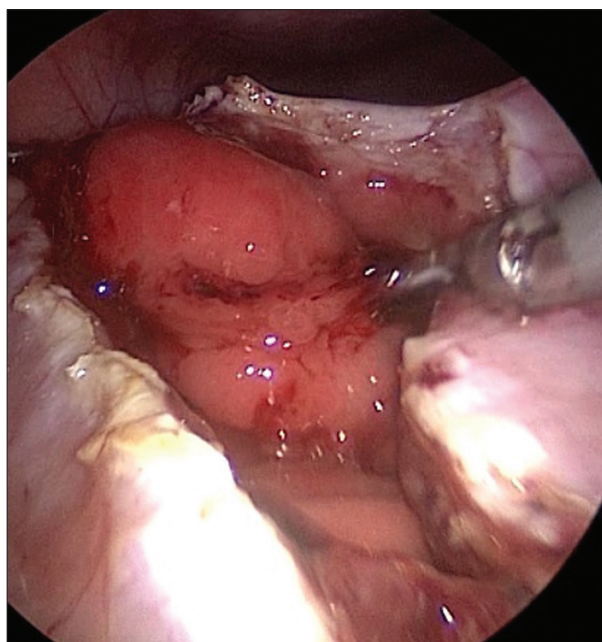


Figure 4. Gastric polypectomy (2.2 × 1.7 cm)

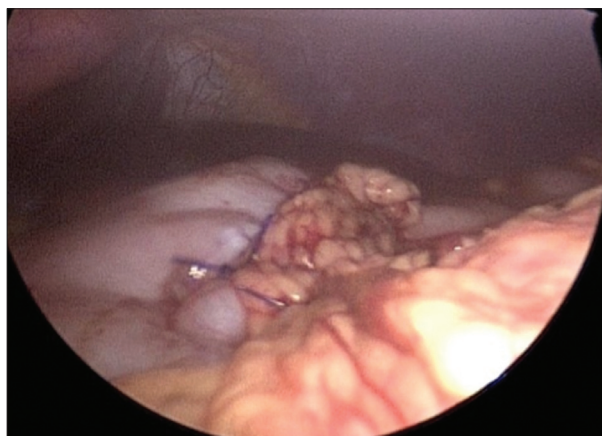

Figure 5. Omentoplasty using non-absorbable 3-0 suture

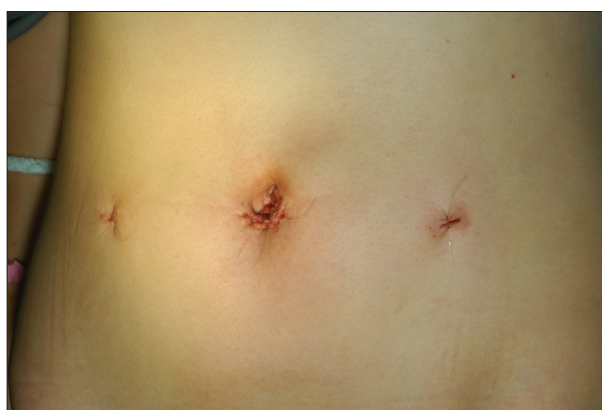

Figure 6. The aesthetic result of the operation

the entire intestine was the first part of the operation. The trichobezoar (14 × 6 cm) was completely removed laparoscopically through created anterior gastrotomy (Figure 1), also using specially modeled endobag (Endo Catch™ 15 × 10 cm; Covidien Ltd., Dublin, Ireland) (Figure 2). Incision of the first umbilical port was minimally enlarged, and before complete extraction of the trichobezoar from the

abdomen, its mechanical fragmentation in the endobag was performed without spilling into the abdominal cavity (Figure 3). The trichobezoar had a highly offensive smell, which was the reason for smearing, culturing and administering antibiotics postoperatively. Additionally, gastric polypectomy (dimensions 2.2×1.7 cm) was also done laparoscopically using the Ultracision® Harmonic® (Ethicon Endo-Surgery Inc., Cincinnati, OH, USA) scalpel and gastrotomy through the same (Figure 4). After resection and exact hemostasis, the polyp was removed from the abdominal cavity by placing an endoscopic extraction basket (Roth Net®; US Endoscopy, Mentor, OH, USA) through one of the created ports. Histopathological examination confirmed it to be a hyperplastic gastric polyp.

Firstly, mucosal defect after polypectomy was sutured using absorbable sutures 4-0; afterwards, the gastric wall was closed by using intracorporeal suturing. Omentoplasty completed the procedure (Figure 5). For that we used non-absorbable 3-0 interrupted suture extramucosally. The same stiches were applied for omentoplasty. Finally, the nasogastric tube was placed. The endoscopist controlled the intraluminal hemostasis throughout the procedure. The postoperative course was uneventful, per oral nutrition started after three days (Figure 6). The gastroenterologist and psychiatrist continued the treatment.

DISCUSSION

Trichobezoars (“hair ball”) are usually located in the stomach. Incidentally, a gastric trichobezoar can extend through the pylorus into distal parts of the gastrointestinal tract. This rare type is called Rapunzel syndrome. Between many complications of this condition, the most frequent are mucosal erosion, ulceration or even perforation of the stomach and intestine, intestinal invagination, jaundice, pancreatitis, and extremely rarely even death [1].

In child population, trichobezoars are found in 90% of the cases. On the other hand, they are an uncommon condition of which only approximately 300 cases have been reported in papers [2]. Main causes are habitual hair pulling called trichotillomania and ingestion of hair called trichophagia, which are usually related to obsessive-compulsive disorders and/or depression [2]. In our case, the child was not controlled preoperatively by a psychiatrist. Physicians should always keep in mind the possibility of a bezoar formation especially after gastric surgery, in case of celiac disease, diabetes mellitus, myotonic muscular dystrophy, cimetidine therapy, etc. [1, 2, 6]. In our case, positive history of trichophagia and visible weight loss pointed us to the right direction in diagnosis and appropriate treatment.

Standard clinical findings are usually non-specific. In literature, Lamerton’s sign, a large mobile epigastric mass, is described as a typical clinical manifestation. It is clear that it may pose a diagnostic challenge when during clinical examination it is not found [1].

Ripolles et al. [7] compared conventional abdominal radiographs, sonography, and computed tomography. A typical computed tomography image shows a well-defined

intraluminal ovoid heterogeneous mass with interspersed gas [2, 4]. However, endoscopy is essential and the best choice in the diagnosis process [8]. In our case, sonography and endoscopy revealed huge trichobezoar and polypoid mass in the antrum of the stomach.

The endoscopist should closely monitor if the pylorus is normal and that there is no distal obstruction. It is well-known that in 17% of cases trichobezoar can be multiple. Also, distal migration of the subsidiary fragments may cause complete or incomplete small bowel obstruction [8]. This is the reason why the entire digestive tract should be examined thoroughly to prevent secondary ileus [8]. We also started the operation with endoscopic navigation and laparoscopic exploration of the entire intestine.

Current data propose many therapy solutions such as endoscopy, standard laparotomy, minimal invasive surgery, and even ineffective medical treatment with enzymatic degradation [1, 2, 9, 10].

Many authors suggest standard open surgery as appropriate treatment for children with trichobezoars, because of better results of this method in comparison with endoscopy and laparoscopy [1, 11]. Occasional reports inform about new therapeutical methods like extracorporeal shock wave lithotripsy, laser, and the combination of endoscopy and laparoscopy. The last report from China even claimed 100% success rate in resolving trichobezoars using a new “explosive” technique through the endoscope [6]. However, clinical experience is still modest for their promotion or suggestion.

Except removal by conventional laparotomy, in some papers, a minimal invasive approach, such as laparoscopy is also proposed. Nirasawa et al. [12] reported successful laparoscopic removal of a trichobezoar for the first time. After this presentation only six other similar reports were published [10]. Still, progression in the laparoscopic technique, in general and peculiarly for the removal of trichobezoars, and exploration of the entire intestine, is not so easy to achieve [13, 14].

Despite the fact that literature describes combined laparoscopy and endoscopy in the management of trichobezoars, there is only one publication addressing this combined technique for the same pathology. [14] We have used this technique at our institute since 2009.

A particularly limiting factor for complete laparoscopic or combined laparo-endoscopic procedure is the size of a trichobezoar. In our case, the largest available endobag measuring 15×10 cm allowed for laparoscopic removal of a trichobezoar. However, to prevent abdominal contamination it was necessary to gently pull trichobezoar from the stomach into the endobag. Also, the only way to insert the trichobezoar into the endobag was to pull it down and place it in its width. In the literature, minimal and maximal dimensions of gastric bezoars are $6 \times 6 \times 5$ cm and $15 \times 10 \times 10$ cm, respectively, and for intestinal bezoars the measurements are $3 \times 3 \times 4$ cm to $4 \times 7 \times 7$ cm [8]. Specified sizes of trichobezoars allow their placement in standardized and commercially available endobags. This is also important because laparoscopic approach in trichobezoar treatment may seem less attractive due to

possible spilling of contaminated hair into the abdominal cavity [9]. As it is well-known that wound infection even after conventional laparotomy is a frequent complication, bacteriological analysis of a trichobezoar is mandatory [8, 9]. Postoperative administration of antibiotics is obligatory [9]. Trichobezoar recurrence is an additional complication and can occur if the underlying psychological condition is not treated [6, 8].

Bates et al. claimed that formation of gastric polyps is a result of chronic irritation of the gastric mucosa by bezoars [5]. In our case, histopathological analysis confirmed the hyperplastic characteristic of the extirpated polyp.

Our first successful result using combined laparoscopic-endoscopic procedure gave us hope that combining minimal invasiveness with optimal efficiency provides a safe and efficient therapy. Only one similar therapeutical approach can be found in current literature, where trichobezoar fragmentation was made laparoscopically while endoscopy was used for removal of the fragments [13, 14]. In any case where there is information about trichotillomania and trichophagia it is advisable to perform an endoscopic examination.

A combined laparoscopic-endoscopic technique is a feasible and recommended treatment for simultaneous removal of a gastric trichobezoar and gastric polypectomy.

REFERENCES

- Mewa Kinoo S, Singh B. Gastric trichobezoar: An enduring Intrigue. Case Reports in Gastrointestinal Medicine [serial online] 2012 [cited Dec 1st 2014]; Available from: <http://dx.doi.org/10.1155/2012/136963>.
- Rishi M, Elhousieni M, Mishra A, Ehtuish EF, Hanesh A. Trichobezoar. Saudi Med J. 2006; 27(7):1057–9.
- Castle SL, Zmora O, Papillon S, Levin D, Stein JE. Management of Complicated Gastric Bezoars in Children and Adolescents. Isr Med Assoc J. 2015; 17(9):541–4.
- Hossenbocus A, Colin-Jones G. Trichobezoar, gastric polyposis, protein-losing gastroenteropathy and steatorrhea. Gut. 1973; 14(9):730–2.
- Balamtekin A, Cakir M, Polat Z, Vurucu S, Bagci S. A rare cause of vomiting in a neurologically impaired child Phytobezoar. HK J Pediatr (New Series). 2011; 16(4):289–91.
- Coulter R, Antony MT, Bhuta P, Memon MA. Large gastric trichobezoar in a normal healthy woman: a case report and review of pertinent literature. South Med J. 2005; 98(10):1042–4.
- Ripolles T, Garcia-Aguayo J, Martinez J, Gil P. Gastrointestinal bezoars: Sonographic and CT characteristics. Am J Roentgenol. 2001; 177(1):65–9.
- Ersoy YE, Ayan F, Ayan F, Ersan Y. Gastro-intestinal bezoars: a thirty-five years experience. Acta Chir Belg. 2009; 109(2):198–203.
- Patil R, Kadeli V, Belagali H. An interesting case of trichobezoar. JEMDS. 2014; 3(1):51–5.
- Gorter RR, Kneepkens CMF, Mattens ECJL, Aronson DC, Heij HA. Management of Trichobezoar: a case report and literature review. Pediatr Surg Int. 2010; 26(5):457–63.
- Fallon SC, Slater BJ, Larimer EL, Brandt ML, Lopez ME. The surgical management of Rapunzel syndrome: a case series and literature review. J Pediatr Surg. 2013; 48(4):830–4.
- Nirasawa Y, Mori T, Ito Y, Tanaka H, Seki N, Atom Y. Laparoscopic removal of a large gastric trichobezoar. J Pediatr Surg. 1998; 33(4):663–665.
- Kanetaka K, Azuma T, Ito S, Matsuo S, Yamaguchi S, Shirono K, et al. Two-channel method for retrieval of gastric trichobezoar: a report of a case. J Pediatr Surg. 2003; 38:1–2.
- Tudor ECG, Clark MC. Laparoscopic-assisted removal of gastric trichobezoar; a novel technique to reduce operative complications and time. J Pediatr Surg. 2013; 48(3):E13–5.

Истовремено лапароскопско и ендоскопско уклањање гастричног трихобезоара и гастричног полипа

Светлана Букарица^{1,2}, Радоица Јокић^{1,2}, Јелена Антић^{1,2}, Мирјана Стојшић³, Александар Комарчевић^{1,2}, Ивана Фратрић^{1,2}

¹Институт за здравствену заштиту деце и омладине Војводине, Клиника за дечју хирургију, Нови Сад, Србија;

²Универзитет у Новом Саду, Медицински факултет, Србија;

³Институт за здравствену заштиту деце и омладине Војводине, Клиника за педијатрију, Нови Сад, Србија

САЖЕТАК

Увод Трихобезоар и гастрични полип су веома ретки у дечјем узрасту и могу представљати дијагностички и терапијски изазов.

Циљ овог рада је да се прикаже успешно искуство у примени комбиноване лапаро-ендоскопске процедуре приликом истовременог решавања трихобезоара и гастричног полипа код детета.

Приказ болесника Приказујемо 15-годишњу девојчицу са симптомима бола у трбуху, повраћања желудачног садржаја са примесама несварене хране и длака. Анамнестички податак о трихофагији указује на постојање трихобезоара као могућег узрока постојећих тегоба. Ендоскопски и ултразвучни налаз потврдили су дијагнозу. Трихобезоар заузима

скоро у потпуности лумен желуца, а у препилоричној регији верификује се постојање полипа. Лапароскопско-ендоскопском, тзв. *rendez-vous* процедуром, трихобезоар димензија 14 × 6 cm и гастрични полип димензија 2,2 × 1,7 cm су одстрањени кроз предњу гастротомију. Примењен је ендобег, а претходно је трихобезоар фрагментован. Постоперативни период је протекло уредно.

Закључак Овај приказ нам показује значајне могућности комбиноване лапароскопско-ендоскопске технике као сигурног и препорученог терапијског начина у истовременом уклањању гастричног трихобезоара и гастричног полипа.

Кључне речи: трихобезоар; полип; лапароскопија; ендоскопија