

## ORIGINAL ARTICLE / ОРИГИНАЛНИ РАД

# The frequency of secondary glaucoma in patients with iridocorneal endothelial syndrome in correlation with the presence of uveal ectropion

Vujica Marković<sup>1,2</sup>, Aleksandra Radosavljević<sup>1,2</sup>, Dragan Vuković<sup>1,2</sup>, Vesna Jakšić<sup>1,3</sup>, Marija Božić<sup>1,2</sup>, Ivan Marjanović<sup>1,2</sup>, Dejan Rašić<sup>1,2</sup>, Vesna Marić<sup>2</sup>

<sup>1</sup>University of Belgrade, School of Medicine, Belgrade, Serbia;

<sup>2</sup>Clinical Centre of Serbia, Clinic for Eye Diseases, Belgrade, Serbia;

<sup>3</sup>Medical Centre Zvezdara, "Prof. Dr I. Stanković" Clinic for Eye Diseases, Belgrade, Serbia



## SUMMARY

**Introduction/Objective** Iridocorneal endothelial (ICE) syndrome includes 3 clinical forms: progressive iris atrophy, Chandler's syndrome, and Cogan–Reese syndrome. It is characterized by various degrees of iris atrophy, corneal endothelial changes, uveal ectropion, corectopia, peripheral anterior synechiae (PAS) and secondary glaucoma.

The aim of the study was to illustrate forms of ICE syndrome, determine frequency of secondary glaucoma with emphasis on cases with uveal ectropion, analyze response to medication treatment and the need for surgical treatment in intraocular pressure (IOP) control.

**Methods** Patients underwent slit lamp examination, applanation tonometry, gonioscopy, ophthalmoscopy, Humphrey visual field testing and Heidelberg retina tomography. Patients were divided into two groups: group I, without uveal ectropion (22 patients) and group II, with uveal ectropion (14 patients).

**Results** A total of 36 patients were examined in a 10-year period. The average age was 38 years, male to female ratio 1:2. Secondary glaucoma was confirmed in 26 (72.2%) patients, out of which 12 (54.5%) in group I and 14 (100%) in group II. PAS were more frequent in group II. In group I, mean initial IOP was 37 mmHg, and after medication treatment 26 mmHg. Secondary glaucoma was controlled in 50% and remaining 50% underwent surgical treatment. In group II, mean initial IOP was 49 mmHg, and after medication treatment 32 mmHg. All 14 patients (100%) underwent surgical treatment in order to achieve IOP control.

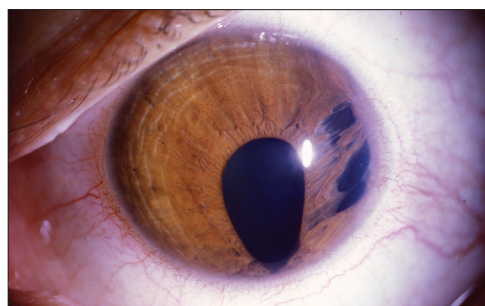
**Conclusion** ICE syndrome is a rare, progressive disease, with high incidence of secondary glaucoma, which is more frequent in cases with uveal ectropion. In these cases, medication treatment is not effective and trabeculectomy with antimetabolite application is necessary.

**Keywords:** ICE syndrome; secondary glaucoma; uveal ectropion

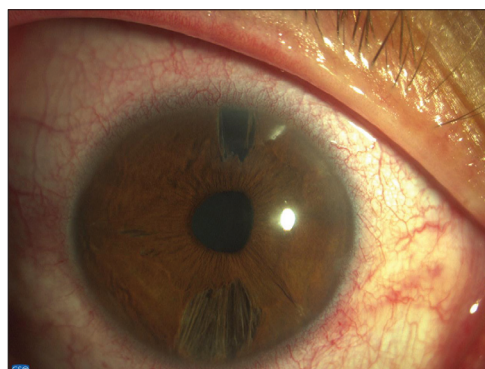
## INTRODUCTION

Iridocorneal endothelial (ICE) syndrome includes three clinical forms: progressive iris atrophy, Chandler's syndrome, and Cogan–Reese (iris nevus) syndrome. Common features of these entities include abnormality of corneal endothelium, iris changes, progressive closure of iridocorneal angle, and secondary glaucoma, in most instances – unilaterally [1].

Progressive iris atrophy was described by Harms [2] in 1903. He depicted extreme iris atrophy with full-thickness iris defects. Focal corneal endothelial changes have enhanced endothelial reflex in the form of "hammered silver." Iris atrophy usually develops in iris stroma and later in pigment epithelial layer, leading to the full thickness iris defects. When these defects occur in areas of iris stretching they are named "stretch holes" (Figure 1). Rarely, iris defects can be seen before the occurrence of corectopia and iris stretching and are named "melting holes" (Figure 2). Cellular membrane composed of one layer of endothelial cells and a membrane similar to Descemet's membrane extends across the



**Figure 1.** Progressive iris atrophy with corectopia and stretch holes, with uveal ectropion



**Figure 2.** Progressive iris atrophy with iris atrophy, minor corectopia and melting holes, without uveal ectropion

Примљено • Received:

May 26, 2016

Ревизија • Revised:

July 26, 2016

Прихваћено • Accepted:

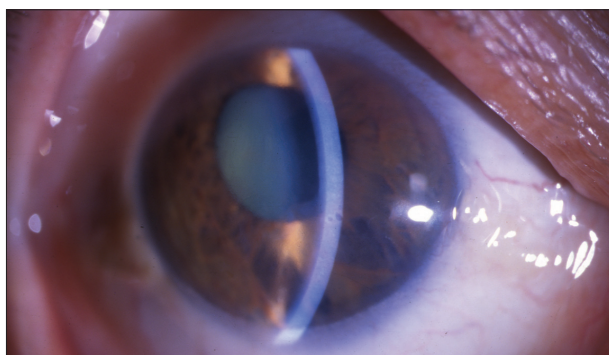
September 7, 2016

Online first: February 28, 2017

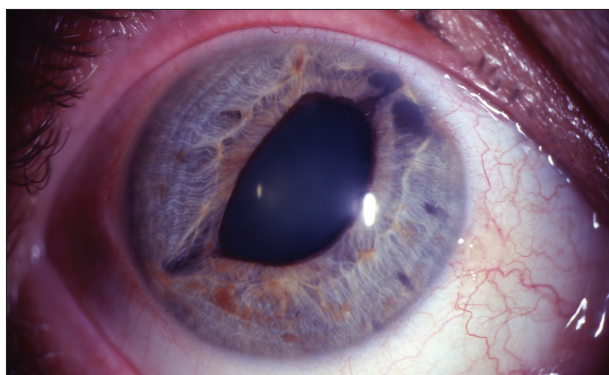Correspondence to:

Aleksandra RADOSAVLJEVIĆ  
Clinic for Eye Diseases, Clinical  
Centre of Serbia, Pasterova 2  
Belgrade, Serbia

[alexandra.radosavljevic@gmail.com](mailto:alexandra.radosavljevic@gmail.com)



**Figure 3.** Chandler's syndrome with enhanced endothelial reflex, corneal edema, atrophy of iris stroma and corectopia, without uveal ectropion



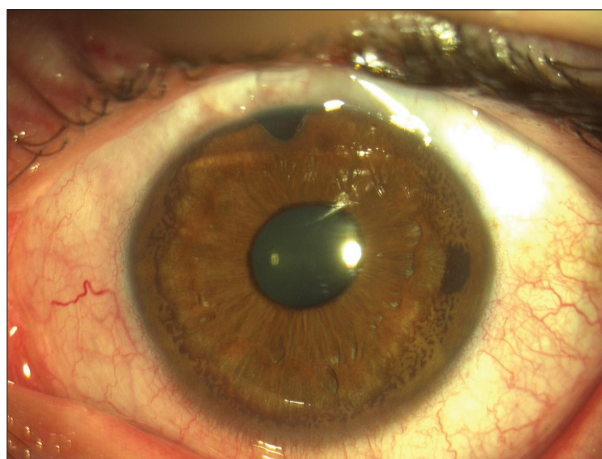
**Figure 4.** Chandler's syndrome with atrophy of iris stroma, corectopia and uveal ectropion

iridocorneal angle towards iris root. Its retraction causes pulling of the iris and pupil distortion, with or without ectropion of the pigment epithelium (Figure 1 and 2).

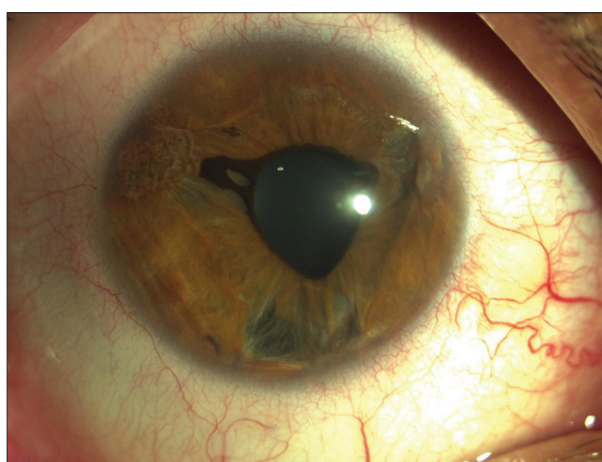
The rise of intraocular pressure (IOP) is caused by the closure of iridocorneal angle with peripheral anterior synechiae (PAS). Although corectopia and pulling of the iris stroma exists, function of iris sphincter remains preserved for a long time. Posterior synechiae do not develop and lens remains clear. Blood vessels are rarely seen in the areas of iris atrophy. Hyphaema does not occur. Progression of the disease can be monitored using confocal microscopy [3], and ultrasound biomicroscopy [4].

Chandler's syndrome, described by Chandler [5] in 1956, is the most common form of ICE syndrome. The most significant changes are in corneal endothelium and manifest with enhanced endothelial reflex of "hammered silver" appearance (Figure 3). Specular microscopy shows endothelial cells with irregular nonhexagonal shape and variable size, number and density. This type of cells is pathognomonic for ICE syndrome and these cells are named ICE cells. Iris atrophy is mild and confined to superficial stroma, while pigment epithelial layer remains intact. In the majority of cases, the pupil remains round and centrally positioned. Rarely, the pupil can be irregular, slightly displaced towards the area with most prominent PAS, with or without ectropion of pigment epithelial layer (Figure 4).

In iridocorneal angle, PAS are present in a lesser extent and angle is rarely blocked. If IOP rise occurs, it is moderately increased and glaucoma has better clinical



**Figure 5.** Cogan-Reese syndrome after trabeculectomy, without uveal ectropion



**Figure 6.** Cogan-Reese syndrome with uveal ectropion

course. Patients usually complain of blurred vision and color circles around the source of light due to the corneal edema, which can be present without significant IOP rise. Each patient has a particular critical value of IOP at which corneal edema occurs. In the evolution of the disease, this critical value gradually decreases, and sometimes it can be below the normal values of IOP.

Cogan-Reese (iris naevus) syndrome was described by Cogan and Reese [6] in 1969. The syndrome consists of unilateral nodular pigmented lesions with or without uveal ectropion (Figure 5 and 6) or diffuse pigmented iris lesions histologically similar to naevi, with variable degree of iris atrophy, PAS, abnormal Descemet-like membrane and loss of normal iris architecture [7, 8]. Iris surface is smooth, without crypts and concentric folds [9]. Heterochromia is typical and affected eye is usually darker. Microscopically, nodules are seen as islands of elevated, dense, pigmented stromal tissue, surrounded at the base by endothelium and Descemet's membrane. Corneal endotheliopathy is present in some areas. In iridocorneal angle, wide PAS are present, similar to those in progressive iris atrophy. Iris atrophy is usually absent, and in cases where it exists, it is mild. Corectopia is often present and can be severe, as well as uveal ectropion.

Transitional forms between progressive iris atrophy and Chandler's syndrome have been described. In those cases



**Table 1.** Frequency of secondary glaucoma in different forms of iridocorneal endothelial (ICE) syndrome, respective to the presence of uveal ectropion

Clinical forms of ICE syndromes	No. of patients	No. (%) of patients without uveal ectropion	No. (%) of patients with uveal ectropion	Total No. (%) of patients with sec. glaucoma	No. (%) of patients with sec. glaucoma without uveal ectropion	No (%) of patients with sec. glaucoma with uveal ectropion
Progressive iris atrophy	12	7 (58.3)	5 (41.7)	9 (75)	4 (57.1)	5 (100)
Chandler's syndrome	14	8 (57.1)	6 (42.9)	10 (71.4)	4 (50)	6 (100)
Cogan–Reese syndrome	10	7 (70)	3 (30)	7 (70)	4 (57.1)	3 (100)
Total	36	22 (61.1)	14 (38.9)	26 (72.2)	12 (54.6)	14 (100)

anterior segment optical coherence tomography findings may be decisive in final diagnosis [10].

We performed a study to analyze prevalence of secondary glaucoma in eyes with ICE syndrome with uveal ectropion, compared to those without uveal ectropion. We also analyzed the efficacy of medicament treatment in IOP management and the need for surgical treatment in both groups of patients.

## METHODS

We performed a prospective study of consecutive patients treated for ICE syndrome at Glaucoma Department of University Eye Clinic in Belgrade, Serbia. All patients underwent slit lamp examination, applanation tonometry, indirect gonioscopy, ophthalmoscopy, Humphrey visual field testing, and Heidelberg retina tomography (HRT) II. Iris specimens obtained after trabeculectomy were histologically analyzed. The patients were divided into the following two groups: group I, patients without uveal ectropion, and group II, patients with uveal ectropion.

The patients were clinically examined in six-month periods, while perimetry, photograph of the optic nerve head, HRT II, and indirect gonioscopy (that was used to monitor distribution and progression of PAS) were performed annually. If needed, anterior segment optical coherence tomography was performed. The difference in thickness between anterior limiting membrane and iris pigment epithelium was compared between the affected areas and healthy unaffected areas of the iris, and used to establish the diagnosis.

In order to control the secondary glaucoma, standard treatment included local administration of beta-blocking agents, carbonic anhydrase inhibitors, alfa-2 adrenergic agonists and prostaglandin agonists, as well as per oral use of carbonic anhydrase inhibitors. In cases in which goal IOP could not be achieved, surgical treatment was performed. Surgical intervention included trepanotrabeculectomy with intraoperative application of sponge soaked with mitomycin C, kept on the filtering site on the sclera for two minutes.

## RESULTS

In a 10-year period, 36 patients with ICE syndrome were treated. Out of them, 12 patients had progressive iris atrophy, 14 Chandler's syndrome, and 10 Cogan–Reese syndrome. All the patients had monocular disease. Women (24 patients, 66.6%) were affected twice as often as men

(12 patients, 33.3%). The average age of patients was 38 years. Out of 36 patients with ICE syndrome, secondary glaucoma was diagnosed in 26 (72.2%).

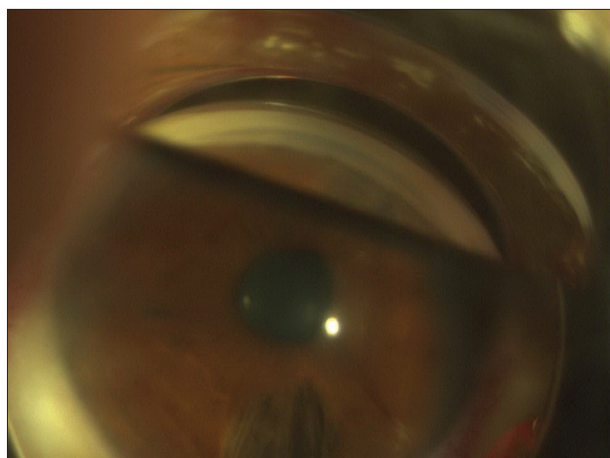
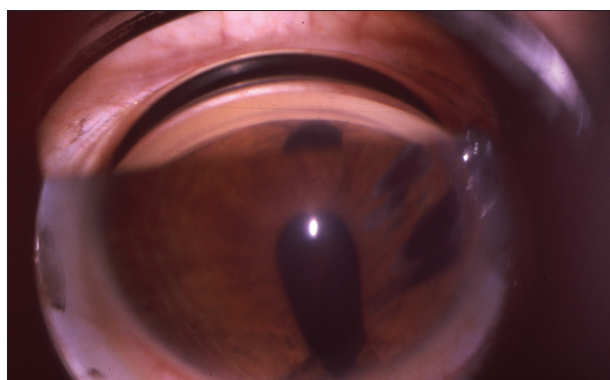
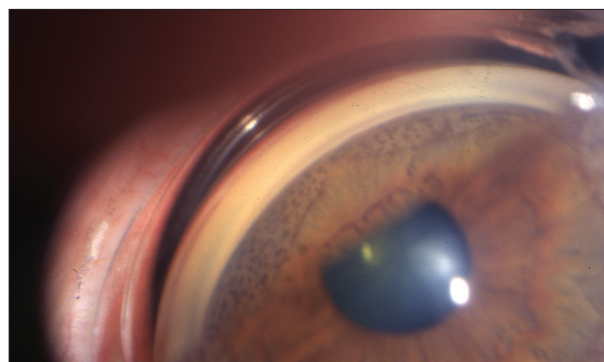
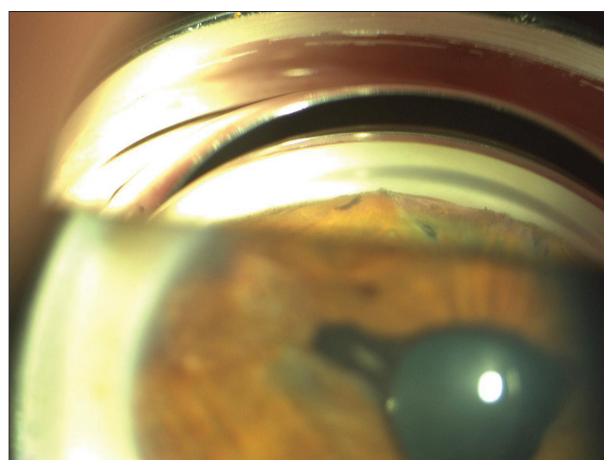
Group I comprised 22 patients (61.1%) without uveal ectropion, while group II consisted of 14 patients (38.9%) with uveal ectropion. In group I, secondary glaucoma was confirmed in 12 (54.5%) patients, while in group II this was the case in all 14 (100%) patients (Table 1). Out of 12 patients with progressive iris atrophy, secondary glaucoma was confirmed in nine (75%) of them. When patients with progressive iris atrophy were subdivided according to the presence of uveal ectropion, in group I, glaucoma was present in four (57.1%) out of seven patients, and in group II in all five patients (100%). Out of 14 patients with Chandler's syndrome, secondary glaucoma was confirmed in 10 (71.4%). When patients with Chandler's syndrome were subdivided according to the presence of uveal ectropion, in group I, glaucoma was present in four (50.0%) out of eight patients, and in group II in all six patients (100%). Out of 10 patients with Cogan–Reese syndrome, secondary glaucoma was confirmed in seven (70.0%) patients. When patients with Cogan–Reese syndrome were subdivided according to the presence of uveal ectropion, in group I, glaucoma was present in four (57.1%) out of seven patients, and in group II in all three patients (100%).

In group I, 12 (54.5%) out of 22 patients were diagnosed with secondary glaucoma. Mean IOP at baseline was 37 mmHg, and 26 mmHg after medicament treatment. Glaucoma was compensated in six (50%) patients, while in the remaining six, surgical treatment was necessary. After the procedure, glaucoma was compensated in four patients. Two patients were reoperated on and had neodymium-doped yttrium aluminium garnet (Nd:YAG) laser cyclophotocoagulation and cyclocriocanemization, after which IOP control was achieved.

In group II, all 14 (100%) patients with uveal ectropion had secondary glaucoma. Mean IOP at baseline was 49 mmHg, and after local medicament treatment it was 32 mmHg. Secondary glaucoma could not be controlled even with oral carbonic anhydrase inhibitors. All the patients underwent surgical procedure, after which target IOP was achieved in seven (50%) patients. In the remaining seven patients, additional surgical procedure was necessary (re-trabeculectomy with antimetabolite application) and was successful in four patients. In the remaining two patients, target IOP was reached after additional Nd:YAG laser cyclophotocoagulation or cyclocriocanemization. Enucleation had to be performed in one patient who had excruciating pain due to decompensated glaucoma.

**Table 2.** Iris changes in different clinical forms of ICE syndrome

Iris changes	Progressive iris atrophy		Chandler's syndrome		Cogan–Reese syndrome		Iris nevus syndrome	
	Without uveal ectropion	With uveal ectropion	Without uveal ectropion	With uveal ectropion	Without uveal ectropion	With uveal ectropion	Without uveal ectropion	With uveal ectropion
Uveal ectropion	7	5	8	6	5	2	2	1
Corectopia	4	5	4	6	4	2	2	1
Iris holes	7	5	0	0	0	0	0	0
Iris nodules or diffuse pigment lesion	0	0	0	0	4	3	2	1

**Figure 7.** Gonioscopy in progressive iris atrophy without uveal ectropion**Figure 8.** Gonioscopy in progressive iris atrophy with uveal ectropion**Figure 9.** Gonioscopy in Cogan–Reese syndrome without uveal ectropion**Figure 10.** Gonioscopy in Cogan–Reese syndrome with uveal ectropion

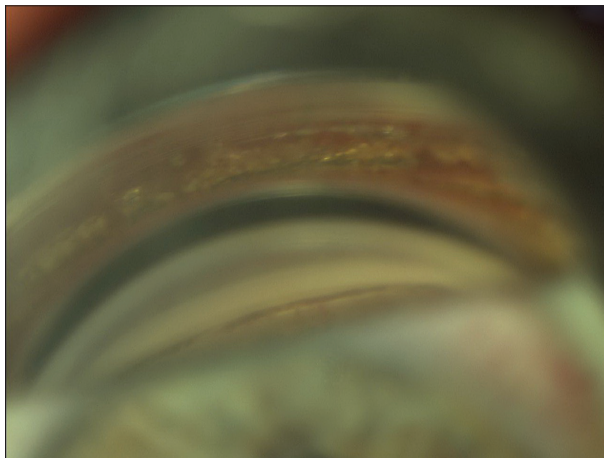
Out of 36 patients with ICE syndrome, 28 (77.7%) had corectopia. Uveal ectropion was partially present (in one part of pupillary margin) in 12 patients, and completely present (in the whole circumference) in two patients. In group II, all 14 patients had uveal ectropion associated with corectopia, while in group I, the condition was present in 14 out of 22 patients (Table 2).

PAS are the parameter that shows the progressive nature of the disease. Gonioscopy was performed in all cases on both eyes. In the healthy, unaffected eye, no PAS were found during the follow-up. However, in the eye with ICE syndrome, progression of the affected parts of iridocorneal angle with PAS was observed, especially in patients with progressive iris atrophy and uveal ectropion, in comparison to those without uveal ectropion (Figure 7 and 8). The progression of PAS was moderate in Cogan–Reese

syndrome (Figure 9 and 10). In Chandler's syndrome, PAS were not frequent and didn't progress as quickly and anteriorly as in progressive iris atrophy and Cogan–Reese syndrome (Figure 11 and 12).

Progression of PAS in group I was moderate, and after five years of follow-up, only four patients had PAS in three quadrants. In contrast, in group II, PAS were present in three or more quadrants of iridocorneal angle in nine patients, and those patients had a progression of secondary glaucoma and reduced effect of filtering surgery. The course of glaucoma was more severe in patients with progressive iris atrophy and Cogan–Reese syndrome, which could be explained by the fact that PAS are more frequent and more quickly formed (Table 3 and 4).

Histological analysis of iris samples of patients with progressive iris atrophy and Chandler's syndrome showed various degrees of iris stromal atrophy, which depended




**Figure 11.** Gonioscopy in Chandler's syndrome without uveal ectropion

on the area of iris sampling and involvement. Pigment nodules in patients with Cogan–Reese syndrome, had histological ultrastructure similar to the iris stroma and were surrounded with cellular membrane. Microscopically, nodules appeared as islands of elevated, dense, pigmented stromal tissue, surrounded at their base with endothelium and Descemet's membrane.

**DISCUSSION**

Although term “essential iris atrophy” was initially used for this group of disorders, clinical and pathohistological studies showed that primary disorder was corneal endothelial abnormality, rather than iris pathology [11]. This is why Yanoff [9] suggested the term ICE syndrome for this spectrum of diseases in 1979. Since iris atrophy was not the basic disorder, the term ‘progressive iris atrophy’ was found more suitable.

ICE syndrome is a rare, acquired disease that affects one eye of middle-aged patients. It has higher incidence in



**Figure 12.** Gonioscopy in Chandler's syndrome with uveal ectropion

females and has no genetic predisposition. Certain etiology of the disease is not known. Many possible factors such as congenital disorders, trauma, chronic inflammation, iris dystrophies, vascular insufficiency, and viral etiology were presumed [7, 12, 13]. For a long time, it was speculated that the disorder was caused by a congenital anomaly. However, very rare reports of family cases and histological evidence that endothelial and Descemet's membrane changes begin in the postnatal period do not support hereditary or congenital nature of the disease. In pathohistological specimens that were obtained after eight keratoplasties performed in eyes with ICE syndrome, Alvarodo et al. [14] found abnormal material in the posterior collagen layer of Descemet's membrane. These findings confirmed that ICE syndrome is an acquired rather than a congenital disorder, as all cases had normal pattern of membrane deposits. Shields [8] and Shields et al. [15] postulated that sudden appearance of abnormal posterior collagen layer is indirect evidence that an acute event has damaged the endothelium and that ICE syndrome is an acquired disorder, caused by the exogenous factor.

Findings made by Alvarodo et al. [14] and Rodrigues et al. [16] concerning lymphocyte infiltration in the endothelial layer indicate that the presence of chronic inflammation

**Table 3.** The distribution and progression of peripheral anterior synechiae in different forms of ICE syndrome without uveal ectropion during a five-year follow up

ICE sy. without uveal ectropion	Progressive iris atrophy					Chandler's syndrome					Cogan–Reese syndrome				
	1st year	2nd year	3rd year	4th year	5th year	1st year	2nd year	3rd year	4th year	5th year	1st year	2nd year	3rd year	4th year	5th year
Presence of PAS															
None	1	1	0	0	0	6	6	4	3	3	5	5	4	3	2
1 quadrant	5	4	4	3	2	2	2	3	4	2	2	2	1	2	2
2 quadrants	1	2	2	3	3	0	0	1	1	2	0	0	2	2	2
3 or 4 quadrants	0	0	1	1	2	0	0	0	0	1	0	0	0	0	1

**Table 4.** Distribution and progression of peripheral anterior synechiae in different forms of ICE syndrome with uveal ectropion during a five-year follow up

ICE sy. with uveal ectropion	Progressive iris atrophy					Chandler's syndrome					Cogan–Reese syndrome				
	1st year	2nd year	3rd year	4th year	5th year	1st year	2nd year	3rd year	4th year	5th year	1st year	2nd year	3rd year	4th year	5th year
Presence of PAS															
None	0	0	0	0	0	1	1	0	0	0	0	0	0	0	0
1 quadrant	3	2	1	0	0	3	2	3	2	0	2	2	1	1	0
2 quadrants	1	2	2	3	1	2	3	2	3	3	1	1	2	1	1
3 or 4 quadrants	1	1	2	2	4	0	0	1	1	3	0	0	0	1	2



could support the theory of viral etiology of the disease. However, rare lymphocytes are also seen in the corneal endothelium of patients with posterior polymorphous dystrophy; hence, they could be considered normal “passenger” cells, traveling towards the endothelium. Although the cause of the corneal endothelial abnormalities in ICE syndrome is not known, strong evidence exists that this is the main pathological event that leads to other clinico-pathological manifestations. Polymerase chain reaction demonstrated the presence of herpes simplex viral DNA in significant percentage of corneas with ICE syndrome, which suggests that this disease could be of viral etiology [17].

Pathogenesis of ICE syndrome is complex, and the “membrane theory” of Campbell et al. [18] is widely accepted. Endothelial abnormality does not only cause corneal edema, it also leads to proliferation of cellular membrane that consists of a single layer of endothelial cells and a membrane similar to Descemet’s membrane. According to this theory, contraction-retraction of the membrane causes the formation of PAS, iris changes, corectopia, ectropion of pigment layer, and secondary glaucoma. Iris pigment epithelium moves anteriorly due to the retraction of this membrane, covers the anterior surface of iris stroma, and causes pigment ectropion. Pigment ectropion can be present in all three clinical forms, although is most common in progressive iris atrophy and Cogan–Reese syndrome. It is always followed by corectopia, and those two findings are usually present in the quadrant with most prominent PAS. In the opposite quadrant, iris pulling is usually associated with iris thinning and, in some cases, iris holes. Along with membranous pulling of iris, other factors, such as secondary ischemia of the iris, are probably involved in the pathogenesis. In cases where the pupil is relatively central, its position and shape can be explained by the similar pulling forces from the opposite parts of iridocorneal angle by PAS.

Iris changes are the most significant clinical feature of progressive iris atrophy. At the onset of the disease, corneal endothelial changes are not so visible and are not associated with the development of corneal edema. Therefore, patients are asymptomatic for a long period of time. Symptoms occur after the change in pupil form or size, or after the onset of decompensated secondary glaucoma.

In Chandler’s syndrome corneal endothelial abnormality is the predominant clinical characteristic. Consequent corneal edema typically occurs when IOP is moderately raised or even normal. Electron microscopy of the corneal endothelium shows both regular hexagonal cells, with visible interdigitations that correspond to pyknotic vesicles and sporadic microvilli in the periphery, and degenerated endothelial cells that vary in size (polimegatism) and shape (polimorphism) [14, 16]. Their borders form zipper-like multilayers, with inner indentations and sporadic warty protuberances. Later on, cells aggregate, move apart, and deplete Descemet’s membrane, which leads to chronic corneal edema [19].

Contraction of the endothelial membrane over structures of anterior chamber angle and iris surface is most probably the cause of secondary glaucoma. Patel et al. [20]

have examined iris samples after trabeculectomy and corneal samples after keratoplasty using electron microscopy and concluded that both proliferation and degeneration of corneal endothelium were present in eyes with progressive iris atrophy and Cogan–Reese syndrome, while in Chandler’s syndrome those changes were not present.

Cogan–Reese syndrome has characteristic findings of nodular or diffuse pigment iris lesions and a variable degree of iris atrophy. Anterior border layer of iris is replaced with dense layer of melanocytes. Abnormal endothelial, glassy membrane in iridocorneal angle and on the anterior iris surface and confluent, peripheral PAS with secondary angle-closure glaucoma are characteristic for the disease. Corneal endotheliopathy is confined to certain areas of the cornea. Spreading of the corneal endothelium over iridocorneal angle and on the anterior iris surface with formation of new Descemet’s membrane seems to be the basic event in this condition. Nevus cells can stimulate spreading of the corneal endothelium [21]. Also, it is assumed that cellular membrane surrounds and pulls parts of the stoma to form nodular iris lesions [6, 22].

Changes in the iridocorneal angle include the formation of PAS, which usually start from or under Schwalbe’s line. Histological studies of iridocorneal angle confirm presence of cellular membrane, which consists of one layer of endothelial cells and membrane similar to the Descemet’s membrane, which grows from the periphery of the cornea. Membrane covers the open iridocorneal angle, or can be associated with the synechial angle closure [18, 22]. The synechial angle closure is typically progressive, leading to the IOP rise. However, secondary glaucoma does not correlate with the degree of synechial angle closure [23]. Obstruction of aqueous drainage is caused by either covering of the trabecular meshwork with membrane or synechial closure of iridocorneal angle [24, 25].

Occurrence of secondary glaucoma in the course of the disease requires medicament antiglaucomatous treatment, which consists of local administration of beta blockers, carbonic anhydrase inhibitors, alpha-2 agonists, and prostaglandin analogues. Surgical interventions based on fistulising procedures, have good results in the beginning, but usually shortly after the procedure closure of fistule with proliferated tissue and endothelial membranes occurs [26, 27]. In most of the cases re-treatment is needed with obligatory intraoperative administration of antimetabolites or usage of drainage implants, in order to prevent or delay cicatricial closure of the surgical aperture in the limbus or in the filtering bleb [28, 29, 30].

Nd:YAG laser cyclophotocoagulation and cyclocryotherapy are the final option for achieving the IOP control and their effect is usually time-limited, due to the progressive nature of the disease.

## CONCLUSION

Although ICE syndrome is a rare, acquired, benign, progressive disease, one must be cautious to timely diagnose and monitor secondary glaucoma, especially in cases with

uveal ectropion, since secondary glaucoma is twice as frequent in this group of patients. Secondary glaucoma is caused by wide and extensive angle closure with PAS and is characterized by poor response to medicament treat-

ment. All cases with uveal ectropion required surgical treatment (trabeculectomy with antimetabolite administration), in order to prevent irreversible glaucomatous optic neuropathy.

## REFERENCES

- Kontić D. Iridokorneoendotelijalni sindrom. In: Cvetković D, Kontić D, Hentova Senčanić P, eds. *Glaukom – dijagnoza i lečenje*. Beograd: Zavod za udžbenike i nastavna sredstva; 1996:301–4.
- Harms C. Einseitige spontane Luckenbildung der Iris durch Atrophie ohne mechanische Zerrung. *Klin Monbl Augenheilkd*. 1903; 41:522–8.
- Gračner T, Trpin S, Šarenac T, Pahor D. Diagnostic methods in the clinical evaluation of iridocorneal endothelial syndrome. *Der Ophthalmol*. 2016; 113(12):1074–7.
- Pezzi P, Marengo M, Cosimi P, Mannino G, Iannetti L. Progression of essential iris atrophy studied with confocal microscopy and ultrasound biomicroscopy: a 5-year case report. *Cornea*. 2009; 28(1):99–102.
- Chandler P. Atrophy of the stroma of the iris: Endothelial dystrophy, corneal edema and glaucoma. *Am J Ophthalmol*. 1956; 41(4):607–15.
- Cogan D, Reese A. A syndrome of iris nodules, ectopic Descemet's membrane and unilateral glaucoma. *Doc Ophthalmol*. 1969; 26:424–33.
- Kolker A, Hetherington J. Becker-Shaffer's diagnosis and therapy of the glaucomas. In: Becker-Shaffer's Diagnosis and Therapy of the Glaucomas. 5th ed. St. Louis: Mosby; 1983. p. 224–30, 275, 337.
- Shields M. Glaucoma associated with primary disorders of the corneal endothelium. In: Ritch R, Shields M, eds. *The Secondary Glaucomas*. St. Louis-Toronto-London: Mosby; 1982. p. 69–83.
- Yanoff M. Iris nevus syndrome (Cogan-Reese syndrome). In: Fraunfelder F, Roy F, eds. *Current Ocular Therapy*. Philadelphia: WB Saunders Company; 1980. p. 479–80.
- Hollo G, Naghizadeh F. Optical coherence tomography characteristics of the iris in Cogan-Reese syndrome. *Eur J Ophthalmol*. 2014; 24(5):797–9.
- Bromley JG, Randleman JB, Stone D, Stulting RD, Grossniklaus HE. Clinicopathologic Findings in Iridocorneal Endothelial Syndrome and Posterior Polymorphous Membranous Dystrophy After Descemet Stripping Automated Endothelial Keratoplasty. *Cornea*. 2012; 31(9):1060–4.
- Joko T, Suzuki T, Inoue T, Kikuchi M, Hara Y, Shiraishi A, et al. Coincidence of varicella-zoster virus anterior uveitis in a patient with chandler's syndrome. *Case Rep Ophthalmol*. 2013; 4(3):274–8.
- Robert A, Renard G, Robert L, Bourges J. The irido-corneo-endothelial syndrome. The loss of the control of corneal endothelial cell cycle. A review. *Pathol Biol (Paris)*. 2013; 61(2):75–82.
- Alvarado J, Murphy C, Jusser R, Herheringron J. Pathogenesis of Chandler's syndrome, essential iris atrophy and the Cogan-Reese syndrome. *Invest Ophthalmol Vis Sci*. 1986; 27(6):853–72.
- Shields C, Shields M, Vilorio V, Pearlstein H, Say E, Shields J. Iridocorneal endothelial syndrome masquerading as iris melanoma in 71 cases. *Arch Ophthalmol*. 2011; 129(8):1023–29.
- Rodrigues MM, Phelps CD, Krachmer JH, Cibis GW, Weingeist TA. Glaucoma due to endothelialization of the anterior chamber angle. A comparison of posterior polymorphous dystrophy of the cornea and Chandler's syndrome. *Arch Ophthalmol*. 1980; 98(4):688–96.
- Kanski J. Iridocorneal endothelial syndrome. In: *Clinical Ophthalmology: A Systematic Approach*. 5th ed. Philadelphia: Butterworth-Heinemann; 2003:241–3.
- Campbell D, Shields M, Smith T. The corneal endothelium and the spectrum of essential iris atrophy. *Am J Ophthalmol*. 1978; 86(3):317–24.
- Wilson M, Shields M. A comparison of the clinical variations of the iridocorneal endothelial syndrome. *Arch Ophthalmol*. 1989; 107(10):1465–8.
- Patel A, Kenyon KR, Hirst LW, Quigley HA, Stark WJ, Meyer RF, et al. Clinicopathologic features of Chandler's syndrome. *Surv Ophthalmol*. 1983; 27(5):327–44.
- Scheie H, Yanoff M. Iris Nevus (Cogan-Reese) Syndrome: A Cause of Unilateral Glaucoma. *Arch Ophthalmol*. 1975; 93:963–70.
- Eagle R, Font R, Yanoff M, Fine B. Proliferative endotheliopathy with iris abnormalities. The iridocorneal endothelial syndrome. *Arch Ophthalmol*. 1979; 97(11):2104–11.
- Shields M, Campbell D, Simmons R. The essential iris atrophies. *Am J Ophthalmol*. 1978; 85(6):749–59.
- Shields M. Axenfeld-Rieger syndrome: a theory of mechanism and distinctions from the iridocorneal endothelial syndrome. *Trans Am Ophthalmol Soc*. 1983; 81:736–84.
- Herde J. Iridocorneal endothelial syndrome (ICE-S): Classification, clinical picture, diagnosis. *Klin Monbl Augenheilkd*. 2005; 222(10):797–801.
- Ninios K, Jonescu-Cuypers CP, Seitz B. Glaucoma with primary iris malformations. Axenfeld-Rieger syndromes, ICE syndromes (essential iris atrophy, Chandler's syndrome, Cogan-Reese syndrome), Aniridia. *Der Ophthalmol*. 2011; 108(6):585–94.
- Salim S, Netland P. Iridocorneal endothelial syndrome and glaucoma. In: *Clinical Glaucoma Care: The Essentials*.; 2014:391–3.
- Jain VK. Trabeculectomy with Mitomycin-C in patients with iridocorneal endothelial syndrome: A case series. *J Clin Diagnostic Res*. 2016; 10(5):5–6.
- Sacchetti M, Mantelli F, Marengo M, Macchi I, Ambrosio O, Rama P. Diagnosis and Management of Iridocorneal Endothelial Syndrome. *Biomed Res Int*. 2015; 2015:763093.
- Cvetković D. Trabekuloiridokornealne disgeneze. In: Cvetković D, Kontić D, Hentova Senčanić P, eds. *Glaukom – dijagnoza i lečenje*. Beograd: Zavod za udžbenike i nastavna sredstva; 1996:236–9.

## Заступљеност секундарног глаукома у иридокорнеалном ендотелијалном синдрому у зависности од присуства ектропијума увеје

Вујица Марковић<sup>1,2</sup>, Александра Радосављевић<sup>1,2</sup>, Драган Вуковић<sup>1,2</sup>, Весна Јакшић<sup>1,3</sup>, Марија Божић<sup>1,2</sup>, Иван Марјановић<sup>1,2</sup>, Дејан Рашић<sup>1,2</sup>, Весна Марић<sup>2</sup>

<sup>1</sup>Универзитет у Београду, Медицински факултет, Београд, Србија;

<sup>2</sup>Клинички центар Србије, Клиника за очне болести, Београд, Србија;

<sup>3</sup>Клиничко-болнички центар Звездара, Клиника за очне болести, „Проф. др И. Станковић“, Београд, Србија

### САЖЕТАК

**Увод/Циљ** Иридокорнеални ендотелијални (ИКЕ) синдром обухвата три клиничка облика: прогресивну атрофију дужице, Чандлеров синдром и Коган–Рисов синдром. Одликује се различитим степеном атрофије дужице, промена на ендотелу рожњаче, ектропијума увеје, коректопије, присуства периферних предњих синехија (ППС) и секундарног глаукома. Циљ рада је да прикаже форме ИКЕ синдрома, утврди учесталост секундарног глаукома, посебно са ектропијумом увеје, и испита одговор на медикаментну терапију и потребу за хируршким третманом у контроли интраокуларног притиска (ИОП).

**Методe** Прегледи болесника обухватили су биомикроскопски преглед, апланациону тонометрију, гониоскопију, офталмоскопију, компјутеризовану периметрију, Хеиделберг-ретина томографију. Болесници су подељени у две групе: група I – без ектропијума увеје (22 болесника) и група II – са ектропијумом увеје (14 болесника).

**Резултати** У десетогодишњем периоду праћено је 36 болесника. Просечна старост је износила 38 година, а однос

мушког и женског пола био је 1 : 2. Секундарни глауком је потврђен код 26 (72,2%) болесника и то у групи I код 12 (54,5%), и у групи II код 14 (100%) болесника. ППС су чешће постојале у групи II. У групи I просечна почетна вредност ИОП-а износила је 37 *mmHg*, а након медикаментне терапије 26 *mmHg*. Секундарни глауком је компензован медикаментном терапијом код 50%, а код преосталих 50% је спроведен хируршки третман. У групи II просечна почетна вредност ИОП-а износила је 49 *mmHg*, а након медикаментне терапије 32 *mmHg*. Код свих 14 (100%) болесника спроведен је хируршки третман у контроли ИОП-а.

**Закључак** ИКЕ синдром је ретко прогресивно обољење. Учесталост секундарног глаукома је висока, и два пута већа код случајева са ектропијумом увеје. Код ових болесника медикаментна терапија је неефикасна, те је неопходан хируршки третман.

**Кључне речи:** ИКЕ синдром; секундарни глауком; ектропијум увеје