



ORIGINAL ARTICLE / ОРИГИНАЛНИ РАД

Social, clinical, and radiological characteristics of physical abuse of children under three years of age hospitalized in a tertiary health institution

Goran Đuričić¹, Zorica Milošević^{2,3}, Đorđe Alempijević^{3,4}, Vladimir Radlović¹, Raša Medović⁵, Siniša Dučić^{1,3}, Zoran Golubović^{1,3}

¹University Children's Hospital, Belgrade, Serbia;

²Institute of Oncology and Radiology of Serbia, Belgrade, Serbia;

³University of Belgrade, Faculty of Medicine, Belgrade, Serbia;

⁴Institute of Forensic Medicine, Belgrade, Serbia;

⁵Clinical Centre of Kragujevac, Pediatric Clinic, Serbia

SUMMARY

Introduction/Objective Child abuse is a significant public health problem in modern society. Many cases of violence against children remain undetected. Serbia has no official protocols for medical examination of abused children.

The aim of the study is an analysis of the social, clinical and radiological characteristics of physical abuse of children under three years of age that required hospital treatment.

Methods This retrospective study included 98 physically injured children admitted to the University Children's Hospital in the period from 2013 to 2015, with suspected physical abuse. In addition to the history of injuries, complete clinical examinations and standard laboratory analyses were performed in all children, as well as X-ray examination in children with apparent or suspected skeletal injury. Ultrasound examination and computerized tomography or magnetic resonance imaging were performed in selected patients. Final diagnosis of abuse was established by multidisciplinary assessment team. The children were divided into two groups – those with proven and those with suspected abuse.

Results Most of 98 children who were suspected of being abused (92%) were from one or both unemployed parents, 68% were male, 60% were first-born, and 44% younger than one year. Ninety-two percent of the children had skeletal fractures, 19% of whom had two or more fractures. The commonest fracture was a linear skull fracture, which was detected in 51% of the cases. Abuse was confirmed in only five of 98 suspected cases.

Conclusion Among the known social risk factors for abuse of children, the low economic status of the family was the most frequent one in our analyzed sample. The most common injury is a linear skull fracture. A national guideline for medical investigating of abused children is required.

Keywords: child abuse; children under three years; bone fractures

INTRODUCTION

Child abuse is a significant public health problem in modern society. Unfortunately, many cases of violence against children remain undetected [1, 2]. Several risk factors are associated with child abuse – parents younger than 20 years, lower socioeconomic status, separated parents, history of mental illness, alcohol and drug abuse. Abused children are more often male, unwanted children with developmental delay or chronic disease [1, 2, 3].

Fractures are the second most frequent manifestation of physical abuse, preceded only by skin lesions (bruises, contusions) [4, 5]. Fractures are usually multiple and may occur in any bone in the skeleton [4]. The evident cases of abuse are those that have occurred in the presence of witnesses or if there has been a confession. All other cases that raise the suspicion of abuse (age younger than 18 months, signs of fracture healing, unknown or inconsistent history of injury mechanism, and presence of

other injuries) require material evidence specific to the identified injury [2, 4, 6–10].

Radiological investigations should include a high quality skeletal survey, while brain computed tomography (CT) and/or magnetic resonance imaging (MRI) are mandatory in children younger than two years and in older children with neurological signs/symptoms. The use of abdominal imaging, including ultrasonography (US), CT and/or MRI is debatable if the child has no symptoms [4, 6, 8, 9, 10].

In Serbia there are papers on forensic and psychiatric aspects of child abuse [11, 12], but with no mention of radiological investigations. Serbia does not have an official protocol that defines standards for performing skeletal surveys on children in whom physical abuse is suspected. The results of this study will highlight significant epidemiological factors associated with child abuse, and provide an overview of the radiological standards for diagnosis of child abuse in Serbia. Given the recent Europe-wide adoption of the Royal College of Radiology / Royal College

Примљено • Received:
September 27, 2016

Ревизија • Revised:
February 9, 2017

Прихваћено • Accepted:
March 7, 2017

Online first: March 21, 2017

Correspondence to:

Goran ĐURIČIĆ
Tiršova 10, 11000 Belgrade,
University Children's Hospital,
Belgrade, Serbia
gorandjuricic@gmail.com

of Pediatrics and Child Health (RCR/RCPCCH) guidelines for investigating child abuse, results will also act as a baseline comparator for future similar studies [13, 14].

The aim of this study was to analyze the social, clinical, and radiological characteristics of physical abuse of children under three years of age that required hospital treatment.

METHODS

The data for this retrospective observational study were extracted from the medical records of 98 children younger than three years admitted to the University Children's Hospital in Belgrade in the period from 2013 to 2015 because of suspected physical abuse.

In addition to the history of injuries, complete clinical examination and standard laboratory analyses were performed in all children with suspected physical abuse, as well as X-ray examination in children with apparent or suspected skeletal injury. US, CT, or MRI examinations were performed in selected patients (Table 1 and 2). Final diagnosis of abuse was established by multidisciplinary assessment team. Children were divided into two groups – those with proven and those with suspected abuse. We defined the proven abuse cases with medical records agreed by the professionals involved, such as the signs of previously medically untreated fractures, unknown or inconsistent history of mechanism of injury in the presence of unexplained fractures on skeletal survey, the presence of injuries other than the presenting injury, especially if injuries were those specific for abuse, plus presence of at least two of the following criteria: admission of assault, presence of witnesses, involvement of police or social services, and legal outcome. We defined the suspected abuse as cases with inconsistent history of mechanism of injury, discrepancies between the extent of an injury and the reported mechanism of injury, estimated by a physician. Also, presence of the risk factors in parents that rise suspicion for child abuse were taken into account, such as parents younger than 20 years, lower socioeconomic status, separated parents, history of mental illness, alcohol and drug abuse.

Based on information provided by parents or the person who had brought the child to the hospital, we recorded the age, education, employment of parents or main occupation, marital status of parents, number of children and family members in total, guardianship of children, and mechanism of injury. In relation to findings from the physical examination, we recorded the presence of other visible non-skeletal injuries (bruises, lacerations, contusions, burns, abrasions, evidence of pinching) and presence of chronic disease or birth defect of children.

According to the radiographic signs of fracture, our patients were divided into the following three groups: patients with fractures described in the literature as highly specific for abuse (posterior and lateral rib fractures, metaphyseal fractures and long bone fractures in non-walking age, scapular fracture, spinous process fracture, multiple "eggshell" skull fractures, occipital impression fracture),

Table 1. Skeletal surveys performed according to RCR/RCPCCH guidelines

Radiographic projection	Number of children (n = 98)	
	Proven abuse	Suspected abuse
Skull (frontal and lateral)*	5	67
Thorax (AP)	5	38
Right and left oblique views of the chest	4	29
Abdomen (pelvis and hip) (AP)	0	2
Lumbosacral and cervical spine (lateral)	1	7
Both upper arms (AP)	0	7
Both forearms (AP)	1	14
Both femurs (AP)	1	11
Both lower legs (AP)	1	12
Hands (PA)	0	4
Feet (DP)	0	4
Follow-up survey	0	2

*Towne view – one child with proven abuse, four children with suspected abuse

RCR – Royal College of Radiologists; RCPCCH – Royal College of Paediatrics and Child Health; AP – anteroposterior; PA – posteroanterior; DP – dorsal-plantar

Table 2. The frequency of use of additional diagnostic methods

Additional examination	Abdomen	Brain	Other*
Computed tomography (CT)	2	42	7
Magnetic resonance imaging (MRI)	0	19	1
Ultrasonography (US)	47	61	11

* CT of spine in five and upper leg in two cases, MRI of spine in one case, US of soft tissue in seven, and testicles in four cases

patients with moderately specific fractures (multiple fractures, epiphyseal separation, vertebral body fracture, complex skull fracture), and patients with fractures of low specificity for abuse (clavicular fracture, oblique and spiral shaft fracture of long bones, linear skull fracture) [4].

Cases with skeletal dysplasia or other bone disease, as well as those with traffic trauma, were not included in this study.

RESULTS

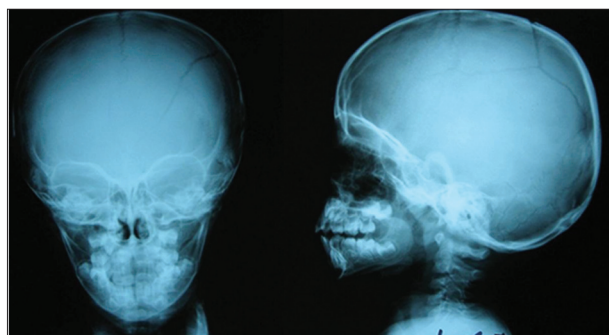
Most of 98 children who were suspected of being abused (92%) were from one or both unemployed parents, 68% were male, 60% the first-born and 44% younger than one year. Education beyond secondary school was obtained by 7% of parents, and 16% were up to 20 years old. Most parents (96%) were married. There were 40 children aged up to 12 months, 28 children aged 12 to 24 months, and 30 children aged 24 to 36 months. Skeletal fractures were found in 92% of the children, 19% of whom had two or more fractures (Table 3 and 4). The most common fracture was a linear skull fracture, which was detected in 51% of the cases. Additional injuries distant to the site of fracture were identified in 70% of the children. The physical abuse was undoubtedly proven in five (5%) out of 98 suspected cases, one in the age group of up to 12 months, one in the 12–24-month age group, and three cases in the 24–36 months age group, all of whom with craniocerebral injuries. In these cases, the perpetrator of abuse was dis-

Table 3. Distribution of fractures

Fracture type/site – number of fractures (n = 90)								
Skull			Long bone				Clavicle	Digit
Linear	Complex	Total	Diaphyseal	Metaphyseal	Epiphyseal	Total	3 (3%)	1 (1%)
46 (51%)	5 (6%)	51 (57%)	34 (38%)	0	1 (1%)	35 (39%)		

Table 4. Distribution of fractures by age

Fracture type/site Number of fractures (n = 90)	Age group		
	0–12 months	12–24 months	24–36 months
Skull	27 (77%)	16 (57%)	8 (30%)
Long bone	5 (14%)	11 (39%)	19 (70%)
Clavicle	3 (9%)	0 (/)	0 (/)
Digit	0 (/)	1 (4%)	0 (/)
Total	35 (100%)	28 (100)	27 (100%)

**Figure 1.** X-ray of the head of a 26-month-old boy injured with multilinear left fronto-parieto-occipital fracture

covered, and all of these children were hospitalized at the Department of Neurosurgery. Figure 1 shows the X-ray appearance of skull fractures in one of them.

DISCUSSION

Our results indicate that physical abuse of children younger than three years was undoubtedly confirmed in only 5% of 98 suspected cases. This is relatively low compared to other reports because there was no consistent approach to the investigation of these children [15–19].

According to our data, physical abuse is twofold more frequent in males. Numerous studies indicate that maltreatment of children most frequently occurs in families with lower economic status and education [1, 2, 3, 20], which was confirmed in our research. In our group of patients, only 3% of parents were educated beyond secondary school and only 7% of them were both employed. While the majority of parents were married, they were in their early twenties. Although there are scarce data in the literature related to birth order and child abuse, most cases in our study were first-born. All of these suggest that parental immaturity, lack of experience, and financial difficulties may be instrumental in the causation of abuse.

Unfortunately, we were unable to record data on the psychiatric disorders, confirmed use of alcohol and/or drugs or previous abuse in the families. This information

should be included in future studies, since it will contribute to a more complete picture of the problem [20].

Large studies cite unknown or inconsistent history of mechanism of injury as a major indicator of abuse [1, 2, 3, 15–20]. In most of our cases, the mechanism of injury was either unknown or it was stated to be self-injury. Non-ambulant children are unable to self-inflict or independently sustain accidental injury. In older children, who walk and play independently, there is a greater probability of accidental injury, but they may also be abused and there is no single fracture that is an absolutely certain diagnostic sign of abuse. Therefore, the diagnostic dilemma of differentiating intentionally inflicted from accidental injury is always present.

The third major indicator of child abuse is the presence of visible soft tissue injuries (bruises, abrasions, lacerations), especially if they are present in several regions of the body in non-ambulant children or over non-bony sites (i. e. cheeks, buttocks or thighs), if they vary by date or have typical appearance suggestive for abuse (handprint, pinch, and tramline bruises, cord or belt buckle marks, bites) [1, 2, 3, 5, 15–20]. Upper lip frenulum tear and ear contusions are highly suggestive for child abuse. Burns and scald injuries should draw attention if they have appearance suggestive for intentional trauma (i.e. cigarette burns, immersion scald injuries with sharp demarcation and/or “stocking or glove” type distribution). Such lesions were observed in 70% of our patients with suspected and in all children with proven abuse.

Radiographs demonstrated at least one fracture in 92% of our patients. Unsuspected fractures were detected in 17%. This is slightly lower than in the study by Barber et al. [17], who reported that previously unsuspected fractures were noted on skeletal survey in 21% of their cases. However, it must be emphasized that their research referred only to infants and that they adhered to a standardized imaging protocol.

Almost 20% of our examined children had more than one fracture and this is an important clinical warning of possible physical abuse. This is similar to the findings of Karmazyn et al. [18], who proved multiple fractures in 18% of their cases. It is interesting that 91% of the patients had low-specificity and the remainder moderate-specificity fractures.

In the Barber’s study, 14% of children had rib and 4.6% uncommon fractures, which can be considered highly specific [17]. Our lack of identification of high-specificity fractures may be mostly due to the low number of full skeletal surveys performed. Also, in only 2% of the cases there was a follow-up skeletal survey. This is even lower than the 14% and 8.5% reported by Sonik et al. [21] and Bennett et al. [22], respectively. Clearly, there is room for

significant improvement in the quality of imaging performed in Serbia.

In this study, 57% of the children had skull fracture and 39% of the children had long bone fracture. Skull fractures were the most common in the two younger age groups, with a note that the number of long bone fractures increased with age, presumably associated with the more active lifestyles in older children. Other authors identified more long bone fractures than skull fractures in their researches. Taitz et al. [15] verified long bone fractures in 65% and skull fractures in 24% of cases, Carty and Pierce [23] 62% and 27%, and Karmazyn et al. [18] 21% and 7% of cases.

Our study demonstrates that child abuse is a very serious problem that requires a multidisciplinary approach including police, court, and social services, as well as the creation of a national guideline for investigating these children. Following medical care, a safe permanent residence is required in order to protect the child from potentially repeated violence [20].

REFERENCES

- Schnitzer PG, Ewigman BG. Child deaths resulting from inflicted injuries: household risk factors and perpetrator characteristics. *Pediatrics*. 2005; 116(5):e687–e93.
- Hobbs CJ, Bilo RA. Nonaccidental trauma: clinical aspects and epidemiology of child abuse. *Pediatr Radiol*. 2009; 39(5):457–60.
- Deans KJ, Thackeray J, Groner JI, Cooper JN, Minneci PC. Risk factors for recurrent injuries in victims of suspected non-accidental trauma: a retrospective cohort study. *BMC Pediatr*. 2014; 14:217.
- Offiah A, van Rijn RR, Perez-Rossello JM, Kleinman PK. Skeletal imaging of child abuse (non-accidental injury). *Pediatr Radiol*. 2009; 39(5):461–70.
- Wood JN, Fakeye O, Mondestin V, Rubin DM, Localio R, Feudtner C. Development of hospital-based guidelines for skeletal survey in young children with bruises. *Pediatrics*. 2015; 135(2):e312–20.
- Adamsbaum C, Méjean N, Merzoug V, Rey-Salmon C. How to explore and report children with suspected non-accidental trauma. *Pediatr Radiol*. 2010; 40(6):932–8.
- Friedman LS, Sheppard S, Friedman D. A retrospective cohort study of suspected child maltreatment cases resulting in hospitalization. *Injury*. 2012; 43(11):1881–7.
- Van Rijn RR. How should we image skeletal injuries in child abuse? *Pediatr Radiol*. 2009; 39 Suppl 2:S226–S229.
- Erfurt C, Hahn G, Roesner D, Schmidt U. Pediatric radiological diagnostic procedures in cases of suspected child abuse. *Forensic Sci Med Pathol*. 2011; 7(1):65–74.
- Phillips KL, Bastin ST, Davies-Payne D, Browne D, Bird HL, Craw S, et al. Radiographic skeletal survey for non-accidental injury: systematic review and development of a national New Zealand protocol. *J Med Imaging Radiat Oncol*. 2015; 59(1):54–65.
- Baralic I, Savic S, Alempijevic DM, Jecmenica DS, Sbutega-Milosevic G, Obradovic M. Child homicide on the territory of Belgrade. *Child Abuse Negl*. 2010; 34(12):935–42.
- Pejovic-Milovancevic M, Mitkovic-Voncina M, Lecic-Tosevski D. Past, present, and future steps in child abuse and neglect issues: the Serbian journey. *Eur Child Adolesc Psychiatry*. 2015; 24(1):121–4.
- Offiah AC, Adamsbaum C, van Rijn RR. ESPR adopts British guidelines for imaging in suspected non-accidental injury as the European standard. *Pediatr Radiol*. 2014; 44:1338.
- Standards for Radiological Investigations of Suspected Non-accidental Injury – March 2008. Intercollegiate Report from the Royal College of Radiologists and Royal College of Paediatrics and Child Health. London: Royal College of Paediatrics and Child Health; 2008. p. 1–56. Accessed July 2015. Available from: https://www.rcr.ac.uk/docs/radiology/pdf/RCPCCH_RCR_final.pdf
- Taitz J, Moran K, O'Meara M. Long bone fractures in children under 3 years of age: is abuse being missed in Emergency Department presentations? *J Paediatr Child Health*. 2004; 40(4):170–4.
- Day F, Clegg S, McPhillips M, Mok J. A retrospective case series of skeletal surveys in children with suspected non-accidental injury. *J Clin Forensic Med*. 2006; 13(2):55–9.
- Barber I, Perez-Rossello JM, Wilson CR, Kleinman PK. The yield of high-detail radiographic skeletal surveys in suspected infant abuse. *Pediatr Radiol*. 2015; 45(1):69–80.
- Karmazyn B, Lewis ME, Jennings SG, Hibbard RA, Hicks RA. The prevalence of uncommon fractures on skeletal surveys performed to evaluate for suspected abuse in 930 children: should practice guidelines change? *AJR Am J Roentgenol*. 2011; 197(1):W159–W163.
- Gera SK, Raveendran R, Mahadev A. Pattern of fractures in non-accidental injuries in the paediatric population in Singapore. *Clin Orthop Surg*. 2014; 6(4):432–8.
- Ben-Arieh A. Community characteristics, social service allocation, and child maltreatment reporting. *Child Abuse Negl*. 2015; 41:136–45.
- Sonik A, Stein-Wexler R, Rogers KK, Coulter KP, Wootton-Gorges SL. Follow-up skeletal surveys for suspected non-accidental trauma: can a more limited survey be performed without compromising diagnostic information? *Child Abuse Negl*. 2010; 34(10):804–6.
- Bennett BL, Chua MS, Care M, Kachelmeyer A, Mahabee-Gittens M. Retrospective review to determine the utility of follow-up skeletal surveys in child abuse evaluations when the initial skeletal survey is normal. *BMC Res Notes*. 2011; 4:354.
- Carty H, Pierce A. Non-accidental injury: a retrospective analysis of a large cohort. *Eur Radiol*. 2002; 12(12):2919–25.

CONCLUSION

Child abuse is a significant public health problem in Serbia that requires immediate creation of a national guideline for medical investigation of these children and multi-disciplinary approach for its solution. In most cases, the perpetrator of violence against children under three years of age remains unknown. Among the known social risk factors for the abuse of children, the most frequent one in the analyzed sample was low economic status of the family. More exposed to abuse in this age are males, firstborn, and those originating from parents with medium and low levels of education. Injuries in physically abused children at this age are very different. The most common and most serious injury is a linear skull fracture. Health professionals of all profiles should be aware of suggestive signs for child abuse. Child abuse prevention and early recognition should be emphasized, especially in suspected but not proven cases, in order to prevent further victim suffering.

Социјалне, клиничке и радиолошке карактеристике физичког злостављања деце узраста до три године хоспитализоване у терцијарној здравственој установи

Горан Ђуричић¹, Зорица Милошевић^{2,3}, Ђорђе Алемпијевић^{3,4}, Владимир Радловић¹, Раша Медовић⁵, Синиша Дучић^{1,3}, Зоран Голубовић^{1,3}

¹Универзитетска дечја клиника, Београд, Србија;

²Институт за онкологију и радиологију Србије, Београд, Србија;

³Универзитет у Београду, Медицински факултет, Београд, Србија;

⁴Институт за судску медицину, Београд, Србија;

⁵Клинички центар, Педијатријска клиника, Крагујевац, Србија

САЖЕТАК

Увод/Циљ Злостављање деце је значајан јавноздравствени проблем савременог света. Многи случајеви насиља над децом остају неоткривени. Србија нема званичне протоколе за медицинско испитивање злостављане деце.

Циљ рада је анализа социјалних, клиничких и радиолошких карактеристика физичког злостављања деце узраста до три године која су хоспитално лечена.

Методе У ретроспективну опсервациону студију укључено је 98 физички повређене деце са сумњом на физичко злостављање, хоспитализоване на Универзитетској дечјој клиници у периоду 2013–2015. године. Код све деце су урађени анамнеза, клинички преглед, стандардне лабораторијске анализе, а радиографско испитивање је урађено код деце са очигледном или суспектном повредом скелета. Код поједине деце урађени су ултразвучни преглед, компјутеризована томографија и магнетна резонанца. Завршну дијагнозу злостављања је постављао мултидисциплинарни тим. Деца су подељена у две групе: са доказаним и суспектним физичким злостављањем.

Резултати Већина деце (92%) из породица су са једним или оба незапослена родитеља. Мушког пола је 68%, прворођењих је 60% и 44% је млађе од годину дана. Прелом костију је имало 92% деце, од чега 19% два или више прелома. Најчешћи прелом је била линеарна фрактура лобање и то код 51% деце. Злостављање је потврђено само код пет од 98 сумњивих случајева.

Закључак У анализираном узорку низак економски статус породице је био најчешћи социјални фактор ризика за злостављање деце. Најчешћа повреда је линеарна фрактура лобање.

Кључне речи: злостављање деце; деца узраста до три године; преломи костију