

Reconstruction of Full Thickness Abdominal Wall Defect Following Tumor Resection: A Case Report

Predrag Kovačević^{1,2}, Asen V. Veličkov¹, Danilo Stojiljković^{1,2}, Aleksandra I. Veličkov¹, Zoran Čeranić³

¹Medical Faculty, University of Niš, Niš, Serbia;

²Clinic of Plastic and Reconstructive Surgery, Clinical Center, Niš, Serbia;

³General Hospital, Leskovac, Serbia

SUMMARY

Introduction Reconstruction of a full thickness abdominal wall defect is a demanding procedure for general and also for plastic surgeons, requiring vigorous planning and reconstruction of three layers.

Case Outline We present a case of a 70-year-old patient with a huge abdominal wall tumor with 40 years evolution. Surgery was performed under general anesthesia. Full thickness abdominal defect appeared after the tumor resection. Reconstruction followed in the same act. The defect was reconstructed using a combination of techniques, including omental flap, fascia lata graft, local skin flaps and skin grafts. After surgery no major complications were noted, only a partial skin flap loss, which was repaired using partial thickness skin grafts. The final result was described by the patient as very good, without hernia formation.

Conclusion Omentoplasty, abdominal wall reconstruction in combination with free fascia lata graft and skin grafts can be one of good options for the reconstruction of full thickness abdominal wall defects.

Keywords: abdominal wall reconstruction; abdominal wall resection; skin cancer

INTRODUCTION

The reconstruction of full thickness abdominal defect is of great significance for patient recovery. Because of the complex and unique musculofascial system it is not easy to maintain the functional integrity of the anterior abdominal wall after resection. The integrity can be compromised by previous surgery, tumor resection or trauma. Vigorous planning is demanded depending on the etiology, location, size and extent of the defect. Besides the structural integrity the esthetic appearance is nowadays also a significant issue both for the patients and for the surgeon [1]. A variety of reconstructive options are available, such as skin grafts, free fascia grafts, component separation technique, tissue expansion, regional flaps, free flaps, synthetic/biologic mesh repair, pedicled omental flap and split skin graft [2]. Although there are several options for reconstruction, each of them is potentially followed by complications. We present a case of full thickness abdominal wall defect reconstruction following tumor resection using a combination of techniques.

CASE REPORT

A 70-year-old patient was admitted to our Clinic for elective surgery of a giant mixed basal/squamous cell carcinoma of the abdominal wall. The tumor appeared 40 years ago and it was not previously treated. It presented as exulcerated tumor 17×15 cm, infiltrating abdominal wall, bleeding when touched and smelly (Figure 1). Surrounding skin was hyperemic. On CT scan the infiltration deep to the peri-

toneum was found. After the diagnostic procedures, surgery under general anesthesia was performed. The tumor was excised, according to the oncological rule for 2 cm healthy margin, en bloc removing the surrounding skin and underlying the rectus abdominis muscles, lateral muscles of anterior abdominal wall, deep fascia and parietal peritoneum (Figure 2). The involvement of intra-abdominal organs was not detected. Following the excision, a pedicled great omental flap was raised to reconstruct the parietal peritoneum (Figure 3). Next, a fascia lata graft was harvested from the left thigh and sutured to the superficial abdominal fascia in order to obtain abdominal wall integrity (Figure 4). To reconstruct the overlying skin defect, local flaps matching the defect were raised and placed. The residual defect was skin-grafted (Figure 5). After several days partial skin flap necrosis was found and the defect was covered using partial thickness skin grafts. Postoperatively, after two months the entire wound healed. We did not register any complications with bowel motility during the follow-up. The patient used a hernia belt support for six months, and according to the general surgical rule physical therapy during that period was contraindicated. Six months after the surgery, the integrity of the abdominal wall and overall cosmetic appearance were rated by the patient as very good (Figure 6).

DISCUSSION

Reconstruction of the abdominal wall following tumor resection is a very demanding procedure. The treatment of abdominal wall tumors

Correspondence to:

Asen V. VELIČKOV
Rentgenova 1/11 Street
18000 Niš
Serbia
asen-amm@medfak.ni.ac.rs

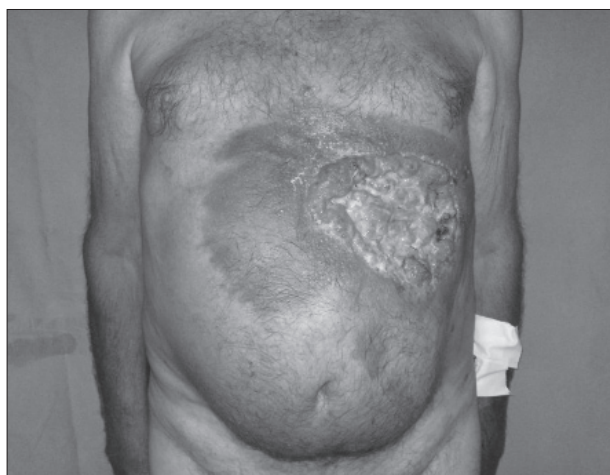


Figure 1. Skin cancer infiltrating abdominal wall

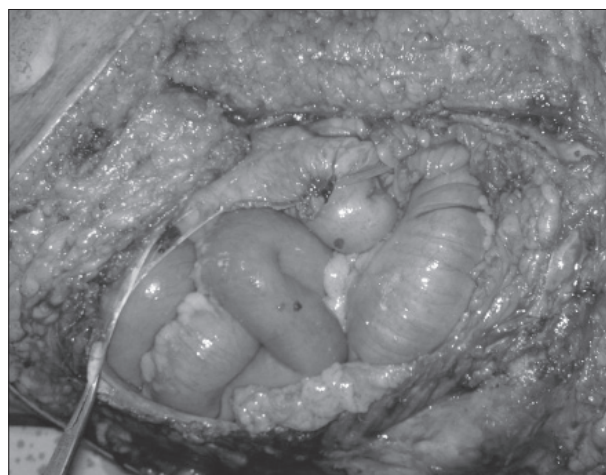


Figure 2. Operative defect after the abdominal wall resection

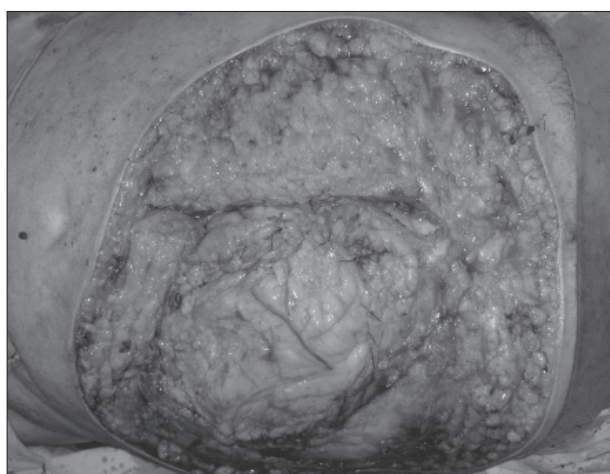


Figure 3. Omental flap placed in defect

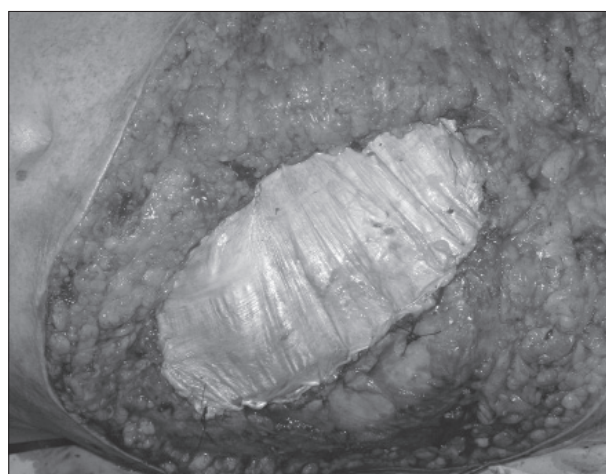

Figure 4. Fascia lata graft sutured in fascial defect

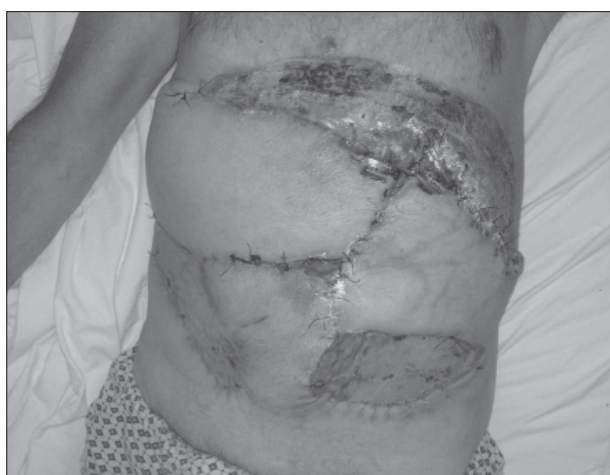

Figure 5. Appearance after skin reconstruction with skin flaps and grafts

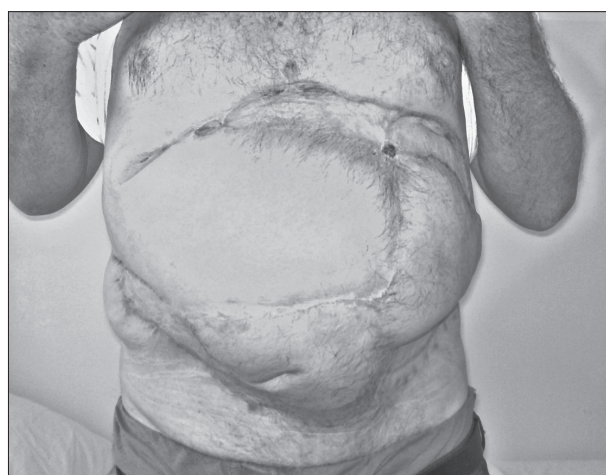

Figure 6. Definitive result on 6-month follow-up

still presents a challenging problem for general and also plastic surgeons. Giant abdominal wall defects can appear after extensive tumor resection. Our case presented with a locally advanced skin cancer which invaded the full thickness of the abdominal wall. The goals of abdominal wall reconstruction are to restore the structural support and optimize the esthetic appearance of the patient. Decisions regarding technique for abdominal wall reconstruction are

based on an assessment of the defect by location, extent, and etiology [2]. Available reconstruction options include direct repair, skin grafts, free fascial grafts, component separation, tissue expansion, regional flaps, free flaps and prosthetic mesh repair [2, 3]. Although there are a lot of techniques for reconstruction described in the literature, there are still extensive disagreements among surgeons regarding which one could be most suitable.

Direct repair of the defect is possible only when defects are smaller than 5 cm in diameter with adequate soft tissue coverage, sufficient fascia present to allow a tension-free closure [2]. Mesh repair followed by soft tissue coverage is also described. Compared to the direct repair of the abdominal wall, defect mesh coverage showed superior results, including lower rates of postoperative hernia [2, 4]. The mesh repair is performed using either synthetic mesh or biological grafts, covered by skin. Synthetic mesh repair predisposes the patient to several post implantation complications, such as wound infection, mesh infections, bowel adhesions, and other complications frequently requiring surgical revision and the rate of those complications could be lowered by using biologic grafts [4-9]. When stable skin coverage is present intraperitoneal mesh placement is recommended. Without cutaneous coverage abdominal wall reconstruction generally requires the use of flap [2].

Skin grafts directly applied to the omentum or small bowel surface provide no structural support, which results in hernia and should never be used in that way [3, 10]. Other techniques as components separation technique (CST) are also usable in cases with excess skin on the abdominal wall. The CST is the method of choice in the absence of both rectus muscles [11, 12]. Also, CST is followed by a relatively high rate of wound complications (12-67%) including hematoma, seroma, skin necrosis, and infection, compared to 12-27% in mesh repair [13, 14]. Previously described techniques, including mesh repair but excluding CST, are not indicated for the repair of this type of abdominal wall defects. For large full thickness abdominal wall defects only usage of CST or pedicled/free myocutaneous flaps provides well-vascularised tissue coverage.

There are proposals for the division of the abdomen into various zones with appropriate local myocutaneous flaps for the reconstruction of defects. Lateral and upper

abdominal defects may be reconstructed with a latissimus dorsi myocutaneous flap, and lower defects with a tensor fascia lata myocutaneous flap [2, 10]. Using those techniques various rates of complications were reported from 8.5% [2] to 44% [15]. Nevertheless, harvesting of potentially useful pedicled tensor fascia lata flap in our case was not useful due to the distance to the defect and the extent of the defect. Free flaps generally would be a good choice, but surgery lasts longer, and flap survival is uncertain.

We find that the method used in our case is the simplest and also the most cost effective procedure. It is known that a pedicled great omentum flap is not too difficult to use; in most cases it can reach defects over all quadrants of the abdominal wall. It consists of abundant blood vessels, fat, and lymphatic tissue, which makes it unique in terms of immunologic and angiogenic properties. It can be, therefore, used in infected or/and fields with poor circulation [16, 17]. The fascia lata graft is also a good solution for restoring the abdominal wall integrity. Firstly, it is an autograft material; in comparison to a synthetic mesh it shows a lower level of complications such as infection of the graft, its degradation or possible local or systemic rejection reaction [5-8]. The use of autologous materials, including the fascia lata graft, can be associated with increased pain, risk of hernia formation at the harvesting site and increased operative time [18]. Since the abdominal wall integrity was obtained using two autologous materials (fascia lata graft sutured to the superficial abdominal fascia) a large overlap of these structures was not required because of the type of suture healing. After the abdominal wall integrity was obtained, the skin defect was covered using local skin flaps, while the residual defects were covered using split skin grafts.

Our experience showed that autologous materials, such as pedicled omental flap, fascia lata graft and local skin flaps can be safely used in repair of large, full thickness and probably contaminated abdominal wall defects.

REFERENCES

- Dorai AA, Halim AS. Extended double pedicle free tensor fascia latae myocutaneous flap for abdominal wall reconstruction. *Singapore Med J*. 2007; 48(5):e141-5.
- Mathes SJ, Steinwald PM, Foster RD, Hoffman WY, Anthony JP. Complex abdominal wall reconstruction: a comparison of flap and mesh closure. *Ann Surg*. 2000; 232(4):586-96.
- Hultman CS, Pratt B, Cairns BA, McPhail L, Rutherford EJ, Rich PB, et al. Multidisciplinary approach to abdominal wall reconstruction after decompressive laparotomy for abdominal compartment syndrome. *Ann Plast Surg*. 2005; 54(3):269-75.
- Burger JW, Luijendijk RW, Hop WC, Halm JA, Verdaasdonk EG, Jeekel J. Long-term follow-up of a randomized controlled trial of suture versus mesh repair of incisional hernia. *Ann Surg*. 2004; 240(4):578-83.
- Shah BC, Tiwari MM, Goede MR, Eichler MJ, Hollins RR, McBride CL, et al. Not all biologics are equal! *Hernia*. 2011; 15(2):165-71.
- Harth KC, Broome AM, Jacobs MR, Blatnik JA, Zeinali F, Bajaksouzian S, et al. Bacterial clearance of biologic grafts used in hernia repair: an experimental study. *Surg Endosc*. 2011; 25(7):2224-9.
- Tang R, Gu Y, Gong DQ, Qian YL. Immediate repair of major abdominal wall defect after extensive tumor excision in patients with abdominal wall neoplasm: a retrospective review of 27 cases [corrected]. *Ann Surg Oncol*. 2009; 16(10):2895-907.
- Ghazi B, Deigni O, Yezhelyev M, Losken A. Current options in the management of complex abdominal wall defects. *Ann Plast Surg*. 2011; 66(5):488-92.
- Falagas ME, Kasiakou SK. Mesh-related infections after hernia repair surgery. *Clin Microbiol Infect*. 2005; 11(1):3-8.
- Sharma RK, Singh G, Naidu PM. Abdominal wall defects: anatomic classification and a scheme for management. *Ann Plast Surg*. 1998; 41(2):180-4.
- Ramirez OM, Ruas E, Dellon AL. "Components separation" method for closure of abdominal-wall defects: an anatomic and clinical study. *Plast Reconstr Surg*. 1990; 86:519-26.
- Kaemmer DA, Conze J, Otto J, Schumpelick V. New technical approach for the repair of an abdominal wall defect after a transverse rectus abdominis myocutaneous flap: a case report. *J Med Case Rep*. 2008; 2:108.
- de Vries Reilingh TS, van Goor H, Charbon JA, Rosman C, Hesselink EJ, van der Wilt GJ, et al. Repair of giant midline abdominal wall hernias: "components separation" technique versus prosthetic repair: interim analysis of a randomized controlled trial. *World J Surg*. 2007; 31:756-63.
- DiCocco JM, Magnotti LJ, Emmett KP, Zarzaur BL, Croce MA, Sharpe JP, et al. Long-term follow-up of abdominal wall reconstruction after planned ventral hernia: a 15-year experience. *J Am Coll Surg*. 2010; 210(5):686-95, 695-8.

15. Williams JK, Carlson GW, deChalain T, Howell R, Coleman JJ. Role of tensor fasciae latae in abdominal wall reconstruction. *Plast Reconstr Surg.* 1998; 101(3):713-8.
16. Bleichrodt RP, Malyar AW, de Vries Reilingh TS, Buyne O, Bonenkamp JJ, van Goor H. The omentum-polypropylene sandwich technique: an attractive method to repair large abdominal-wall defects in the presence of contamination or infection. *Hernia.* 2007; 11(1):71-4.
17. Liebermann-Meffert D. The greater omentum. Anatomy, embryology, and surgical applications. *Surg Clin North Am.* 2000; 80(1):275-93, xii.
18. Howden NS, Zyczynski HM, Moalli PA, Sagan ER, Meyn LA, Weber AM. Comparison of autologous rectus fascia and cadaveric fascia in pubovaginal sling continence outcomes. *Am J Obstet Gynecol.* 2006; 194:1444-9.

Реконструкција оштећења предњег трбушног зида пуне дебљине након ресекције тумора – приказ болесника

Предраг Ковачевић^{1,2}, Асен В. Величков¹, Данило Стојиљковић^{1,2}, Александра И. Величков¹, Зоран Ђеранић³

¹Медицински факултет, Универзитет у Нишу, Ниш, Србија;

²Клиника за пластичну и реконструктивну хирургију, Клинички центар, Ниш, Србија;

³Општа болница, Лесковац, Србија

КРАТАК САДРЖАЈ

Увод Реконструкција оштећења трбушног зида пуне дебљине је захтевна процедура, како за опште, тако и за пластичне хирурге, и захтева енергично планирање и реконструкцију три слоја.

Приказ болесника Код болесника старог 70 година дијагностикован је велики тумор трбушног зида с еволуцијом дугом 40 година. Болесник је оперисан у општој анестезији. Након ресекције тумора заостало је оштећење трбушног зида пуне дебљине. Реконструкција је урађена у истом акту. Оштећење је реконструисано применом комбинације техника, укључујући и режањ великог оментума, графт фа-

сције лате, локалне кожне режњеве и трансплантате коже. Након операције није било компликација, осим парцијалне некрозе режњева, која је лечена слободним кожним трансплантатима. Болесник је описао коначни резултат као врло добар. Није уочено стварање хернија.

Закључак Техника оментопластике, реконструкција трбушног зида оментопластиком у комбинацији са слободним графтом фасције лате и кожним графтом може бити добро решење за велика оштећења трбушног зида са губитком пуне дебљине ткива.

Кључне речи: реконструкција трбушног зида; ресекција трбушног зида; карцином коже

Примљен • Received: 04/03/2013

Прихваћен • Accepted: 22/05/2013