

# Falx Chondroma with Hyperostosis of the Skull: A Case Report

Nenad Živković<sup>1</sup>, Iva Berisavac<sup>1</sup>, Marko Marković<sup>1</sup>, Sanja Milenković<sup>2</sup>

<sup>1</sup>Department of Neurosurgery, Clinical Hospital Center Zemun, Belgrade, Serbia;

<sup>2</sup>Department of Clinical Pathology, Clinical Hospital Center Zemun, Belgrade, Serbia

## SUMMARY

**Introduction** Intracranial chondroma is a very rare, slow growing, benign cartilaginous tumor that arises usually from the base of the skull. Chondroma located at the falx is extremely rare. According to our best knowledge 15 cases of falx chondromas have been reported in the literature.

**Case Outline** This is the first case report of falx chondroma located in the parietal area associated with hyperostosis. Magnetic resonance imaging of the brain revealed a 3×4×4 cm solid, calcified, ring-shaped, well-defined tumor at the posterior falx. The patient underwent surgery and complete resection was performed. Histological examination confirmed chondroma of the falx. Postoperative CT scan showed no residual of tumor and the patient was discharged.

**Conclusion** The long-term prognosis is good after a total excision of the tumor. Awareness of this rare pathology in the differential diagnosis of falx mass could facilitate the diagnosis.

**Keywords:** intracranial tumor; chondroma; falx cerebri

## INTRODUCTION

Chondroma is one of the most common benign cartilaginous bone tumors arising from the long bones, pelvis or scapulae [1]. Intracranial chondromas, on the contrary, are very rare tumors with an incidence of 0.2% to 0.3% of all intracranial tumors. The first case of intracranial chondroma was reported in 1851 by Hirschfield [2] and the first surgical resection was reported by Nixon [3] in 1982. Since then 127 cases of intracranial chondromas were reported, mostly involving the base of the skull originating from residual rests of primordial cartilage in basilar synchondroses, with a predilection for the sphenoid-ethmoidal region [4]. In very rare instances, chondromas arise from the falx [5-19]. According to our best knowledge only 15 cases were reported in the literature.

In this article we report the case of a patient with chondroma involving one side of the falx extending to the right parietal area.

## CASE REPORT

A 38-year-old male was admitted to our hospital with a history of intermittent headaches lasting one year. He reported few head traumas while working as a miner. Three months ago he was referred to our institution due to headaches resistant to analgesics. A month before admission, he was experiencing hypoesthesia of the right side of the head that lasted for two weeks and disappeared spontaneously. General and neurological examinations were completely normal and his past medical history was unremarkable.

A computer tomography (CT) scan revealed a 3×4×4 cm, solid, well-circumscribed, hyperdense mass involving the left side of the falx in the parietal area.

Magnetic resonance imaging (MRI) of the brain showed a solid, calcified, ring-shaped, well-defined tumor at the posterior falx. The tumor involved one side of the falx and extended to the parietal area with no perifocal edema (Figure 1).

Cerebral intra-arterial digital subtraction angiography (DSA) was performed and revealed an avascular mass with a patent sagittal sinus.

The patient underwent surgery and left parietal craniotomy was performed under general anesthesia. Surgery revealed a 3×4×4 cm solid mass, calcified, with white lobulated surface, involving one side of the posterior falx and the lateral wall of venous superior sagittal sinus, and extending into the parietal area with no adhesion between the tumor and the brain tissue. CT and MRI showed no perifocal edema. The tumor was completely removed with its attachment to the falx.

Patho-histological examination revealed chondroma, with cartilaginous lobules in the hyaline matrix and calcifications. Neither nuclear atypia nor mitoses were found (Figure 2).

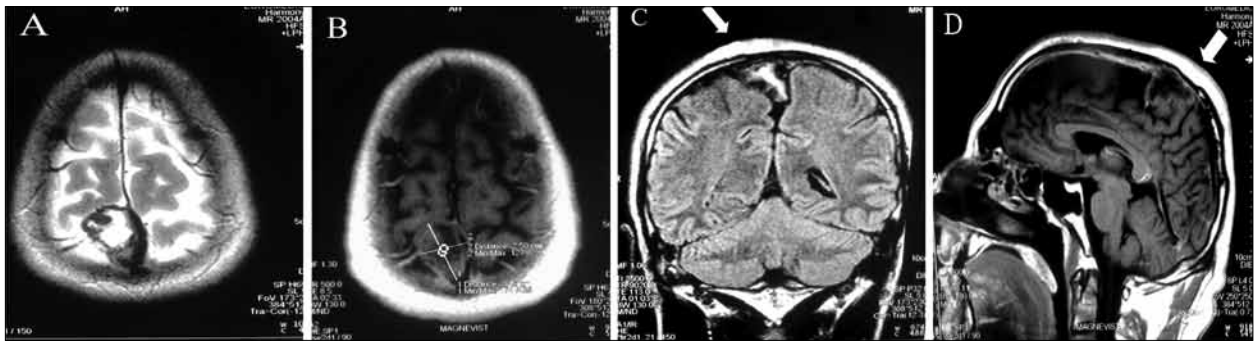
Postoperative CT scans showed no residual tumor and the patient was discharged on the 9<sup>th</sup> operative day (Figure 3).

## DISCUSSION

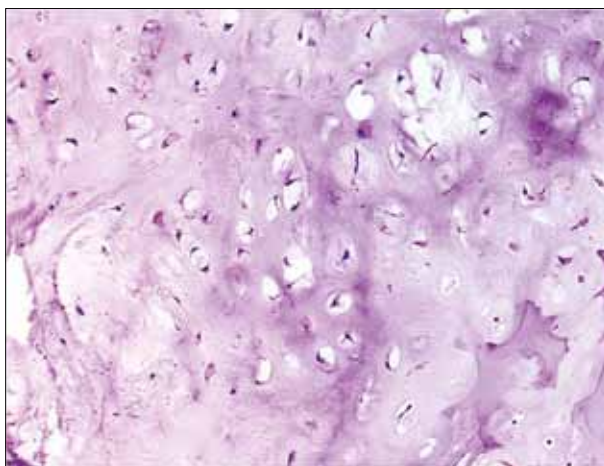
Intracranial chondromas are rare lesions with an incidence of 0.2-0.3% of all intracranial tumors and can occur as solitary lesions or as a

### Correspondence to:

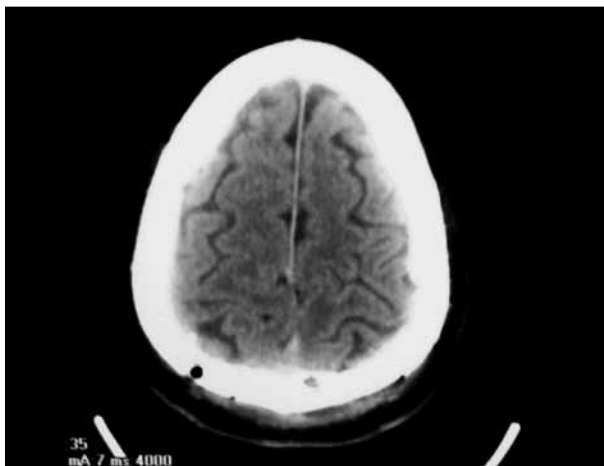Nenad ŽIVKOVIĆ  
Department of Neurosurgery  
Clinical Hospital Center "Zemun"  
Vukova 9, 11080 Zemun  
Serbia  
drnzivkovic@yahoo.com



**Figure 1.** Magnetic resonance imaging (MRI) of falx chondroma. (A) Axial section of T2 and (B) T1-weighted MRI showing a well-defined tumor at the posterior parietal area crossing the falx cerebri. The center is hyperintense on T2. (C) On coronal MRI a hyperdense mass, inhomogeneously calcified, involving one side of falx cerebri. (D) Sagittal MRI revealing a 3x4x4 cm sized tumor involving one side of falx and extending to the parietal area with no perifocal edema, with hyperostosis of parietal bone.



**Figure 2.** Histopathology of falx chondroma. Microscopic appearance of cartilaginous tumor. Cellular atypism is not identified (Hematoxyline-eosine, original magnification  $\times 300$ ).



**Figure 3.** Postoperative CT of the brain. No residual tumor was found.

part of polysystemic enchondromatosis (Ollier's disease) or multiple enchondromatosis associated with soft tissue angiomas (Maffucci syndrome) [20]. The first case of intracranial chondroma was reported in 1851 by Hirschfeld [2] and the first surgical resection was reported in 1982 by Nixon [3]. Since then 127 cases of intracranial chondromas were reported occurring at the base of the skull and originating from spheno-petrosal, spheno-occipital and

petro-occipital synchondroses. Extremely rare, chondromas arise from the falx. According to our best knowledge, only 15 cases were reported in the literature [5-19]. The results of published falx cerebri chondroma cases are summarized in Table 1.

In the literature, the reported age of patients ranged between 14 and 50 years with a peak in the third decade and no preference for either sex [12].

The etiology of falx chondromas is not clearly established. There are several theories of the origin of the intracranial falx chondromas. They are considered to develop due to heterotrophic chondrocytes, metaplasia of perivascular mesenchymal cells or meningeal fibroblasts or migration caused by trauma or inflammatory process. Trauma is an etiological factor that is connected with tumor-like meningiomas [21]. Only a few cases described a possible connection between intracranial chondroma and trauma [22]. Hong et al. [22] supported that theory with a case of convexity chondroma at the site of a previously depressed skull fracture. However, our patient had a history of previous head traumas when working as a miner; he is the case with trauma as a possible etiological factor for falx chondroma with hyperostosis of the parietal bone. We can speculate that this is the cause of later head trauma or by migration of mesenchymal dural cells. However, we cannot prove this theory.

The clinical presentation of falx chondromas mostly depends of anatomic location and it is non-specific. They can be clinically silent and the symptoms may not appear for many years since the tumors are slow-growing. Patients may have, depending on the location, focal neurological signs and personality changes, but most of the reported cases had symptoms of high intracranial pressure and seizures. In our case, the patient had focal signs due to the local compression of brain tissue with intermittent headaches and the feeling of hypoesthesia on the right side of the head.

For the detection of falx chondromas CT and MRI are very important and usually show well-circumscribed and demarcated, isodense, extra-cerebral avascular lesion with different extent of calcification, with no hyperostosis and no perifocal edema. Chondromas of convexity may show evidence of hyperostosis of the internal table of the skull. According to the reported data, no falx chondroma was

**Table 1.** Summary of the published intracranial chondroma cases originated from falx cerebri

Author, year, reference number	Age/sex	Location	Calcification	Type by Lacerte	Size	Outcome (1-5 years)
Ozgen et al. (1984) [5]	39/M	Left frontal	Present	I	N/A	No recurrence
Yang et al. (1986) [6]	27/F	Right fronto-parietal	Present	II	N/A	No recurrence
Hadadian et al. (1991) [7]	25/F	Bilateral frontal	Present	II	10×7×4 cm	No recurrence
Saleman et al. (1992) [8]	28/F	Left parafalcine	Absent	I	7×5×4 cm	No recurrence
DeCoene et al. (1997) [9]	35/M	Right parietal	Present	I	N/A	No recurrence
Abdelhamid et al. (1996) [10]	37/F	Right posterior frontal	Present	II	5×5×6 cm	No recurrence
Lacerte et al. (1996) [11]	22/M	Right fronto-parietal	Present	I	5.5×4.4×3.8 cm	No recurrence
Kurt et al. (1996) [12]	27/M	Bifrontal	Present	II	9×9×9 cm	No recurrence
Pallini et al. (1997) [13]	22/M	Left parasagittal	Present	II	6×4.5×5 cm	No recurrence
Ustun et al. (1997) [14]	28/F	Right temporo-parietal	Absent	II	8×6×3.5 cm	No recurrence
Luzardo-Small et al. (1999) [15]	14/M	Left fronto-parietal	Absent	II	9×6×5 cm	No recurrence
Bergman et al. (2004) [16]	19/F	Bifrontal	Present	N/A	6×4×4 cm	No recurrence
Cosar et al. (2005) [17]	44/M	Bifrontal	Absent	I	5×5×6 cm	No recurrence
Erdogan et al. (2006) [18]	50/F	Bifrontal	Present	II	8.5×7.5×4 cm	No recurrence
Fountas et al. (2008) [19]	30/M	Left parietal	Absent	II	2×3×4 cm	No recurrence

M – male; F – female; N/A – not available

found with hyperostosis of the skull [23, 24]. This is the first reported falx chondroma with hyperostosis of the parietal posterior bone. Lacerte et al. [25] proposed the classification of chondromal tumors in two types. First, most common type which on CT scan appears as an isodense and homogenous mass. Type two appears with a central hypodense area and constitutes a degenerative cyst. Falcine chondromas, in most cases, appear as isointense lesions on T1-weighted images (T1W1) and on magnetic resonance images T2W1; they have mixed hypo- and hyper-intense images. Falcine chondromas usually do not have calcifications [23]. Differential diagnosis of falcine lesions mostly indicates falx meningiomas but is not limited to oligodendroglioma, chondrosarcoma, glioblastoma multiforme. It should be differentiated from falx meningioma by using contrast-enhanced imaging and angiography because chondromas, according to a number of published cases, usually have no enhancement in contrast to meningiomas and have no vascular supply. Angiography procedures always revealed the avascular nature of chondromal tumors [2, 18, 26]. Cerebral intra-arterial digital subtraction angiography (DSA) was performed in our case and revealed an avascular mass, which pointed to a tumor other than meningioma.

Treatment for these tumors is total tumor resection with removal of attached falx [2, 12]. For the description of surgical resection, the Simpson resection grading scale can be used, as in falx meningiomas [27]. Otherwise, after extirpation these tumors show no recurrence and the long-term outcome is excellent [5, 12]. Any recurrences should raise suspicion for chondrosarcoma [16, 18]. Falcine chondromas can be attached to the dura matrix and venous sinuses, as in our case, and their extirpation should be prepared with extra caution and eventual management of sinus venous hemorrhage.

Radiation therapy is not advised since chondromal tumors are radio-resistant and can undergo a malignant transformation [18, 28, 29].

Falcine chondromas are extremely rare, slow-growing, intracranial lesions. To the best of our knowledge, only 15 cases of intracranial chondromas derived from the falx have been reported. Extra-cerebral falx lesions with no perifocal edema, the lack of enhancement and hyperostosis of the skull, should also make us suspect falx chondromas. Complete extirpation is a long-term treatment for falx chondromas and any recurrence should raise suspicion for malignant degeneration into chondrosarcomas.

## REFERENCES

- Morisaki Y, Takagi K, Ishii Y, Furuya T, Ishikawa M, Tanaka S. Periosteal chondroma developing in a rib at the side of a chest wall wound from a previous thoracotomy: report of a case. *Surg Today*. 1996; 26:57-9.
- Nakayama M, Nagayama T, Hirano H, Oyoshi T, Kuratsu J. Giant chondroma arising from the dura mater of the convexity. *J Neurosurg*. 2001; 94:331-4.
- Dany A, Vidal J, Dumas M, Ravon R, Bokor J. Cerebellopontine angle chondroma. A report of one personal case. *Neurochirurgie*. 1980; 26:355-7. [in French]
- Mapstone TB, Wongmorengkolrit T, Roessman U, Ratcheson RA. Intradural chondroma: A case report and review of the literature. *Neurosurgery*. 1983; 12:111-4.
- Ozgen T, Pamir MN, Akalan N, Bertan V, Onol B. Intracranial solitary chondroma. Case report. *J Neurosurg*. 1984; 61:399-401.
- Yang PJ, Seeger JF, Carmody RF, Fleischer AS. Chondroma of falx: CT findings. *J Comput Assist Tomogr*. 1986; 10:1075-6.
- Hadadian K, Abtahii H, Asil ZT, Rakhshan M, Vessal P. Cystic falcine chondroma: Case report and review of the literature. *Neurosurgery*. 1991; 29:909-12.
- Saleman M, Scholtz H, Kriszt D, Numaguchi Y. Extraskelatal myxoid chondrosarcoma of the falx. *Neurosurgery*. 1992; 31:344-8.
- De Coene B, Gilliard C, Grandin C, Nisolle JF, Trigaux JP, Lahdou JB. Unusual location of an intracranial chondroma. *Am J Neuroradiol*. 1997; 18:573-5.

10. Abdelhamid K, Camras LR, Nijenshom EM, Rosseau GL, Cerullo LJ. Intracranial chondroma arising from the cranial vault: CT and MR appearance. *J Comput Assist Tomogr.* 1996; 20:556-8.
11. Lacerte D, Gagne F, Copty M. Intracranial chondroma. Report of two cases and review of the literature. *Can J Neurol Sci.* 1996; 23:132-7.
12. Kurt E, Beute GN, Sluzewski M, van Rooij WJ, Teeppen JL. Giant chondroma of the falx. Case report and review of the literature. *J Neurosurg.* 1996; 85:1161-4.
13. Pallini R, Lauretti L, Fernandez E, Colosimo C. Giant chondroma of the falx. *J Neurosurg.* 1997; 87:333-4.
14. Ustun MO, Paksoy N, Kilicarslan B. Cystic chondroma arising from the falx cerebri: a case study with review of literature. *Clin Neuropathol.* 1997; 16:27-9.
15. Luzardo-Small G, Mendez-Martinez O, Cardozo-Duran J. Cavitated (cystic) falcine chondroma: case report. *Br J Neurosurg.* 1999; 13:426-8.
16. Bergmann M, Pinz W, Blasius S, Lentschig M, Ostertag H, Neubauer U. Chondroid tumors arising from the meninges – report of 2 cases and review of the literature. *Clin Neuropathol.* 2004; 23:149-53.
17. Cosar M, Iplikcioglu AC, Bek S, Gokduman CA. Intracranial falcine and convexity chondromas: two case reports. *Br J Neurosurg.* 2005; 19:241-3.
18. Erdogan S, Zorludemir S, Erman T, Akgul E, Ergin M, Ildan F, et al. Chondromas of the falx cerebri and dural convexity: report of two cases and review of the literature. *J Neurooncol.* 2006; 80:21-5.
19. Fountas KN, Stamatou S, Barbanis S, Kourtopoulos H. Intracranial falx chondroma: Literature review and case report. *Clin Neurol Neurosurg.* 2008; 110(1):8-13.
20. Traflet FR, Babaria AR, Barolat G, Doan HT, Gonzalez C, Mishkin MM. Intracranial chondroma in a patient with Ollier's disease. *J Neurosurg.* 1989; 70:274-6.
21. Kotzen RM, Swanson RM, Milhorat TH, Boockvar J. Post-traumatic meningioma: case report and historical perspective. *J Neurol Neurosurg Psychiatry.* 1999; 66:796-8.
22. Hong JT, LeeSW, Son BC, Sung JH, Choi HC, Kim MC. Delayed occurrence of intracranial supratentorial chondroma following compound depressed skull fracture. *Acta Neurochir* 2005; 147:343-5.
23. Sebbag M, Schmidt V, Leboucq N, Bitoun J, Castan PH, Frerebeau PH. Chondrome dure-mérien; a propos d'un cas et revue de la literature. *J Radiol.* 1990; 71:495-8.
24. Mapstone TB, Wongmongkolrit T, Roessman U, Ratcheson RA. Intradural chondroma: a case report and review of the literature. *Neurosurgery.* 1983; 12:111-4.
25. Lacerte D, Gagne F, Copty M. Intracranial chondroma. Report of two cases and review of the literature. *Can J Neurol Sci.* 1996; 23:132-7.
26. Khosrovi H, Sadrolhefazi A, El-Kadi H, Bloomfield SM, Schochet SS. Intradural convexity chondroma: a case report and review of diagnostic features. *WV Med J.* 2000; 96:612-6.
27. Simpson D. The recurrence of intracranial meningiomas after surgical treatment. *J Neurol Neurosurg Psychiatry.* 1957; 20:22-39.
28. Colpan E, Attar A, Erekul S, Arasil E. Convexity dural chondroma: a case report and review of the literature. *J Clin Neurosci.* 2003; 10:106-8.
29. Valdueza JM, Freckmann N, Herrmann HD. Chondromatosis of the choroid plexus: case report. *Neurosurgery.* 1990; 27:291-4.

## Хондром фалкса с хиперостозом кости лобање: приказ болесника

Ненад Живковић<sup>1</sup>, Ива Берисавац<sup>1</sup>, Марко Марковић<sup>1</sup>, Сања Миленковић<sup>2</sup>

<sup>1</sup>Неурохирушка служба, Клиничко-болнички центар „Земун“, Београд, Србија;

<sup>2</sup>Служба клиничке патологије, Клиничко-болнички центар „Земун“, Београд, Србија

### КРАТАК САДРЖАЈ

**Увод** Интракранијални хондром је веома редак, спорорастући, бенигни картилагинозни тумор који обично настаје са базе лобање. Хондром локализован на фалксу је изузетно редак. Према нашим сазнањима, 15 случајева фалксног хондрома је приказано у литератури.

**Приказ болесника** Ово је први случај хондрома фалкса у паријеталној области повезаног с хиперостозом. Магнетна резонанција мозга је открила солидан, чврст, добро дефинисан тумор у облику прстена (величине 3x4x4 cm) на

задњем фалксу. Болесник је оперисан и урађена је потпуна ресекција. Хистолошко испитивање потврдило је хондром фалкса. Постоперациони налаз компјутеризоване томографије није показао никакав резидуум тумора и болесник је пуштен кући.

**Закључак** Дугорочна прогноза је добра после тоталне ексцизије тумора. Свест о овој реткој патологији у диференцијалној дијагнози фалксне масе олакшаће дијагностику.

**Кључне речи:** интракранијални тумор; хондром; фалкс мозга

Примљен • Received: 16/07/2012

Ревизија • Revision: 09/05/2014

Прихваћен • Accepted: 26/05/2014